



PATIENT

Lia Cafasso

SPECIES

Canine

BREED

Pitbull

SEX

Spayed Female

AGE

11 Years

WEIGHT

60.9 Lbs.

INTERPRETED BY

Andrea Nicastro, DMV,
Diplomate DACVIM
(Small Animal
Internal Medicine)

IMAGING PERFORMED BY

Michelle Roche

HOSPITAL NAME

Fredon AH

REFERRING VET

Dr. Michelle Roche

INVOICE

13655

DATE

1/28/22

PRESENTING CLINICAL SIGNS

History: Increase urination per owner
Abnormal PE/Chem/CBC/UA Results: Slight pot belly, ulcerated growth ventral chest WBC: 3.8 Neut: 2888 Lymph: 604 Mono: 118 Alt: 725

ULTRASONOGRAPHIC EXAMINATION OF THE ABDOMEN

Urinary System

The urinary bladder, trigone, and pelvic urethra are normal in thickness and the mucosal surface is smooth. The bladder lumen is moderately distended with anechoic urine. No masses, inflammatory changes or calculi are observed. Ureteral papillae and visualized portion of the proximal urethra, visible to a depth of 2 cm, are normal.

The left kidney presented normal size (5.65 cm in length); normal shape and architecture with smooth peripheral margins. There is a normal 1:3 cortex to medulla ratio with minimal loss of corticomedullary distinction. There is no evidence of pyelectasia, nephroliths, infarcts or hydronephrosis. Renal vasculature is normal.

The right kidney presented normal size (6.56 cm in length); normal shape and architecture with smooth peripheral margins. There is a normal 1:3 cortex to medulla ratio with minimal loss of corticomedullary distinction. There is no evidence of pyelectasia, nephroliths, infarcts or hydronephrosis. Renal vasculature is normal.

Adrenal Glands

The left adrenal gland is normal size (0.85 cm at cranial pole) (0.68 cm at caudal pole) (3.69 cm in length); normal shape; homogenous parenchyma. The glandular echogenicity and detail are unremarkable. Capsule, cortex, and medullary definition are normal. The phrenicoabdominal vein and surrounding vasculature are normal.

The right adrenal gland is mildly enlarged (1.53 cm at cranial pole) (0.96 cm at caudal pole) (3.19 cm in length); normal shape; homogenous parenchyma. The glandular echogenicity and detail are unremarkable. Capsule, cortex, and medullary definition are normal. The phrenicoabdominal vein and surrounding vasculature are normal.

Spleen

The spleen is normal in size (1.89 cm in width at the level of the hilus) with a normal capsular contour. There is appropriate echogenicity and echotexture. No focal lesions are observed. Splenic vasculature is normal.

Liver

The liver is subjectively normal in size with normal contours and structure. There is appropriate echogenicity and echotexture. No overt structural evidence of inflammatory, infiltrative or regenerative pathology is evident. Vascular and biliary tracts are of normal volume with no evidence of congestion. No pathological hepatic lymphadenopathy observed.

The gall bladder is of normal contours and contains some gravity dependent echogenic debris. The wall is normal in thickness. No choleliths are observed. The cystic and common bile ducts are normal/not seen.



PATIENT

Lia Cafasso

SPECIES

Canine

BREED

Pitbull

SEX

Spayed Female

AGE

11 Years

WEIGHT

60.9 Lbs.

INTERPRETED BY

Andrea Nicastro, DMV,
Diplomate DACVIM
(Small Animal
Internal Medicine)

**IMAGING
PERFORMED BY**

Michelle Roche

HOSPITAL NAME

Fredon AH

REFERRING VET

Dr. Michelle Roche

INVOICE

13655

DATE

1/28/22

Gastrointestinal

The stomach and intestine are free of stasis and exhibit normal peristaltic activity. The gastric lumen is not distended. The gastric wall and pylorus are normal in thickness with a normal layering pattern. The small intestinal lumen is not dilated. The small intestinal wall thickness is normal with a normal layering pattern and appropriate mural detail. Discreet masses are not identified. The colonic wall is normal. No obstructive or overt infiltrative disease is noted.

Pancreas

The region of the pancreas is isoechoic relative to surrounding omental fat. No obvious parenchymal abnormalities are observed. There is no evidence of regional inflammation or effusion.

Free Abdomen

The peritoneal cavity is normal. There is no evidence of inflammation or effusion. The abdominal lymph nodes are normal/not visible.

ULTRASONOGRAPHIC FINDINGS

Primary Findings

- An obvious cause for the elevated liver enzymes is not identified in the study. However, a microscopic hepatopathy (i.e., bacterial cholangiohepatitis, Leptospirosis, chronic active hepatitis, copper-associated hepatotoxicity, infiltrative neoplasia (less likely)) should be considered.

Secondary Findings

- The gastric luminal contents likely represent ingesta +/- foreign material and/or pills. Correlation with clinical findings is recommended.
- The mild right adrenomegaly is likely secondary to hyperplastic change with lower potential for emerging neoplasia.

INTERPRETATION OF THE FINDINGS & FURTHER RECOMMENDATIONS

- Leptospirosis testing (i.e., blood and urine PCR, serology) is recommended, particularly if the ALT elevation is acute in nature.
- Also consider pre-and post-prandial serum bile acids to assess hepatic function.
- Cytologic evaluation of the liver should be considered in this patient if clotting status is appropriate. A fine needle aspirate using a 25-gauge needle is recommended. If cytologic evaluation is inconclusive, consider a surgical liver biopsy with aerobic and anaerobic bile cultures and acquisition of additional hepatic tissue samples for copper quantitation. If a more conservative approach is desired, consider empirical treatment for bacterial cholangiohepatitis (amoxicillin-clavulanic acid, hepatic antioxidants). If no improvement in the liver values is seen within 7-10 days of initiating therapy, antibiotics should be discontinued, and hepatic tissue sampling reconsidered. If liver values improve, continue therapy for at least 4-6 weeks and 1 week beyond normalization of the liver values.
- Given the patients age, three-view thoracic radiographs are recommended to assess cardiopulmonary status.



PATIENT

Lia Cafasso

SPECIES

Canine

BREED

Pitbull

SEX

Spayed Female

AGE

11 Years

WEIGHT

60.9 Lbs.

INTERPRETED BY

Andrea Nicastro, DMV,
Diplomate DACVIM
(Small Animal
Internal Medicine)

IMAGING PERFORMED BY

Michelle Roche

HOSPITAL NAME

Fredon AH

REFERRING VET

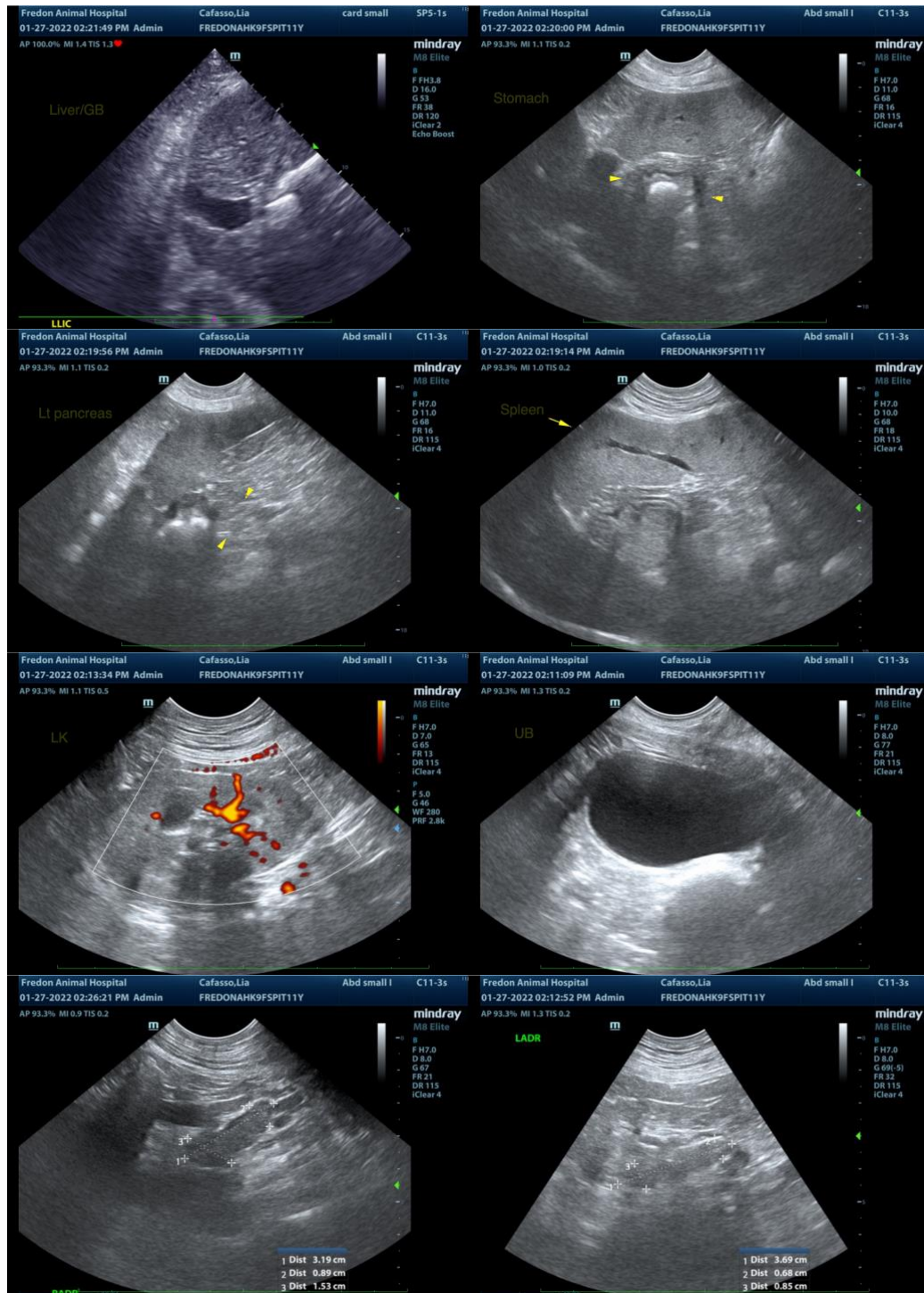
Dr. Michelle Roche

INVOICE

13655

DATE

1/28/22





PATIENT

Lia Cafasso

SPECIES

Canine

BREED

Pitbull

SEX

Spayed Female

AGE

11 Years

WEIGHT

60.9 Lbs.

INTERPRETED BY

Andrea Nicastro, DMV,
Diplomate DACVIM
(Small Animal
Internal Medicine)

**IMAGING
PERFORMED BY**

Michelle Roche

HOSPITAL NAME

Fredon AH

REFERRING VET

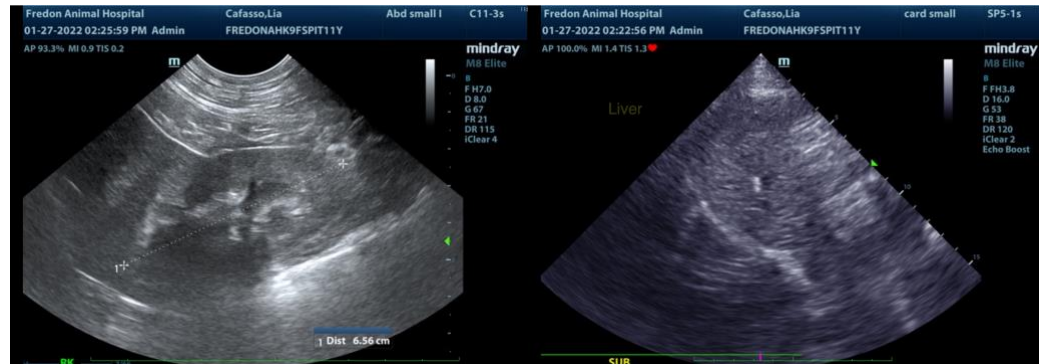Dr. Michelle Roche

INVOICE

13655

DATE

1/28/22



The information and recommendations provided are based on the images presented by the referring veterinarian. No evaluation can be communicated regarding pathology that was not visible in the image/video clips provided.

Thank you for this referral. If the clinical or image interpretation does not parallel your findings or if I can be of any further assistance please contact me.

Andrea Nicastro, DVM, Diplomate DACVIM (Small Animal Internal Medicine)
info@SonoPath.com