**PATIENT PRESENTING CLINICAL SIGNS**

Thor Schultz History: Recent onset of vomiting and appetite. No intake of water as well. As of last night, Thor is non ambulatory. No Radiographs or current BW.

SPECIES Abnormal PE/Chem/CBC/UA Results:

Canine

ULTRASONOGRAPHIC EXAMINATION OF THE ABDOMEN**BREED** *Urinary System*

Goldendoodle

The urinary bladder wall is normal in thickness and the mucosal surface is smooth. The bladder is moderately distended. A small amount of suspended echogenic debris is observed within the lumen. No masses, inflammatory changes or calculi are observed. The region of the trigone and visible portion of the proximal urethra are normal.

SEX

Neutered Male

The prostate is normal in size (1.34 cm in width) and shape. Parenchyma is homogenous. The prostatic urethra appears normal without evidence of dilation or obstruction.

AGE

12 years

The left kidney is normal in size (7.66 cm in length) with a normal shape, architecture and smooth peripheral margins. There is a normal 1:3 cortex to medulla ratio with mild to moderate loss of corticomedullary distinction. There is no evidence of pyelectasia, nephroliths, infarcts or hydroureter.

WEIGHT

86 lbs

The right kidney is normal in size (7.37 cm in length) with a normal shape, architecture and smooth peripheral margins. There is a normal 1:3 cortex to medulla ratio with mild to moderate loss of corticomedullary distinction. There is no evidence of pyelectasia, nephroliths, infarcts or hydroureter.

Adrenal Glands

The left adrenal gland is small in size (0.52 cm at cranial pole) (0.54 cm at caudal pole) with a slightly flattened contour. The glandular echogenicity and detail are unremarkable. Capsule, cortex, and medullary definition are normal. The phrenicoabdominal vein and surrounding vasculature are normal.

INTERPRETED BY

Andrea Nicastro,
DVM, Diplomate
ACVIM (Small Animal
Internal Medicine)

The right adrenal gland is small in size (0.52 cm at cranial pole) (0.51 cm at caudal pole) with a slightly flattened contour. The glandular echogenicity and detail are unremarkable. Capsule, cortex, and medullary definition are normal. The phrenicoabdominal vein and surrounding vasculature are normal.

IMAGING PERFORMED BY

Kim Liedberg

Spleen

The spleen is normal in size (1.77 cm in width at the level of the hilus) with a normal capsular contour. The parenchyma is diffusely mottled in appearance. No focal lesions are observed. Splenic vasculature is normal.

HOSPITAL NAME

SVS Imaging WI

Liver

The liver is subjectively normal in size with normal curvilinear peripheral contours. The parenchyma is hypoechoic relative to the spleen and slightly mottled in appearance. No distinct focal lesions are observed. Hepatic vasculature and intrahepatic biliary tracts are of normal volume with no evidence of congestion.

REFERRING VET

Dr Senn
Fox Lake AH

The gall bladder lumen is moderately distended. The wall is thin and smooth. A small amount of echogenic debris is observed within the lumen. The cystic and common bile ducts are normal/not seen.

INVOICE

12101

Gastrointestinal

The stomach and intestine are free of stasis and exhibit normal peristaltic activity. The gastric lumen is moderate gas-distended. The gastric wall and pylorus are normal in thickness with a normal layering pattern. The pyloric outflow tract is patent. The small intestinal lumen is segmentally dilated with

DATE

1.26.23

**PATIENT**

Thor Schultz

chyme (mild). The small intestinal wall thickness is normal with a normal layering pattern and appropriate mural detail. Discreet masses are not identified. The colonic wall is normal. There is no evidence of an obstructive pattern.

SPECIES

Canine

Pancreas

The base and right limb of the pancreas are visible and slightly irregular peripheral margins. The parenchyma is largely hyperechoic relative to surrounding omental fat and slightly mottled in appearance. The pancreatic duct is visible but not overtly dilated. There is no evidence of peripancreatic inflammation or effusion.

BREED

Goldendoodle

Free Abdomen

The peritoneal cavity is normal. There is no evidence of inflammation or effusion. The abdominal lymph nodes are normal/not visible.

SEX

Neutered Male

ULTRASONOGRAPHIC FINDINGS**Primary Findings**

- The splenic parenchymal changes are most consistent with a benign process such as lymphoid hyperplasia, extramedullary hematopoiesis, splenitis or antigenic stimulation with a lower possibility of infiltrative neoplasia (i.e., lymphoma, mast cell neoplasia).

AGE

12 years

Secondary Findings

- The hepatic parenchymal changes are nonspecific and could be consistent with benign age-related remodeling and/or regenerative nodular hyperplasia. However, a microscopic hepatopathy cannot be completely excluded.
- The pancreatic changes are most consistent with age-related parenchymal remodeling, potentially secondary to a prior inflammatory episode, early fibrosis or chronic pancreatitis.
- Bilateral chronic age-related renal changes
- The flattened adrenal glands may be a normal variant or could be consistent with early atrophy (i.e., secondary to hypoadrenocorticism)

WEIGHT

86 lbs

INTERPRETED BY

Andrea Nicastro,
DVM, Diplomate
ACVIM (Small Animal
Internal Medicine)

IMAGING PERFORMED BY

Kim Liedberg

*An obvious cause for the patient's clinical signs is not identified in this study. Considerations include underlying metabolic issue, microscopic gastrointestinal disease (i.e., food allergy/intolerance, inflammatory bowel disease, infectious/parasitic disease), mild pancreatitis, other.

HOSPITAL NAME

SVS Imaging WI

INTERPRETATION OF THE FINDINGS & FURTHER RECOMMENDATIONS**REFERRING VET**

Dr Senn
Fox Lake AH

- Baseline lab work, including a CBC, chemistry panel, urinalysis and T4 is recommended.
- Also consider a resting cortisol level to screen for hypoadrenocorticism.
- Thoracic radiographs should also be considered to assess cardiopulmonary status and to evaluate for occult esophageal disease.

INVOICE

12101

DATE

1.26.23



PATIENT

Thor Schultz

- Consider a fine-needle aspirate of the spleen (if clotting status is appropriate) to assess for infiltrative neoplasia.

SPECIES

Canine

- Depending on the results of the above diagnostics, a more comprehensive work-up may be warranted.

BREED

Goldendoodle

SEX

Neutered Male

AGE

12 years

WEIGHT

86 lbs

INTERPRETED BY

Andrea Nicastro,
DVM, Diplomate
ACVIM (Small Animal
Internal Medicine)

**IMAGING
PERFORMED BY**

Kim Liedberg

HOSPITAL NAME

SVS Imaging WI

REFERRING VET

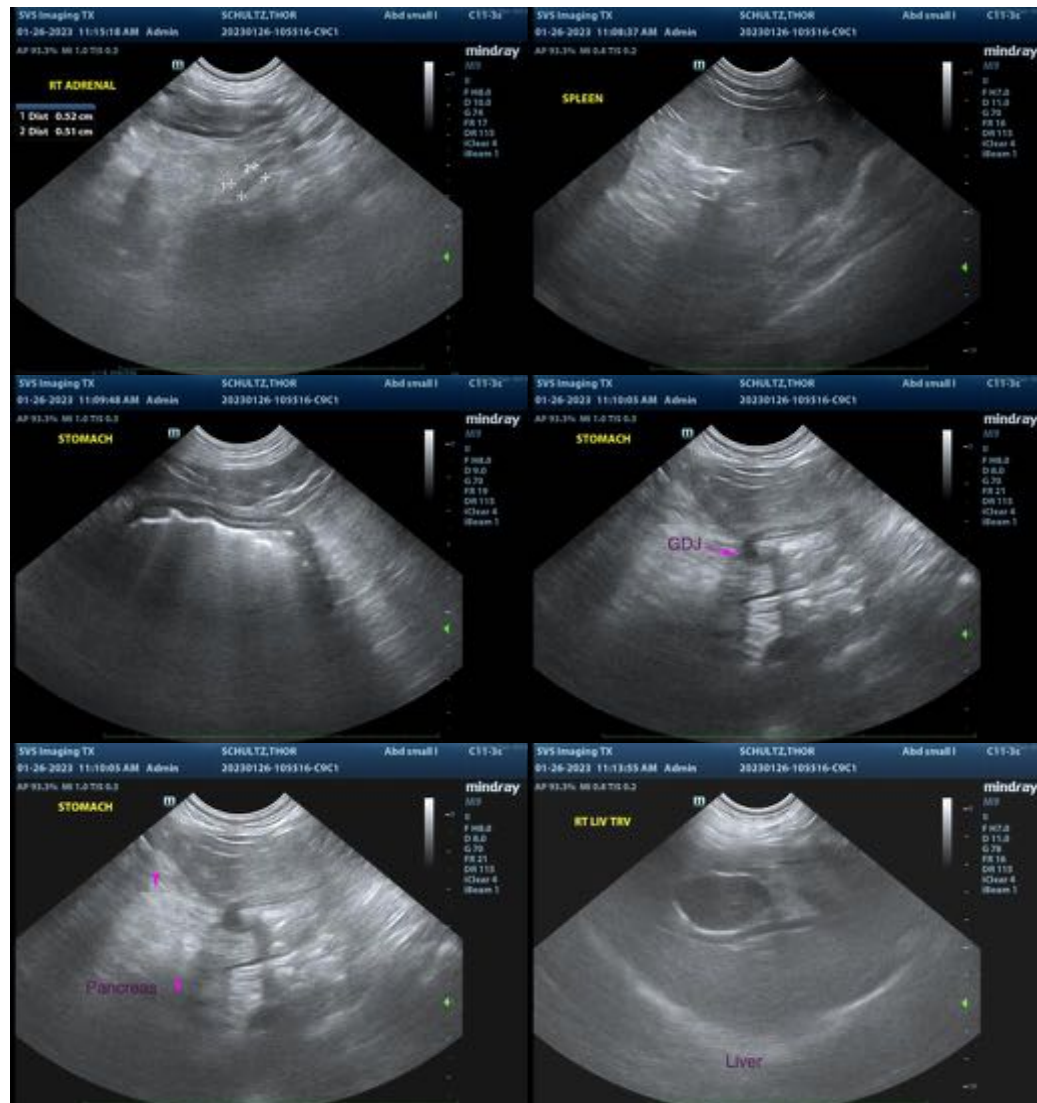
Dr Senn
Fox Lake AH

INVOICE

12101

DATE

1.26.23



IMAGING PERFORMED BY

svsimagingqc.net 309-737-3070



Clinical Sonography & Telectology

EDUCATIONAL TELECONSULTATION SERVICES™

1-800-838-4268 info@sonopath.com SonoPath.com

PATIENT

Thor Schultz

SPECIES

Canine

BREED

Goldendoodle

SEX

Neutered Male

AGE

12 years

WEIGHT

86 lbs

INTERPRETED BY

Andrea Nicastro,
DVM, Diplomate
ACVIM (Small Animal
Internal Medicine)

IMAGING PERFORMED BY

Kim Liedberg

HOSPITAL NAME

SVS Imaging WI

REFERRING VET

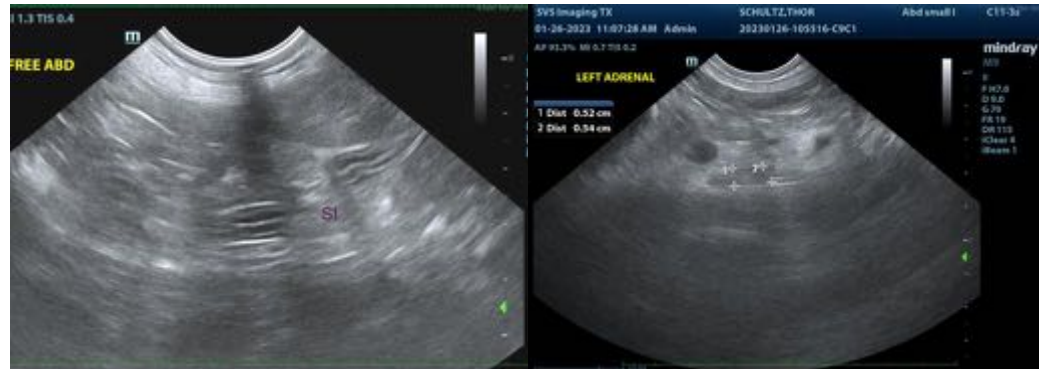Dr Senn
Fox Lake AH

INVOICE

12101

DATE

1.26.23



The information and recommendations provided are based on the images presented by the referring veterinarian/sonographer. No evaluation can be communicated regarding pathology that was not visible in the image/video clips provided.

Thank you for this referral. If the clinical or image interpretation does not parallel your findings or if I can be of any further assistance, please contact me.

Andrea Nicastro, MPH, DVM, Diplomate DACVIM (Small Animal Internal Medicine)
info@SonoPath.com