



PATIENT PRESENTING CLINICAL SIGNS

PATIENT Fox Crawford
SPECIES Feline
BREED DSH

History: P has a 2-week history of hyporexia to anorexia, lethargy, intermittent tachypnea and left front limb lameness. P has long standing history of heart murmur. Thoracic radiographs had a bronchial pattern, no signs of CHF, but cardiomegaly present. In included abdomen, splenomegaly and hepatomegaly noted, with slight loss of serosal detail. POCUS revealed a La:Ao ratio of 1.3, very scant pericardial effusion, significant hepatomegaly and splenomegaly with very course irregular echotexture of both organs, no overt mass lesions noted. Scant free abdominal fluid also present. Mild elevation in pT - 33sec, normal/unremarkable CBC

SEX Female Spayed
AGE 15

Abnormal PE/Chem/CBC/UA Results: General Appearance: Lethargic, mildly fractious Hydration: Slightly dehydrated Oral Cavity: Tartar mild Cardiovascular: Gallop rhythm, grade 3/6 systolic murmur Respiratory: Abnormal: tachypnea Abdomen: Tense on palpation, not overtly painful, p reactive to abdominal palpation Musculoskeletal: Abnormal: generalized muscle atrophy Integument: Dull hair coat Imagyst splenic sample- Findings are cytologically suggestive of normal to mildly reactive splenic tissue. spleno/hepatomegaly on rads, not suggestive of CHF PT 33 sec TFAST, La:ao ratio ~1.3, very scant pericardial effusion, no B lines, AFAST severe hepatomegaly and splenomegaly with course echotexture of each, scant free abdominal fluid present

ULTRASONOGRAPHIC EXAMINATION OF THE ABDOMEN

Urinary System

The urinary bladder wall is normal in thickness. The mucosal surface is smooth. The bladder is moderately distended. A small amount of suspended echogenic debris is observed within the lumen. No cystic calculi are observed. The region of the trigone is normal.

INTERPRETED BY

Andrea Nicastro, DVM,
 Diplomate ACVIM
 (Small Animal Internal
 Medicine)

The left kidney is mildly enlarged (4.21 cm in length) with a slightly irregular shape. The cortex is variably thickened, with poor corticomedullary distinction. Hyperechoic shadowing diverticular foci are visualized. Moderate pyelectasia is present (0.25 cm in the longitudinal plane). Small, mineralized foci are visualized. There is no evidence of hydroureter. Renal vasculature is normal. Some subcapsular fluid is present. Perirenal fat is hyperechoic.

IMAGING PERFORMED BY

Dr Huntington

The right kidney is enlarged (4.81 cm in length) with a relatively normal shape. The cortex is variably thickened, with moderate-to-severe loss of corticomedullary distinction. Moderate pyelectasia is present (0.31 cm in the longitudinal plane). Nonobstructive mineralized foci are visualized. There is no evidence of infarcts or hydroureter. Renal vasculature is normal. Trace subcapsular fluid is present. Perirenal fat is mildly hyperechoic.

HOSPITAL NAME

Wilvet South

Adrenal Glands

The left adrenal gland is normal size (0.39 cm width). Normal shape and glandular echogenicity. The phrenicoabdominal vein and surrounding vasculature are normal.

REFERRING VET

Dr Huntington

The region of the right adrenal gland is evaluated. No obvious pathology is observed in this region.

INVOICE

22456

Spleen

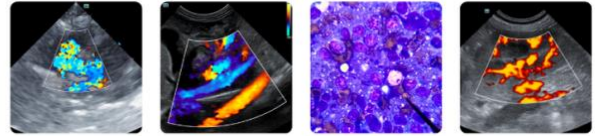
The spleen is mildly enlarged (1.22 cm in length) with swollen/irregular peripheral margins and a folded contour. The parenchyma is subtly mottled in appearance. No distinct focal lesions are observed Splenic vasculature appears normal with no obvious evidence of thrombosis.

DATE

1-25-26

Liver

The liver is subjectively enlarged, with swollen peripheral contours. The parenchyma is isoechoic relative to the spleen and mottled in appearance. No distinct focal lesions are observed. Hepatic vasculature and



PATIENT

intrahepatic biliary tracts are of normal volume with no evidence of congestion. The portal vein to caudal vena cava ratio is approximately 1: 1.

Fox Crawford

SPECIES

The gallbladder lumen is moderately distended. The wall is thin and smooth. A small-to-moderate amount of echogenic debris is observed within the lumen. The cystic and common bile ducts are normal.

Feline

Gastrointestinal

BREED

The gastric lumen is mildly distended with ingesta. The gastric wall and pylorus are normal in thickness with a normal layering pattern. The pyloric outflow tract is patent. The small intestinal lumen is not dilated. The small intestinal wall is normal in thickness with a normal layering pattern and appropriate mural detail. Discreet masses are not identified. The colonic wall is normal. There is no evidence of an obstructive pattern.

DSH

SEX

Pancreas

Female Spayed

The right limb of the pancreas is visible with normal curvilinear peripheral contours. The parenchyma is largely isoechoic relative to surrounding omental fat and slightly mottled in appearance. The pancreatic duct is visible but not overtly dilated. There is no evidence of peripancreatic inflammation or effusion.

AGE

15

Lymph Nodes

(See "Other" category).

WEIGHT

4.5 kg

Free Abdomen

Trace free fluid is observed.

INTERPRETED BY

Other

In the cranial abdomen, a 0.87 cm round- to slightly irregular hypoechoic structure is visualized. Surrounding mesentery is hyperechoic.

Andrea Nicastro, DVM,
Diplomate ACVIM
(Small Animal Internal
Medicine)

ULTRASONOGRAPHIC FINDINGS

IMAGING PERFORMED BY

Primary Findings

Dr Huntington

- The bilateral renal changes could be consistent with inflammatory disease (i.e., pyelonephritis, interstitial nephrosis/nephritis) or infiltrative neoplasia (i.e., lymphoma). The pyelectasia may be secondary to pyelonephritis, parenchymal remodeling, PU/PD (if applicable), fluid therapy (if applicable), or some combination thereof. There is evidence of retroperitonitis.

HOSPITAL NAME

Wilvet South

- The diffuse hepatic parenchymal changes could be consistent with hepatic lipidosis, an inflammatory hepatopathy (i.e., bacterial cholangiohepatitis, lymphoplasmacytic hepatitis, feline infectious peritonitis), infiltrative neoplasia (i.e., lymphoma) and/or other hepatopathy.

REFERRING VET

Dr Huntington

- The splenic parenchymal changes are most consistent with a benign process such as lymphoid hyperplasia, extramedullary hematopoiesis, splenitis or antigenic stimulation with a lower possibility of infiltrative neoplasia (i.e., lymphoma, mast cell neoplasia).

INVOICE

22456

- The origin of the hypoechoic structure in the cranial abdomen is unclear. It may represent an enlarged lymph node, pancreatic nodule, other. Differentials include neoplasia, an inflammatory process, hyperplastic lesion, other. Mild adjacent peritonitis is present.

DATE

1-25-26

- Trace ascites



PATIENT Secondary Findings

Fox Crawford

- The pancreatic changes are most consistent with age-related parenchymal remodeling, potentially secondary to a prior inflammatory episode, early fibrosis or chronic pancreatitis.

SPECIES

Feline

- Minor retained gas and ingesta

BREED

DSH

SEX

Female Spayed

INTERPRETATION OF THE FINDINGS & FURTHER RECOMMENDATIONS

- Regarding the renal changes, consider the following:
 1. Urinalysis with culture and sensitivity
 2. UPC if proteinuria is present in the absence of infection
 3. +/- renal aspiration (if clotting status and blood pressure are appropriate). A 25-gauge needle should be used.
- Regarding the hepatic changes, consider fine-needle aspiration (assuming normal clotting status). A 25-gauge needle should be used. Aerobic and anaerobic bile cultures would also be beneficial.
- Given the POCUS changes, consider a full echocardiogram.

WEIGHT

4.5 kg

INTERPRETED BY

Andrea Nicastro, DVM,
Diplomate ACVIM
(Small Animal Internal
Medicine)

IMAGING PERFORMED BY

Dr Huntington

HOSPITAL NAME

Wilvet South

REFERRING VET

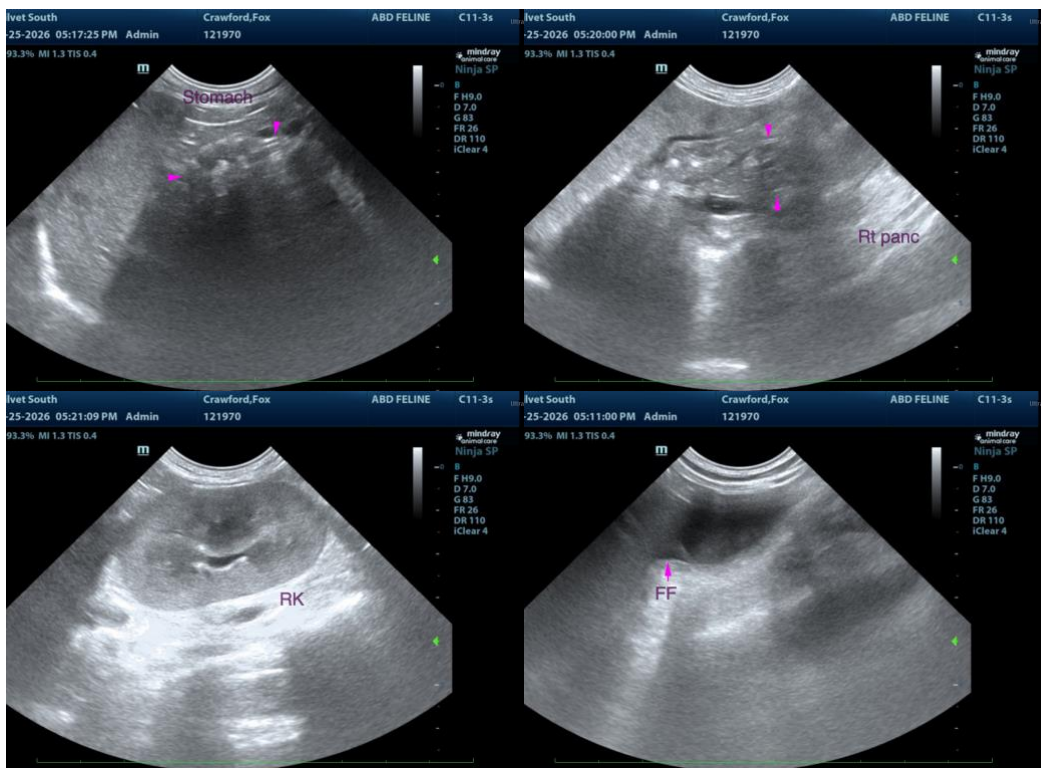
Dr Huntington

INVOICE

22456

DATE

1-25-26





PATIENT

Fox Crawford

SPECIES

Feline

BREED

DSH

SEX

Female Spayed

AGE

15

WEIGHT

4.5 kg

INTERPRETED BY

Andrea Nicastro, DVM,
Diplomate ACVIM
(Small Animal Internal
Medicine)

IMAGING PERFORMED BY

Dr Huntington

HOSPITAL NAME

Wilvet South

REFERRING VET

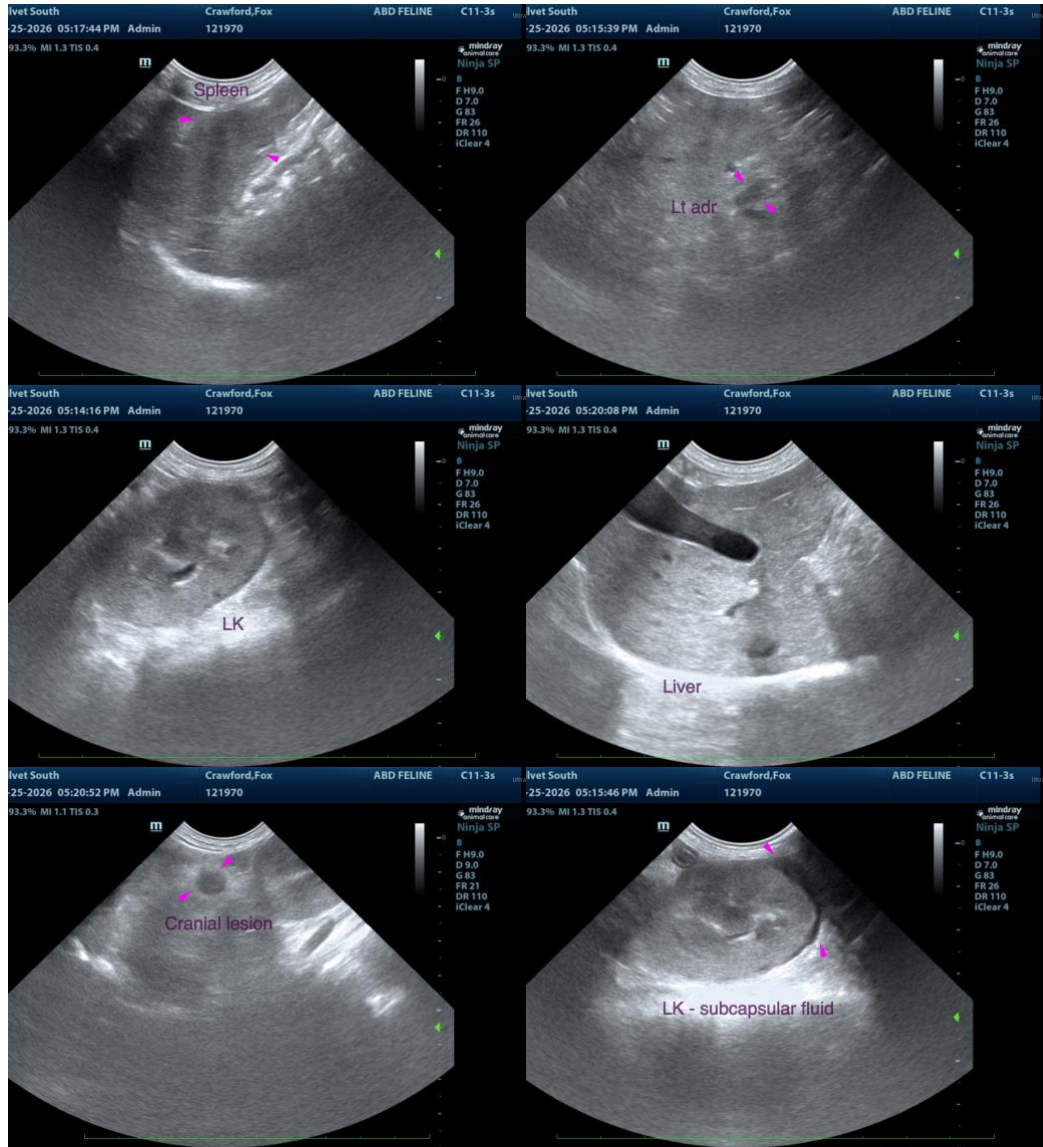
Dr Huntington

INVOICE

22456

DATE

1-25-26



The information and recommendations provided are based on the images presented by the referring veterinarian/sonographer. No evaluation can be communicated regarding pathology that was not visible in the image/video clips provided.

Thank you for this referral. If the clinical or image interpretation does not parallel your findings or if I can be of any further assistance, please contact me.

Andrea Nicastro, MPH, DVM, Diplomate DACVIM (Small Animal Internal Medicine)
info@SonoPath.com