



**PATIENT PRESENTING CLINICAL SIGNS**

Phannie Albert History: chronic history of eating sticks/wood and occasional vomiting

**SPECIES**

Abnormal PE/Chem/CBC/UA Results: BW in 11/2022 Chemistry ALB 4.0 g/dL 2.7 - 3.9 ALT 133 U/L 18 - 121 CHOL 351 mg/dL 131 - 345 TRIG 192 mg/dL 20 - 150 UA USG 1.029 pH >9 3+ protein CBC/rest of chem/cPL/T4: wnl no current UPC

Canine

**ULTRASONOGRAPHIC EXAMINATION OF THE ABDOMEN**

**BREED**

**Urinary System**

Pitbull Terrier Mix

The urinary bladder wall is normal in thickness. The mucosal surface in the region of the apex is slightly irregular. The bladder lumen is moderately distended with anechoic urine. No masses, inflammatory changes or calculi are observed. The region of the trigone and visible portion of the proximal urethra are normal.

**SEX**

Spayed Female

The left kidney is normal in size (6.01 cm in length) with a normal shape, architecture and smooth peripheral margins. There is a normal 1:3 cortex to medulla ratio with minimal to mild loss of corticomedullary distinction. There is no evidence of pyelectasia, nephroliths, infarcts or hydroureter.

**AGE**

14 years

The right kidney is normal in size (6.87 cm in length) with a normal shape, architecture and smooth peripheral margins. There is a normal 1:3 cortex to medulla ratio with mild loss of corticomedullary distinction. There is no evidence of pyelectasia, nephroliths, infarcts or hydroureter.

**WEIGHT**

**Adrenal Glands**

36 lbs

The left adrenal gland is normal in size (0.51 cm at cranial pole) (0.70 cm at caudal pole) with a normal shape and homogenous parenchyma. The glandular echogenicity and detail are unremarkable. Capsule, cortex, and medullary definition are normal. The phrenicoabdominal vein and surrounding vasculature are normal.

**INTERPRETED BY**

Andrea Nicastro, DVM,  
Diplomate ACVIM (*Small  
Animal Internal Medicine*)

The right adrenal gland is in normal size (1.43 cm at cranial pole) (0.67 cm at caudal pole) with a normal shape and homogenous parenchyma. The glandular echogenicity and detail are unremarkable. Capsule, cortex, and medullary definition are normal. The phrenicoabdominal vein and surrounding vasculature are normal.

**IMAGING PERFORMED BY**

Christina Sitton

**Spleen**

The spleen is normal in size (1.89 cm in width at the level of the hilus) with a normal capsular contour. There is appropriate echogenicity and echotexture. No focal lesions are observed. Splenic vasculature is normal.

**HOSPITAL NAME**

Sherwood Family PC

**Liver**

The liver is subjectively normal in size with normal contours and structure. There is appropriate echogenicity and echotexture. No overt structural evidence of inflammatory, infiltrative, or regenerative pathology is evident. Vascular and biliary tracts are of normal volume with no evidence of congestion. No pathological hepatic lymphadenopathy observed.

**REFERRING VET**

Christina Sitton

The gall bladder lumen is moderately distended. The wall is thin and smooth. Luminal contents are anechoic. The cystic and common bile ducts are normal/not seen.

**INVOICE**

**Gastrointestinal**

12087

The lumen is not distended. The gastric wall is normal in thickness with a normal layering pattern. The small intestinal lumen is not dilated. The small intestinal wall thickness is normal with a normal layering pattern and appropriate mural detail. Discreet masses are not identified. The colonic wall is normal. There is no evidence of an obstructive pattern.

**DATE**

1.25.23

### ***Pancreas***

The region of the pancreas is isoechoic relative to surrounding omental fat. No obvious parenchymal abnormalities are observed. There is no evidence of regional inflammation or effusion.

### ***Free Abdomen***

The peritoneal cavity is normal. There is no evidence of inflammation or effusion. The abdominal lymph nodes are normal/not visible.

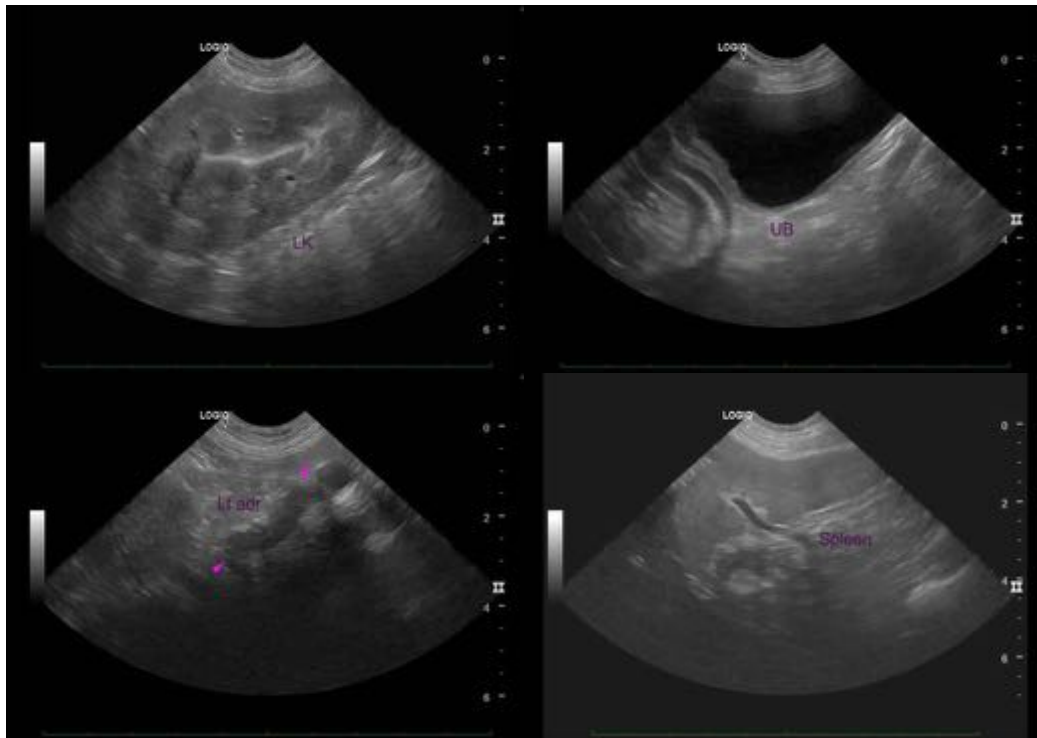
## **ULTRASONOGRAPHIC FINDINGS**

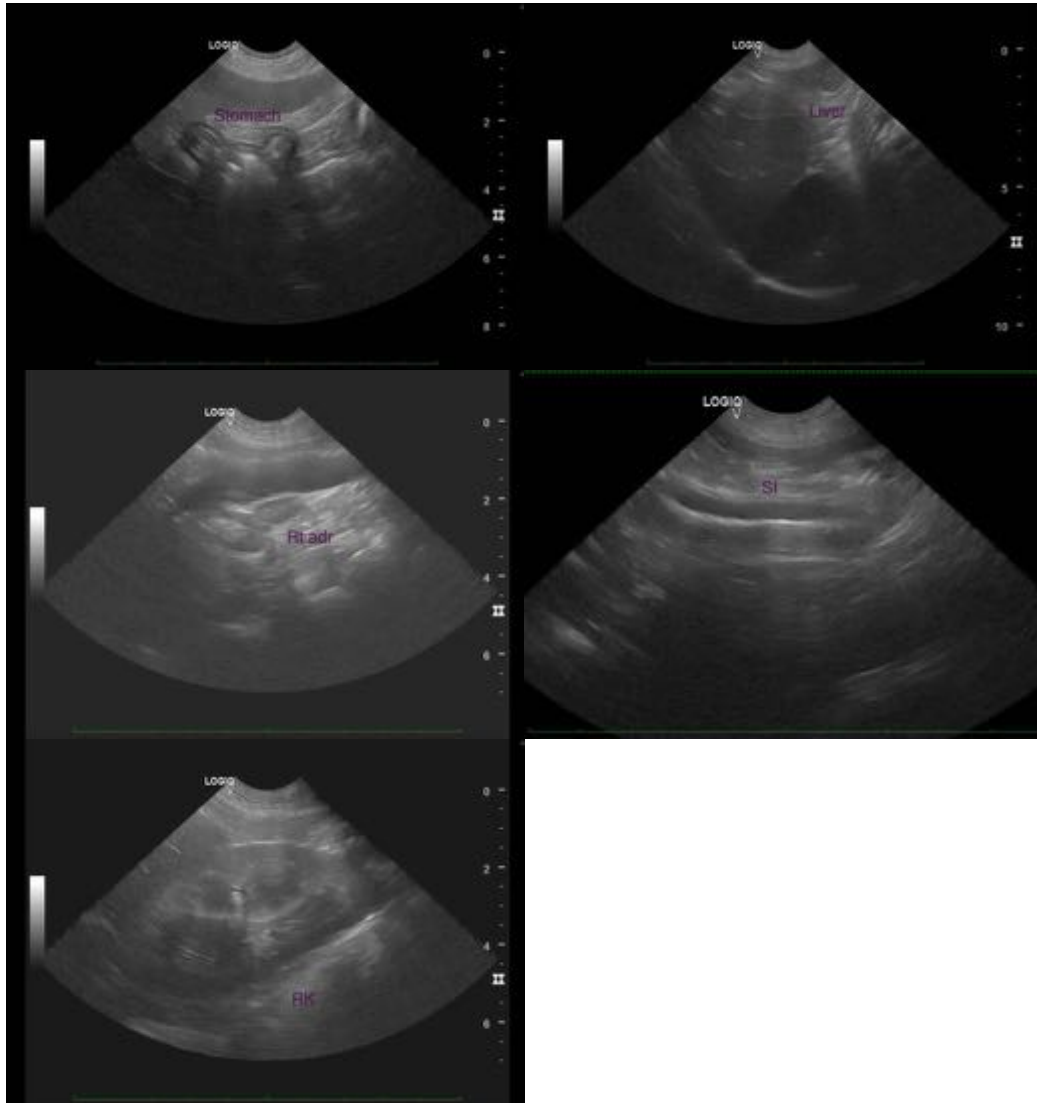
### **Primary Findings**

- Minor bilateral age-related renal changes. The remainder of the abdomen is unremarkable.

### **INTERPRETATION OF THE FINDINGS & FURTHER RECOMMENDATIONS**

- Regarding the proteinuria, a urine culture and sensitivity is recommended. If culture results are negative, a UPC should be performed.
- Given the slightly elevated ALT, serial monitoring (i.e., every 3-4 months) of the patient's liver values is also recommended.





The information and recommendations provided are based on the images presented by the referring veterinarian/sonographer. No evaluation can be communicated regarding pathology that was not visible in the image/video clips provided.

Thank you for this referral. If the clinical or image interpretation does not parallel your findings or if I can be of any further assistance, please contact me.

**Andrea Nicastro**, MPH, DVM, Diplomate DACVIM (Small Animal Internal Medicine)  
[info@SonoPath.com](mailto:info@SonoPath.com)