



PATIENT PRESENTING CLINICAL SIGNS

Coco Carrel History: Bloody stool, blood in rectum, explosive diarrhea.

SPECIES

Canine

BREED

Shih Tzu Mix

SEX

Spayed Female

AGE

7 years

WEIGHT

12.1 lbs

INTERPRETED BY

Andrea Nicastro, DVM,
Diplomate ACVIM (*Small
Animal Internal Medicine*)

**IMAGING
PERFORMED BY**

Kelly Vazquez

HOSPITAL NAME

Animal Gen Hudson

REFERRING VET

Dr. Krstevski

INVOICE

12098

DATE

1.25.23

Abnormal PE/Chem/CBC/UA Results: RBC 9.16, K 3.2.

ULTRASONOGRAPHIC EXAMINATION OF THE ABDOMEN

Urinary System

The urinary bladder wall is normal in thickness and the mucosal surface is smooth. The bladder lumen is mildly distended with anechoic urine. No masses, inflammatory changes or calculi are observed. Ureteral papillae and visualized portion of the proximal urethra, visible to a depth of 1-2 cm, are normal.

The left kidney is normal in size (3.89 cm in length) with a normal shape, architecture and smooth peripheral margins. There is a normal 1:3 cortex to medulla ratio with normal corticomedullary distinction. There is no evidence of pyelectasia, nephroliths, infarcts or hydronephrosis. Renal vasculature is normal.

The right kidney is normal in size (3.41 cm in length) with a normal shape, architecture and smooth peripheral margins. There is a normal 1:3 cortex to medulla ratio with normal corticomedullary distinction. There is no evidence of pyelectasia, nephroliths, infarcts or hydronephrosis. Renal vasculature is normal.

Adrenal Glands

The left adrenal gland is normal in size (0.43 cm at cranial pole) (0.48 cm at caudal pole) (1.59 cm in length) with a normal shape and homogenous parenchyma. The glandular echogenicity and detail are unremarkable. Capsule, cortex, and medullary definition are normal. The phrenicoabdominal vein and surrounding vasculature are normal.

The right adrenal gland is in normal size (0.50 cm at cranial pole) (0.40 cm at caudal pole) (1.66 cm in length) with a normal shape and homogenous parenchyma. The glandular echogenicity and detail are unremarkable. Capsule, cortex, and medullary definition are normal. The phrenicoabdominal vein and surrounding vasculature are normal.

Spleen

The spleen is normal in size (0.98 cm in width at the level of the hilus) with a normal capsular contour. There is appropriate echogenicity and echotexture. No focal lesions are observed. Splenic vasculature is normal.

Liver

The liver is subjectively normal in size with normal contours and structure. There is appropriate echogenicity and echotexture. No overt structural evidence of inflammatory, infiltrative, or regenerative pathology is evident. Vascular and biliary tracts are of normal volume with no evidence of congestion. No pathological hepatic lymphadenopathy observed.

The gall bladder lumen is moderately distended. The wall is thin and smooth. Luminal contents are anechoic. The cystic and common bile ducts are normal/not seen.

Gastrointestinal

The gastric lumen is mildly to moderately distended with ingesta. The gastric wall is normal in thickness with a normal layering pattern. The small intestinal lumen is not dilated. The small intestinal wall thickness is normal with a normal layering pattern and appropriate mural detail. Discrete masses are not identified. The colonic wall is normal. The colonic lumen contains shadowing fecal material. There is no obvious evidence of an obstructive pattern.

Pancreas

The region of the pancreas is isoechoic relative to surrounding omental fat. No obvious parenchymal abnormalities are observed. There is no evidence of regional inflammation or effusion.

Free Abdomen

The peritoneal cavity is normal. There is no evidence of inflammation or effusion. The abdominal lymph nodes are normal/not visible.

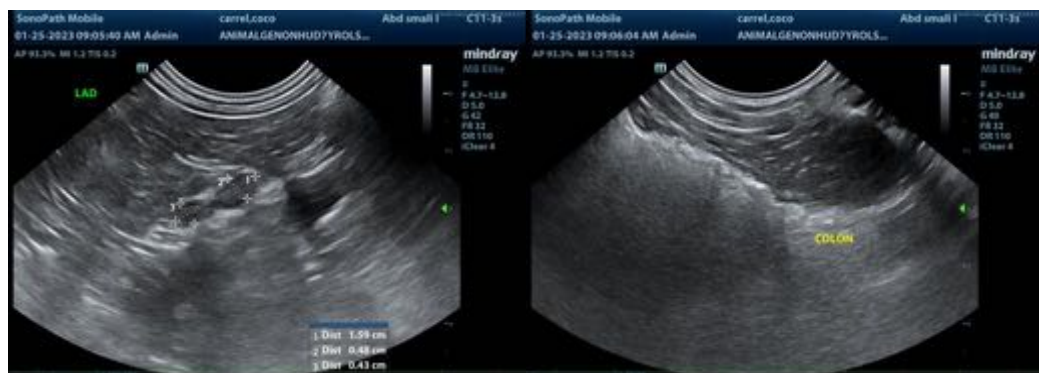ULTRASONOGRAPHIC FINDINGS

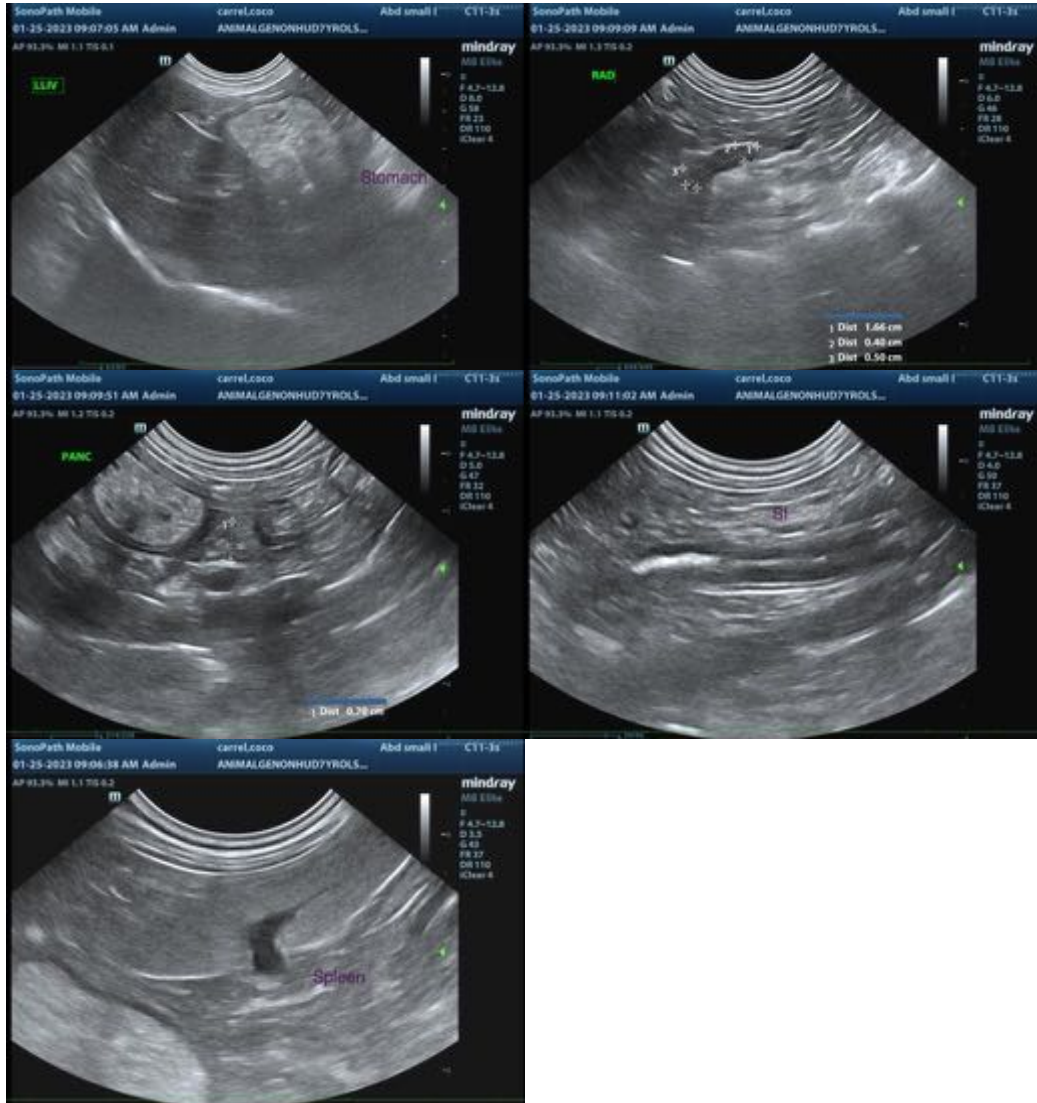
Primary Findings

- If the patient was fasted for this study, the presence of ingesta within the gastric lumen could suggest delayed gastric emptying.
- *An obvious cause for the patient's clinical signs is not identified in this study. Considerations include dietary indiscretion, infectious/parasitic disease, acute hemorrhagic gastroenteritis, food allergy/intolerance, underlying metabolic issue, other.

INTERPRETATION OF THE FINDINGS & FURTHER RECOMMENDATIONS

- Fecal evaluation for ova and Giardia (if not already performed)
- Consider a fecal PCR infectious disease panel.
- Also consider a resting cortisol level to screen for atypical hypoadrenocorticism.
- Prophylactic deworming with Fenbendazole is recommended, along with a bland diet, probiotic, fiber supplement and other symptomatic measures.
- If clinical signs do not improve with medical management, a more advanced GI work-up (i.e., GI panel, biopsies) may be warranted.





The information and recommendations provided are based on the images presented by the referring veterinarian/sonographer. No evaluation can be communicated regarding pathology that was not visible in the image/video clips provided.

Thank you for this referral. If the clinical or image interpretation does not parallel your findings or if I can be of any further assistance, please contact me.

Andrea Nicastro, MPH, DVM, Diplomate DACVIM (Small Animal Internal Medicine)
info@SonoPath.com

