



PATIENT

George Durfee

SPECIES

Canine

BREED

Labrador Retriever

SEX

Male, neutered

AGE

2.5 Yrs.

WEIGHT

38 kg.

INTERPRETED BY

Andrea Nicastro, DVM,
Diplomate ACVIM
(*Small Animal Internal
Medicine*)

**IMAGING
PERFORMED BY**

Dr. Stegemoller

HOSPITAL NAME

North Idaho AH

REFERRING VET

Dr. Segemoller

INVOICE

14494

DATE

1/24/23

PRESENTING CLINICAL SIGNS

History: Presented 1/17 for acute vomiting/lethargy and some soft stool. Treated supportively as no signs of GI obstruction present. Patient has failed to respond to supportive therapy and continues to feel lethargic, have minimal appetite, and soft stool. Patient continues to have a depressed attitude as minimal restraint needed for ultrasound or IV catheter placement. Performed radiographs and initial ultrasound on 1/17, repeated full abdominal ultrasound today.

Abnormal PE/Chem/CBC/UA Results: 1/23 - CBC WNL, Chem 17/lytes WNL 1/17 - CBC WNL, Chem 17/lytes WNL Pending diarrhea PCR, fecal O&P NPS, pending resting cortisol and specCPL

ULTRASONOGRAPHIC EXAMINATION OF THE ABDOMEN

Urinary System

The urinary bladder wall is normal in thickness and the mucosal surface is smooth. The bladder lumen is moderately distended with anechoic urine. No masses, inflammatory changes or calculi are observed. The region of the trigone is normal.

The prostate is not definitively visualized due to its pelvic location.

The left kidney is normal size (6.79 cm in length); normal shape and architecture with smooth peripheral margins. There is a normal 1:3 cortex to medulla ratio with normal corticomedullary distinction. There is no evidence of pyelectasia, nephroliths, infarcts or hydroureter. Renal vasculature is normal.

The right kidney is normal size (7.15 cm in length); normal shape and architecture with smooth peripheral margins. There is a normal 1:3 cortex to medulla ratio with normal corticomedullary distinction. There is no evidence of pyelectasia, nephroliths, infarcts or hydroureter. Renal vasculature is normal.

Adrenal Glands

The left adrenal gland is normal to slightly small in size (0.58 cm at cranial pole) (0.58 cm at caudal pole) (2.61 cm in length); normal shape; smooth peripheral contours. The glandular echogenicity and detail are unremarkable. Capsule, cortex, and medullary definition are normal. The phrenicoabdominal vein and surrounding vasculature are normal.

The right adrenal gland is normal to slightly small in size (0.26 cm at cranial pole) (0.59 cm at caudal pole) (2.60 cm in length); normal shape; smooth peripheral contours. The glandular echogenicity and detail are unremarkable. Capsule, cortex, and medullary definition are normal. The phrenicoabdominal vein and surrounding vasculature are normal.

Spleen

The spleen is normal in size (2.38 cm in width at the level of the hilus) with a normal capsular contour. The parenchyma is subtly mottled in appearance. No focal lesions are observed. Splenic vasculature is normal.

Liver

The liver is subjectively normal in size with normal contours and structure. There is appropriate echogenicity and echotexture. No overt structural evidence of inflammatory, infiltrative or regenerative pathology is evident. Vascular and biliary tracts are of normal volume with no evidence of congestion. No pathological hepatic lymphadenopathy observed. The gall bladder lumen is moderately distended. The wall is thin and smooth. Luminal contents are anechoic. The cystic and common bile ducts are normal/not seen.



PATIENT

George Durfee

SPECIES

Canine

BREED

Labrador Retriever

SEX

Male, neutered

AGE

2.5 Yrs.

WEIGHT

38 kg.

INTERPRETED BY

Andrea Nicastro, DVM,
Diplomate ACVIM
(*Small Animal Internal
Medicine*)

**IMAGING
PERFORMED BY**

Dr. Stegemoller

HOSPITAL NAME

North Idaho AH

REFERRING VET

Dr. Segemoller

INVOICE

14494

DATE

1/24/23

Gastrointestinal

The gastric lumen is not distended. The gastric wall is normal in thickness with a normal layering pattern. The small intestinal lumen is segmentally dilated with chyme (mild). The small intestinal wall thickness is normal with a normal layering pattern and appropriate mural detail. Discreet masses are not identified. The colonic wall is normal. There is no evidence of an obstructive pattern.

Pancreas

The region of the pancreas is isoechoic relative to surrounding omental fat. No obvious parenchymal abnormalities are observed. There is no evidence of regional inflammation or effusion.

Free Abdomen

Trace free fluid is observed. A few prominent mesenteric lymph nodes are visualized, the largest measuring 2.07 cm in length. The nodes are normal in shape and echogenicity.

ULTRASONOGRAPHIC FINDINGS

- The splenic parenchymal changes are most consistent with a benign process such as lymphoid hyperplasia, extramedullary hematopoiesis, splenitis or antigenic stimulation with a low possibility of infiltrative neoplasia (i.e., lymphoma, mast cell neoplasia).
- The prominent abdominal lymph nodes are most consistent with reactive lymphadenitis or lymphoid hyperplasia. Neoplastic infiltration is considered less likely.
- Trace ascites.
- The borderline small adrenal glands may be a normal variant for this patient or may represent early atrophy (i.e., secondary to hypoadrenocorticism).

*An obvious cause for the patient's clinical signs is not identified in this study. Differentials include microscopic gastrointestinal disease (i.e., food allergy/intolerance, infectious/parasitic disease, inflammatory bowel disease), mild pancreatitis, underlying metabolic issue (i.e., hypoadrenocorticism), other.

INTERPRETATION OF THE FINDINGS & FURTHER RECOMMENDATIONS

- A malabsorption panel including serum cobalamin, folate, TLI and PLI should be considered.
- Consider prophylactic deworming with Fenbendazole if not already performed.
- Also consider a 6 week hydrolyzed protein or limited antigen diet trial if/when the patient is eating well.
- Initiation of a probiotic as well as a fiber supplement is also recommended.
- Depending on the results of the above diagnostics as well as the impending test results, GI biopsies (i.e., endoscopic or surgical) may be necessary to get a definitive diagnosis.



PATIENT

George Durfee

SPECIES

Canine

BREED

Labrador Retriever

SEX

Male, neutered

AGE

2.5 Yrs.

WEIGHT

38 kg.

INTERPRETED BY

Andrea Nicastro, DVM,
Diplomate ACVIM
(Small Animal Internal
Medicine)

IMAGING PERFORMED BY

Dr. Stegemoller

HOSPITAL NAME

North Idaho AH

REFERRING VET

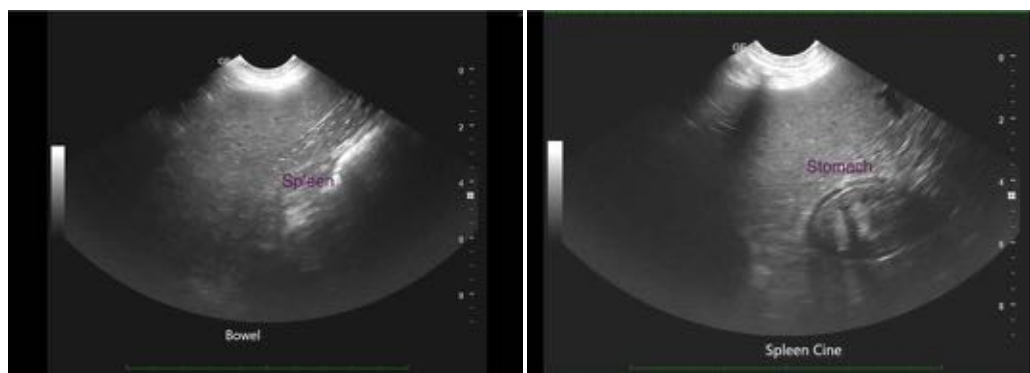
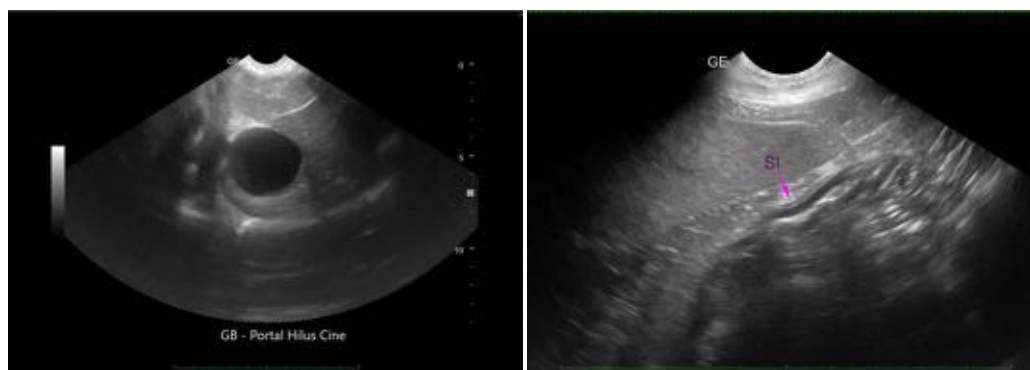
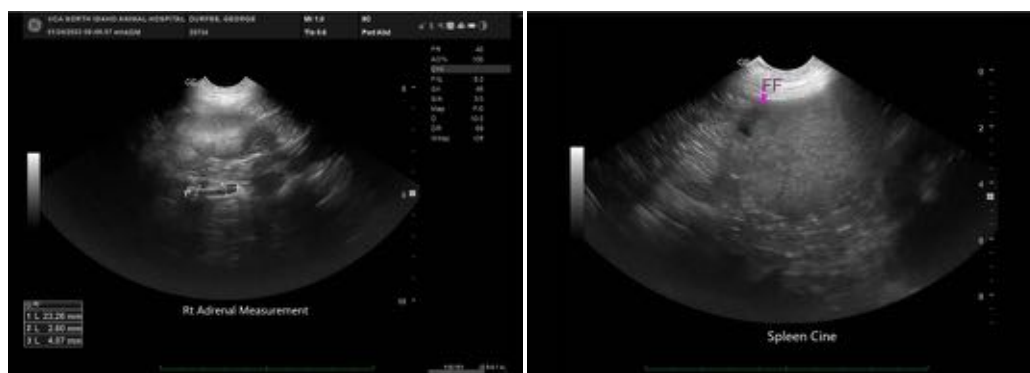
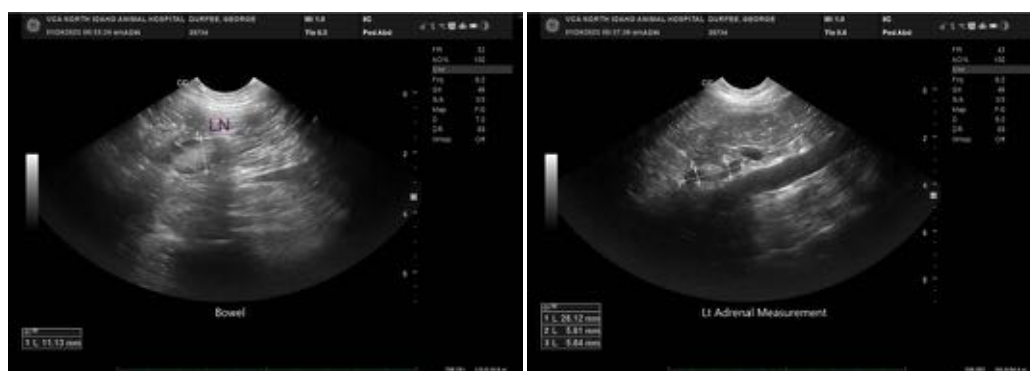
Dr. Segemoller

INVOICE

14494

DATE

1/24/23



The information and recommendations provided are based on the images presented by the referring veterinarian/sonographer. No evaluation can be communicated regarding pathology that was not visible



PATIENT

George Durfee

in the image/video clips provided.

Thank you for this referral. If the clinical or image interpretation does not parallel your findings or if I can be of any further assistance please contact me.

SPECIES

Canine

Andrea Nicastro, MPH, DVM, Diplomate DACVIM (Small Animal Internal Medicine)
info@SonoPath.com

BREED

Labrador Retriever

SEX

Male, neutered

AGE

2.5 Yrs.

WEIGHT

38 kg.

INTERPRETED BY

Andrea Nicastro, DVM,
Diplomate ACVIM
(*Small Animal Internal
Medicine*)

**IMAGING
PERFORMED BY**

Dr. Stegemoller

HOSPITAL NAME

North Idaho AH

REFERRING VET

Dr. Segemoller

INVOICE

14494

DATE

1/24/23