

**DATE PRESENTING CLINICAL SIGNS**

1/24/22

History: anorexia/vomiting, lethargy - 48 hours - owner notes weight loss. Has been spending more time in litter box - possible eating litter.

PATIENT

Slinky Isensee-Cox

Current Medications: iv fluids, Cerenia, Enrofloxacin.

Lab Results: normal cbc/chem- stress leukogram, UA - wnl, pro-BNP - pending, T4 - pending.

Date of Previous IntraPet Ultrasound: No previous IntraPet scans.

Sedation: Not required to complete full diagnostic ultrasound.

Stat Report: Declined.

SPECIES

Feline

Imaging Performed By: Stephanie Pearce RDCS, RVT.

BREED

Domestic shorthair

ULTRASONOGRAPHIC EXAMINATION OF THE ABDOMEN**Urinary System**

The urinary bladder, trigone, and pelvic urethra are normal in thickness and the mucosal surface is smooth. The bladder lumen is mildly to moderately distended. A scant amount of suspended echogenic debris is observed within the lumen. No masses, inflammatory changes or calculi are observed. Ureteral papillae and visualized portion of the proximal urethra, visible to a depth of 2 cm, are normal.

SEX

Female, spayed

The left kidney is normal size (3.47 cm in length); normal shape and architecture with smooth peripheral margins. There is a normal 1:3 cortex to medulla ratio with minimal to mild loss of corticomedullary distinction. There is no evidence of pyelectasia, nephroliths, infarcts or hydroureter. Renal vasculature is normal.

AGE

3/2/2006

WEIGHT

7.3 lbs.

The right kidney is normal size (3.63 cm in length); normal shape and architecture with smooth peripheral margins. There is a normal 1:3 cortex to medulla ratio with minimal to mild loss of corticomedullary distinction. A few small non-obstructive nephroliths are visualized. Trace pyelectasia is present. There is no evidence of infarcts or hydroureter. Renal vasculature is normal.

INTERPRETED BY

Andrea Nicastro, DVM,
Diplomate ACVIM
(Small Animal Internal
Medicine)

Adrenal Glands

The left adrenal gland is normal in size (0.51 cm width). Normal shape and glandular echogenicity. The phrenicoabdominal vein and surrounding vasculature are normal.

The right adrenal gland is normal in size (0.50 cm width). Normal shape and glandular echogenicity. The phrenicoabdominal vein and surrounding vasculature are normal.

HOSPITAL NAME

Eastern AH

Spleen

The spleen is subjectively normal in size (0.65 cm in width at the level of the hilus) with scalloping of the medial contour. Using the high frequency probe, the parenchyma is diffusely mottled with a "moth-eaten" appearance. No focal lesions are observed. Splenic vasculature is normal.

REFERRING VET

Dr. Kaufman

Liver

The liver is subjectively normal in size with normal curvilinear peripheral contours. The parenchyma is hypoechoic relative to the spleen. A 4.95 x 2.85 cm irregular hyperechoic to heterogeneous multi-septated cystic mass is observed deep on the right side adjacent to the diaphragm. The remaining parenchyma is relatively homogeneous in appearance. Vascular and biliary tracts are of normal volume with no evidence of congestion. The gall bladder lumen is moderately distended. The wall is normal in thickness. A small amount of aggregated echogenic mostly gravity-dependent debris/sludge is observed within the lumen. The cystic and common bile ducts are normal/not seen.

INVOICE

12897

Gastrointestinal

The gastric lumen is mildly fluid distended. The gastric wall and pylorus are normal in thickness with a normal layering pattern. The pyloric outflow tract is patent. The small intestinal lumen is not dilated. The small

intestinal wall is normal to mildly thickened (up to 0.33 cm) with a normal layering pattern and appropriate mural detail. There is disruption in the normal 1:3 muscularis: mucosal ratio with a >1:1 ratio in some segments. Discreet masses are not identified. The ileocecal colic junction and colonic wall are normal. No obstructive disease is noted.

Pancreas

The region of the pancreas is isoechoic relative to surrounding omental fat. No obvious parenchymal abnormalities are observed. There is no evidence of regional inflammation or effusion.

Free Abdomen

The mesentery throughout the abdomen is hyperechoic. A small amount of free fluid is observed. 2 severely enlarged rounded hypoechoic to slightly heterogeneous lymph nodes were observed at the mesenteric root, the largest measuring 4.29 cm in length. Surrounding mesentery is hyperechoic. In addition, 1-2 prominent lymph nodes are observed in the right cranial quadrant, the largest measuring 1.17 cm in length. A few smaller nodes are observed adjacent to the larger nodes.

ULTRASONOGRAPHIC FINDINGS

Primary Findings:

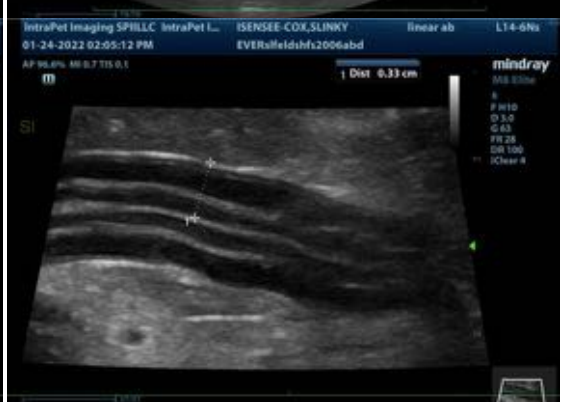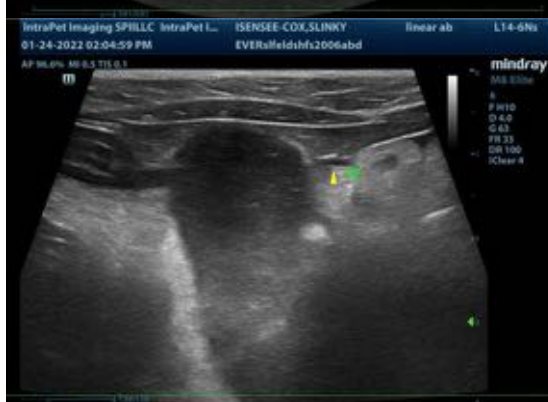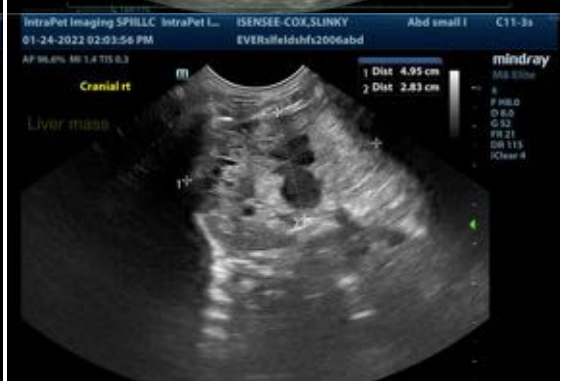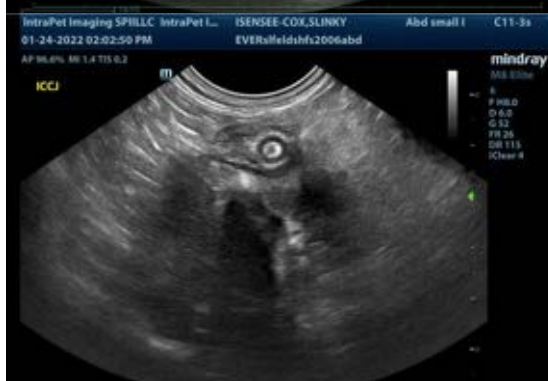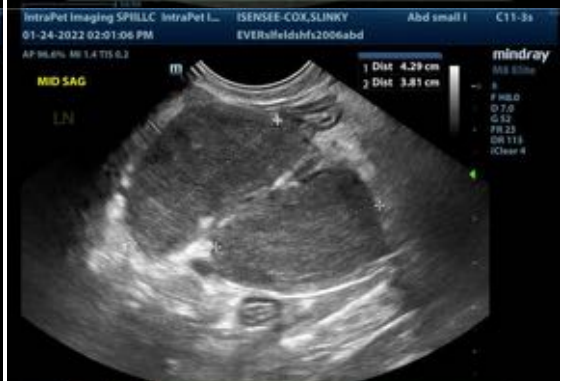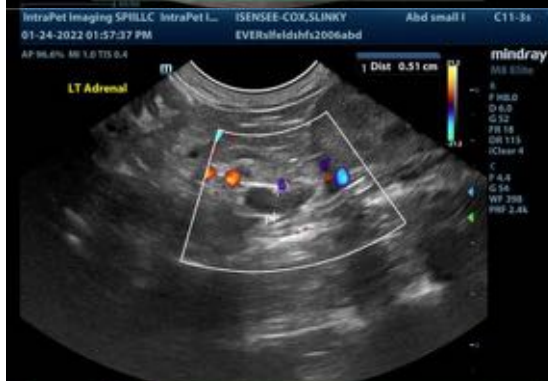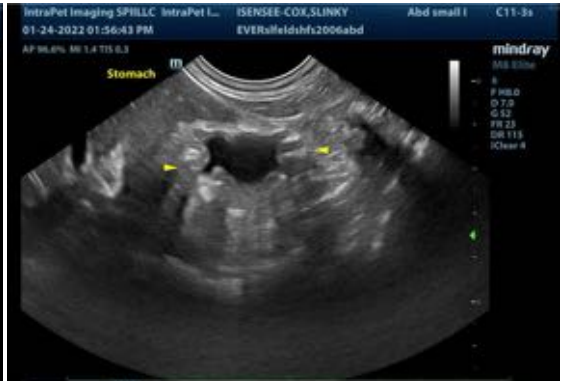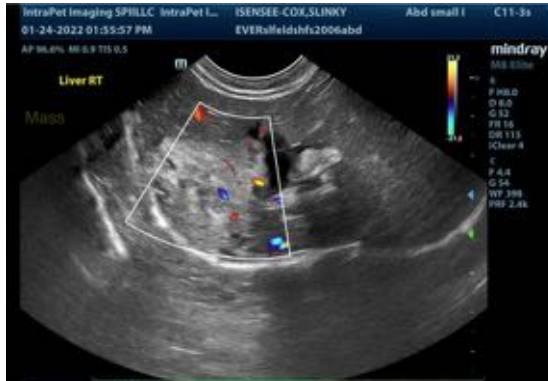- The abdominal lymphadenopathy is most consistent with infiltrative neoplasia. Lymphoma is the top differential. A severe inflammatory process (i.e., pyogranulomatous) however, cannot be completely excluded.
- Bowel pattern consistent with emerging lymphoma or severe inflammatory bowel disease.
- Diffuse peritonitis, likely secondary to bowel and/or lymph node pathology.
- The splenic parenchymal changes are most consistent with infiltrative neoplasia (i.e., lymphoma) with a lower possibility of a benign process.
- The cystic hepatic mass is most consistent with a biliary cyst adenoma or cyst adenocarcinoma.

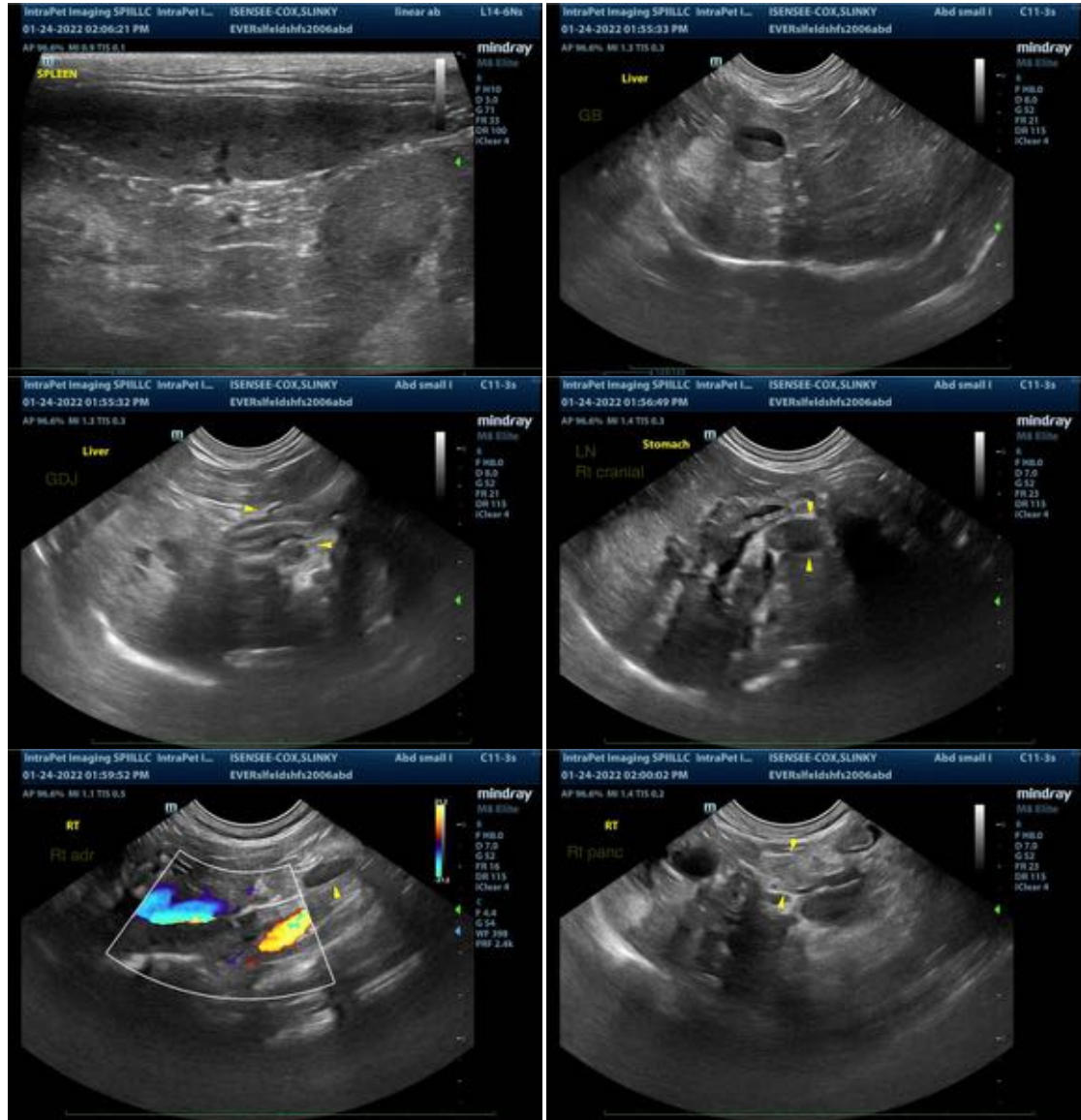
Secondary Findings:

- Bilateral age-related renal changes with right non-obstructive nephrolithiasis.

INTERPRETATION OF THE FINDINGS & FURTHER RECOMMENDATIONS

- Three-view thoracic radiographs are recommended to assess for lymphadenopathy in the chest.
- Fine needle aspirates of the enlarged abdominal lymph nodes and spleen are recommended if clotting status is appropriate. If cytology results are inconclusive, consider PARR or surgical biopsies.





The information and recommendations provided are based on the images presented by the referring veterinarian. No evaluation can be communicated regarding pathology that was not visible in the image/video clips provided.

Thank you for this referral. If the clinical or image interpretation does not parallel your findings or if I can be of any further assistance please contact me.

Andrea Nicastro, DVM, Diplomate ACVIM (*Small Animal Internal Medicine*)
 Andrea.nicastro@sonopath.com