



PATIENT PRESENTING CLINICAL SIGNS

- Teddy Youngen
- Investigate cause of systemic hypertension controlled with amlodipine
 - Left ventricular hypertrophy with dilated aortic root and mild aortic insufficiency
- SPECIES**
- Bloodwork largely normal

Canine Abnormal PE/Chem/CBC/UA Results: ALT 137. Triglycerides 683. PSL 251.

BREED ULTRASONOGRAPHIC EXAMINATION OF THE ABDOMEN

Labradoodle **Urinary System**

The urinary bladder wall is normal in thickness. The mucosal surface is smooth. The bladder is moderately distended. Luminal contents are anechoic. No cystic calculi are observed. The region of the trigone and the proximal urethra, visible to a depth of 1.5-2.0 cm, are normal.

SEX

Neutered Male

The prostate is normal in size (1.03 cm in width) and shape. Parenchyma is homogenous. The prostatic urethra appears normal without evidence of dilation or obstruction.

AGE

13 years 7 mos

The left kidney is normal in size (6.36 cm in length) with a normal shape, smooth peripheral margins, and normal internal architecture. There is mild loss of corticomedullary distinction. Several hyperechoic shadowing diverticular foci are observed. A few, small, cortical cysts are seen. There is no evidence of pyelectasia, infarcts or hydronephrosis. Renal vasculature is normal.

WEIGHT

43.4 lbs

The right kidney is normal in size (5.99 cm in length) with a slightly irregular shape. There is mild loss of corticomedullary distinction. Several hyperechoic shadowing diverticular foci are observed. There is no evidence of pyelectasia, infarcts or hydronephrosis. Renal vasculature is normal.

INTERPRETED BY

Andrea Nicastro, DVM,
Diplomate ACVIM
(Small Animal Internal
Medicine)

IMAGING PERFORMED BY

Melinda Persson

Adrenal Glands

The left adrenal gland is enlarged (0.88 cm at cranial pole) (0.98 cm at caudal pole) with swollen peripheral contours. The parenchyma is mildly heterogenous, with some loss of glandular detail. At the caudal pole, a 0.88 x 0.77 hypoechoic nodule is seen. The phrenicoabdominal vein and surrounding vasculature are normal.

HOSPITAL NAME

At Home Veterinary

The right adrenal gland is enlarged (1.11 cm at cranial pole) (0.96 cm at caudal pole) swollen peripheral contours. Glandular echogenicity and detail are normal. The phrenicoabdominal vein and surrounding vasculature are normal.

REFERRING VET

Melinda Persson

Spleen

The spleen is normal in size (1.93 cm in width at the level of the hilus) with a normal capsular contour. There is appropriate echogenicity and echotexture. No focal lesions are observed. Splenic vasculature is normal.

INVOICE

22426

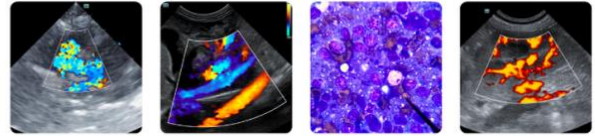
DATE

1-22-26

Liver

The liver is subjectively prominent in size with swollen curvilinear peripheral contours. The parenchyma is isoechoic relative to the spleen and exhibits mild heterogeneity. No distinct focal lesions are observed. Hepatic vasculature and biliary tracts are of normal volume with no evidence of congestion.

The gallbladder lumen is moderately distended. The wall is thin and smooth. A small amount of aggregated, echogenic, gravity-dependent debris/sludge is observed within the lumen. The cystic and common bile ducts are normal/not seen.



PATIENT *Gastrointestinal*

Teddy Youngen

The lumen is not distended. The gastric wall is normal in thickness with a normal layering pattern. The small intestinal lumen is not dilated. The small intestinal wall thickness is normal with a normal layering pattern and appropriate mural detail. Discreet masses are not identified. The colonic wall is normal. There is no evidence of an obstructive pattern.

SPECIES

Canine

Pancreas

The region of the pancreas is isoechoic relative to surrounding omental fat. No obvious parenchymal abnormalities are observed. There is no evidence of regional inflammation or effusion.

BREED

Labradoodle

Lymph Nodes

The abdominal lymph nodes are normal/not visible.

SEX

Neutered Male

Free Abdomen

The peritoneal cavity is normal. There is no evidence of inflammation or effusion.

AGE

13 years 7 mos

ULTRASONOGRAPHIC FINDINGS

WEIGHT

43.4 lbs

- Bilateral adrenomegaly. The left adrenal nodule could be consistent with focal nodular hyperplasia, adenoma, emerging adenocarcinoma, pheochromocytoma, other.
- Mild bilateral nonspecific age-related renal changes with subtly dystrophic mineralization and small left cortical cysts
- The diffuse hepatic changes are nonspecific and could be consistent with vacuolar hepatopathy, regenerative nodular hyperplasia, and/or age-related remodeling. Inflammatory disease, infiltrative neoplasia and other hepatopathies are considered less likely. However, correlation with the patient's liver values is recommended.
- Gall bladder sludge, non-mucocele

INTERPRETED BY

Andrea Nicastro, DVM,
Diplomate ACVIM
(Small Animal Internal
Medicine)

IMAGING PERFORMED BY

Melinda Persson

HOSPITAL NAME

At Home Veterinary

INTERPRETATION OF THE FINDINGS & FURTHER RECOMMENDATIONS

- Given the adrenal changes, consider further testing for a functional tumor (i.e., urine/blood metanephrine levels (to assess for a pheochromocytoma)) +/- low-dose dexamethasone suppression test (to evaluate for Cushing's disease). However, it would be unusual for a patient to have Cushing's disease without an elevated ALP.
- Also consider a urinalysis with a UPC (if proteinuria is present on the urine dipstick).

REFERRING VET

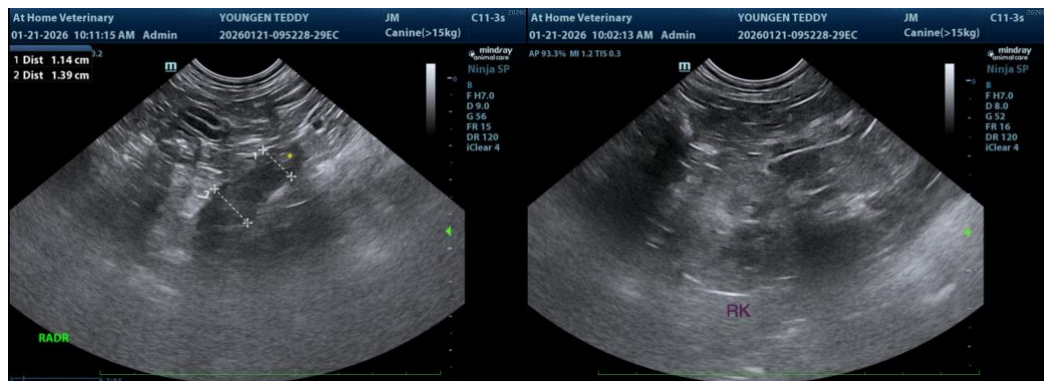
Melinda Persson

INVOICE

22426

DATE

1-22-26





PATIENT

Teddy Youngen

SPECIES

Canine

BREED

Labradoodle

SEX

Neutered Male

AGE

13 years 7 mos

WEIGHT

43.4 lbs

INTERPRETED BY

Andrea Nicastro, DVM,
Diplomate ACVIM
(Small Animal Internal
Medicine)

**IMAGING
PERFORMED BY**

Melinda Persson

HOSPITAL NAME

At Home Veterinary

REFERRING VET

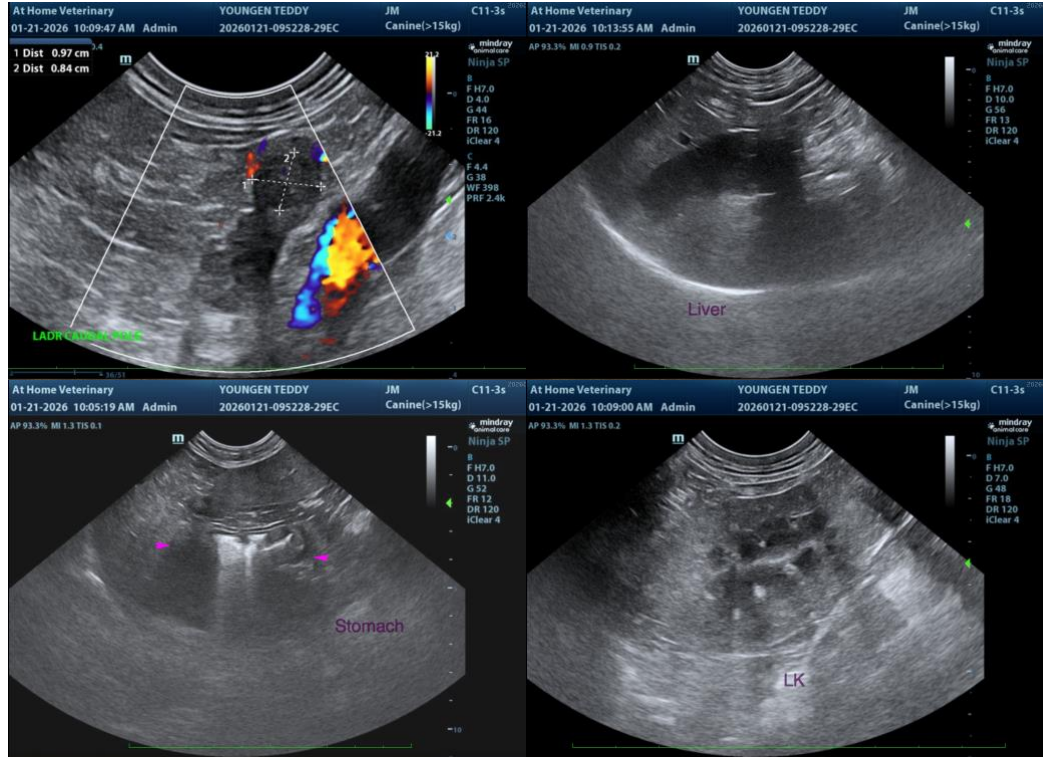
Melinda Persson

INVOICE

22426

DATE

1-22-26



The information and recommendations provided are based on the images presented by the referring veterinarian/sonographer. No evaluation can be communicated regarding pathology that was not visible in the image/video clips provided.

Thank you for this referral. If the clinical or image interpretation does not parallel your findings or if I can be of any further assistance, please contact me.

Andrea Nicastro, MPH, DVM, Diplomate DACVIM (Small Animal Internal Medicine)
info@SonoPath.com