



## PATIENT PRESENTING CLINICAL SIGNS

Dinah Schultz	<ul style="list-style-type: none"> <li>• Several-month weight loss with excellent appetite, new increased lez on labs</li> <li>• P is acting comfortable with normal energy at home</li> </ul>
<b>SPECIES</b>	<ul style="list-style-type: none"> <li>• Long-term suspected inflammatory bowel disease (symptoms: vomiting, diarrhea; us performed 2y ago showed SI changes suspected to be IBD, no parr testing or biopsies performed) managed with daily oral prednisolone; tried cyclosporine and this was insufficient</li> </ul>
Feline	<ul style="list-style-type: none"> <li>• Early hyperthyroidism well managed with twice daily methimazole</li> </ul>
<b>BREED</b>	<ul style="list-style-type: none"> <li>• P also has cerebellar hypoplasia and hypertrophic obstructive cardiomyopathy, stage b1 (managed by cardiologist, no medications indicated)</li> </ul>
DLH	<ul style="list-style-type: none"> <li>• Current medications: prednisolone 4mg PO q24h; methimazole 2mg PO q12h</li> </ul>
<b>SEX</b>	Abnormal PE/Chem/CBC/UA Results: PE: underweight BCS 3/9, 4/6 L parasternal systolic murmur, lungs clear, no abdominal masses palpated, comfortable on abdominal palpation, PLN WNL CBC: mild monocytosis (780), no anemia chem: hypokalemia (3.4), inc ALT 336, inc AST 99, ALP/GGT/bili/ cholesterol all WNL; renal values/protein/BG WNL freeT4: WNL (2.2), total T4: high-WNL (3.5)
Female Spayed	

## AGE

16.5

## WEIGHT

6.6 lbs

## ULTRASONOGRAPHIC EXAMINATION OF THE ABDOMEN

### Urinary System

The urinary bladder wall is normal in thickness. The mucosal surface is smooth. The bladder is distended. A small amount of suspended echogenic debris is observed within the lumen. No cystic calculi are observed. The region of the trigone and visible portion of the proximal urethra are normal.

## INTERPRETED BY

Andrea Nicastro, DVM,  
Diplomate ACVIM  
(Small Animal Internal  
Medicine)

The left kidney is normal in size (3.59 cm in length) with a normal shape, architecture and smooth peripheral margins. There is a normal 1:3 cortex to medulla ratio with minimal loss of corticomedullary distinction. There is no evidence of pyelectasia, nephroliths, infarcts or hydroureter. Renal vasculature is normal.

The right kidney is normal in size (3.42 cm in length) with a normal shape, architecture and smooth peripheral margins. There is a normal 1:3 cortex to medulla ratio with minimal loss of corticomedullary distinction. Trace pyelectasia is present. There is no evidence of nephroliths, infarcts or hydroureter. Renal vasculature is normal.

## IMAGING PERFORMED BY

Karla Schultz

### Adrenal Glands

The region of the left adrenal gland is evaluated. No obvious pathology is observed in this region.

## HOSPITAL NAME

Northshore VH

The right adrenal gland is normal size (0.49 cm width). Normal shape and glandular echogenicity. The phrenicoabdominal vein and surrounding vasculature are normal.

## REFERRING VET

Karla Schultz

### Spleen

The spleen is subjectively enlarged with swollen/irregular peripheral contours. The parenchyma appears homogenous. Splenic vasculature appears normal no obvious evidence of thrombosis.

## INVOICE

22420

### Liver

The liver is subjectively normal in size with normal peripheral contours. The parenchyma is isoechoic relative to the spleen and mildly heterogenous in appearance. Hepatic vasculature and intrahepatic biliary tracts are of normal volume with no evidence of congestion.

## DATE

1-21-26

The gallbladder is of normal contours and contains some dependent echogenic debris. The wall is normal in thickness. A few, polypoid-like lesions are arising from the mucosal surface. No choleliths are observed. The cystic and common bile ducts are normal.



**PATIENT** *Gastrointestinal*

Dinah Schultz

**SPECIES**

Feline

**BREED**

DLH

**SEX**

Female Spayed

**AGE**

16.5

**WEIGHT**

6.6 lbs

**INTERPRETED BY**

Andrea Nicastro, DVM,  
Diplomate ACVIM  
(Small Animal Internal  
Medicine)

**IMAGING PERFORMED BY**

Karla Schultz

**HOSPITAL NAME**

Northshore VH

**REFERRING VET**

Karla Schultz

**INVOICE**

22420

**DATE**

1-21-26

The gastric lumen is not distended. The gastric wall is normal in thickness with a normal layering pattern. The small intestinal wall is to moderately-thickened (up to 0.34 cm). There is disruption in the normal 1:3 muscularis: mucosal ratio. In at least one small intestinal segment, there appears to be a loss of the normal layering pattern. Discreet masses are not identified. The ileoceocolic junction and colonic wall are normal. There is no obvious evidence of an obstructive pattern.

**Pancreas**

The base and limbs of the pancreas are visible with normal curvilinear peripheral contours. The parenchyma is slightly hypoechoic relative to surrounding omental fat and slightly mottled in appearance. The pancreatic duct is visible but not overtly dilated. There is no evidence of peripancreatic inflammation or effusion.

**Lymph Nodes**

A 0.38 x 0.36 cm gastric lymph node is visualized. Several prominent mesenteric lymph nodes are visualized (one measuring 1.5 x 0.7 cm). Surrounding mesentery is mildly hyperechoic.

**Free Abdomen**

There is no obvious evidence of free fluid.

**ULTRASONOGRAPHIC FINDINGS**

**Primary Findings**

- The small intestinal wall changes, particularly in the regions where there appears to be a loss of layering, are concerning for emerging neoplasia (i.e., lymphoma). However, inflammatory bowel disease cannot be excluded.
- The prominent mesenteric lymph nodes could be consistent with lymphoid hyperplasia, lymphadenitis, or emerging neoplasia (i.e., lymphoma).
- The pancreatic changes are most consistent with age-related parenchymal remodeling, potentially secondary to a prior inflammatory episode, early fibrosis or chronic pancreatitis.

**Secondary Findings**

- Trace right pyelectasia. This may be secondary to parenchymal remodeling, pyelonephritis, PU/PD or some combination thereof. Correlation with the patient's clinical history is recommended.
- The diffuse hepatic parenchymal changes could be consistent with hepatic lipidosis, an inflammatory hepatopathy (i.e., bacterial cholangiohepatitis, lymphoplasmacytic hepatitis, feline infectious peritonitis), infiltrative neoplasia (i.e., lymphoma) and/or other hepatopathy.
- The splenic changes could be consistent with lymphoid hyperplasia, extramedullary hematopoiesis, splenitis, antigenic stimulation, or emerging neoplasia.

**INTERPRETATION OF THE FINDINGS & FURTHER RECOMMENDATIONS**

- Regarding the elevated ALT and sonographic hepatic changes, consider hepatic tissue sampling (i.e., aspirates or biopsies) along with aerobic and anaerobic bile cultures.
- Regarding the small intestinal and abdominal lymph node changes, an abdominal exploratory with biopsies may be necessary to get a definitive diagnosis. Ancillary tests could include the following:



**PATIENT**

Dinah Schultz

**SPECIES**

Feline

**BREED**

DLH

**SEX**

Female Spayed

**AGE**

16.5

**WEIGHT**

6.6 lbs

**INTERPRETED BY**

Andrea Nicastro, DVM,  
Diplomate ACVIM  
(Small Animal Internal  
Medicine)

**IMAGING PERFORMED BY**

Karla Schultz

**HOSPITAL NAME**

Northshore VH

**REFERRING VET**

Karla Schultz

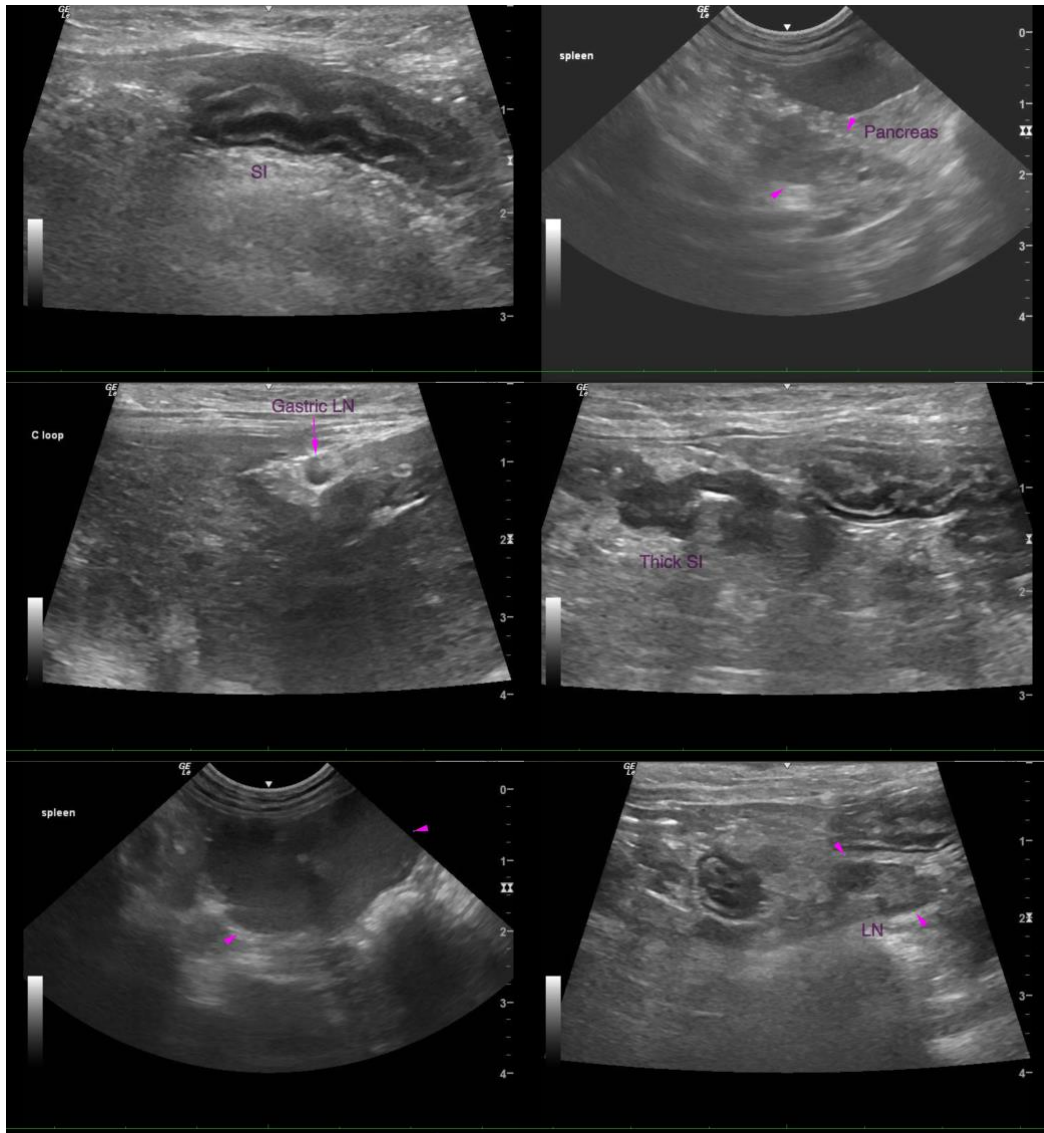
**INVOICE**

22420

**DATE**

1-21-26

1. GI panel including serum cobalamin and folate, TLI and PLI
2. Fine-needle aspiration of the spleen (assuming normal clotting status). A 25-gauge needle should be used.
3. Feline leukemia, FIV and FIP testing, if not already performed





## PATIENT

Dinah Schultz

## SPECIES

Feline

## BREED

DLH

## SEX

Female Spayed

## AGE

16.5

## WEIGHT

6.6 lbs

## INTERPRETED BY

Andrea Nicastro, DVM,  
Diplomate ACVIM  
(Small Animal Internal  
Medicine)

## IMAGING PERFORMED BY

Karla Schultz

## HOSPITAL NAME

Northshore VH

## REFERRING VET

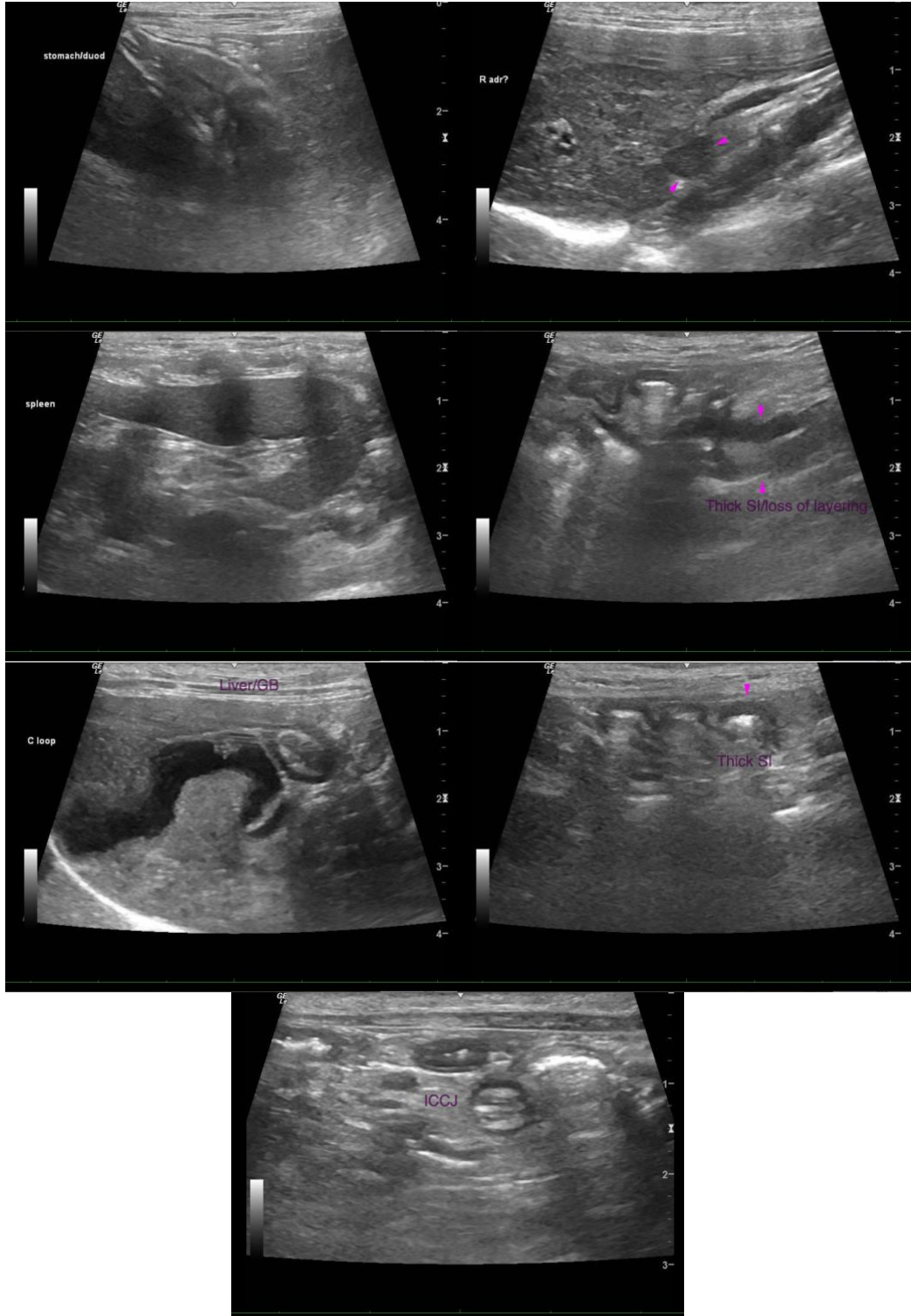
Karla Schultz

## INVOICE

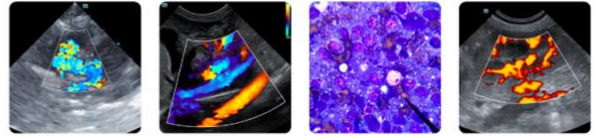
22420

## DATE

1-21-26



The information and recommendations provided are based on the images presented by the referring veterinarian/sonographer. No evaluation can be communicated regarding pathology that was not visible in



**PATIENT** the image/video clips provided.

Dinah Schultz Thank you for this referral. If the clinical or image interpretation does not parallel your findings or if I can be of any further assistance, please contact me.

**SPECIES**

Feline

**Andrea Nicastro, MPH, DVM, Diplomate DACVIM (Small Animal Internal Medicine)**  
[info@SonoPath.com](mailto:info@SonoPath.com)

**BREED**

DLH

**SEX**

Female Spayed

**AGE**

16.5

**WEIGHT**

6.6 lbs

**INTERPRETED BY**

Andrea Nicastro, DVM,  
Diplomate ACVIM  
(Small Animal Internal  
Medicine)

**IMAGING  
PERFORMED BY**

Karla Schultz

**HOSPITAL NAME**

Northshore VH

**REFERRING VET**

Karla Schultz

**INVOICE**

22420

**DATE**

1-21-26