


DATE PRESENTING CLINICAL SIGNS

1/20/26

Patient History: Decreased appetite for 6 months, increased vomiting over past 2 months, vomits almost every day, rapid weight loss. Normal BW 1/7/26.

PATIENT

Grey Cat Wells

Current Medications: None currently.

Labwork Results: Labwork not submitted. Reported as BW WNL 1/7/26. Rads and quick scan today suspicious of cranial abdominal mass.

SPECIES

Feline

Date of Previous IntraPet Ultrasound: No previous.

Sedation: Not required to complete full diagnostic ultrasound but would be required for further imaging.

Stat Report: DVM requested.

Imaging Performed by: Andi Parkinson, BS, RDMS.

BREED

Domestic shorthair

ULTRASONOGRAPHIC EXAMINATION OF THE ABDOMEN
SEX

Female, spayed

Urinary System

The urinary bladder wall is normal in thickness and the mucosal surface is smooth. The bladder is moderately distended. Luminal contents are anechoic. No cystic calculi are observed. The region of the trigone and the proximal urethra, visible to a depth of 2 cm, are normal.

AGE

11/15/2018

The left kidney is normal in size (3.17 cm in length) with a normal shape, architecture and smooth peripheral margins. There is a normal 1:3 cortex to medulla ratio with normal corticomedullary distinction. There is no evidence of pyelectasia, nephroliths, infarcts or hydroureter.

WEIGHT

6.96 lbs.

The right kidney is normal in size (4.17 cm in length) with a normal shape, architecture and smooth peripheral margins. There is a normal 1:3 cortex to medulla ratio with minimal to mild loss of corticomedullary distinction. There is no evidence of pyelectasia, nephroliths, infarcts or hydroureter.

INTERPRETED BY
Adrenal Glands

The left adrenal gland is normal size (0.36 cm width). Normal shape and glandular echogenicity. The phrenicoabdominal vein and surrounding vasculature are normal.

The region of the right adrenal gland is evaluated. No obvious pathology is observed in this region.

HOSPITAL NAME

Northwind AH

Spleen

The spleen is normal in size (0.60 cm in width at the level of the hilus) with a normal capsular contour. There is appropriate echogenicity and echotexture. No focal lesions are observed. Splenic vasculature is normal.

REFERRING VET

Dr. Mullenex

Liver

The liver is subjectively normal in size with normal contours and structure. There is appropriate echogenicity and echotexture. No overt structural evidence of inflammatory, infiltrative, or regenerative pathology is evident. Vascular and biliary tracts are of normal volume with no evidence of congestion. The portal vein to caudal vena cava ratio is approximately 1:1.

INVOICE

13403

The gall bladder lumen is moderately distended. The wall is thin and smooth. Luminal contents are anechoic. The distal common bile duct appears normal. The duodenal papilla is normal in size (0.21 cm in width).

Gastrointestinal

The stomach and intestine are free of stasis and exhibit normal peristaltic activity. The gastric lumen is not distended. The gastric wall and pylorus are normal in thickness with a normal layering pattern. The pyloric

outflow tract is patent. The small intestinal lumen is not dilated. The small intestinal wall thickness is normal. There is disruption in the normal 1:3 muscularis: mucosal ratio in most segments. Discreet masses are not identified. The colonic wall is normal. No obvious obstructive disease is noted.

Pancreas

See *Other*.

Lymph nodes

The abdominal lymph nodes are normal/not visible.

Free Abdomen

There is no obvious evidence of free fluid.

Other

In the cranial abdomen, a >6 cm irregular hypoechoic, lobulated, vascular mass is observed in the cranial to mid-abdomen. Surrounding mesentery is hyperechoic.

ULTRASONOGRAPHIC FINDINGS

Primary Findings:

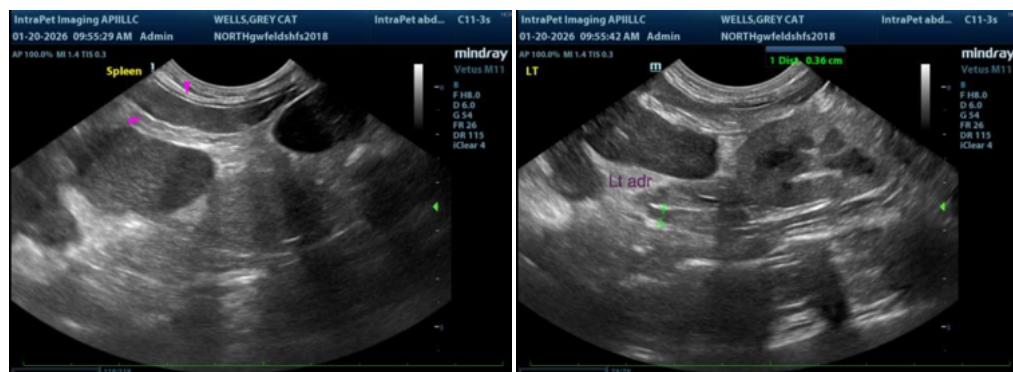
- Cranial to mid-abdominal mass, suspected to be of pancreatic origin, although other origins (i.e., liver, mesentery, lymph node, other) cannot be excluded. Adjacent peritonitis is present.

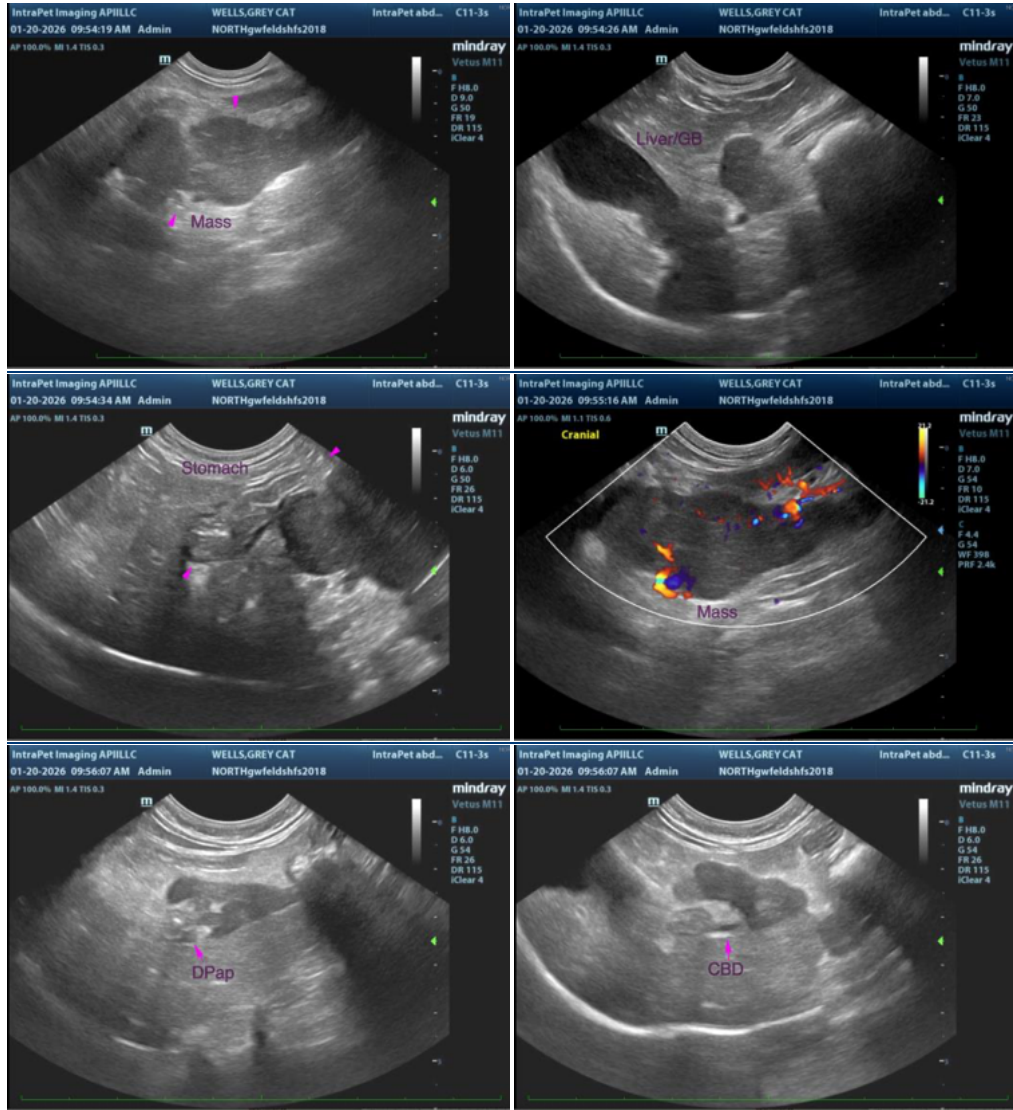
Secondary Findings:

- Mild bilateral nonspecific, age-related renal changes
- The small intestinal wall changes could be consistent with inflammatory bowel disease, emerging lymphoma or may be a normal variant for this older feline patient.

INTERPRETATION OF THE FINDINGS & FURTHER RECOMMENDATIONS

1. Three-view thoracic radiographs are recommended to assess for pulmonary metastases.
2. Consider fine needle aspiration of the cranial to mid-abdominal mass (assuming normal clotting status). A 25-gauge needle should be used. Depending on results, consultation with a board certified oncologist may be indicated. If tissue sampling is not pursued, palliative care is recommended.
3. A GI panel including serum cobalamin, folate, TLI and PLI may also be beneficial.





The information and recommendations provided are based on the images presented by the referring veterinarian/sonographer. No evaluation can be communicated regarding pathology that was not visible in the image/video clips provided.

Thank you for this referral. If the clinical or image interpretation does not parallel your findings or if I can be of any further assistance please contact me.

Andrea Nicastro, MPH, DVM, Diplomate DACVIM (Small Animal Internal Medicine) info@SonoPath.com