



## PATIENT

Louisa Rose Weitz

## PRESENTING CLINICAL SIGNS

Clinical Exam Findings: Spoke to owner and told her that LES have gone up slightly higher. Would recommend AUS or starting Denamarin and rechecking. Owner would like to schedule AUS.

## SPECIES

Canine

Perivulvar Dermatitis. Hematuria. Recessed Vulva. Underbite. Dental Calculi. Pododermatitis. Suspect. Atopy. Elevated LES. Hx of UTI

## BREED

Fr Bulldog

Abnormal lab-work values

1/16/2023 NSAID panel: CREA 0.8 mg/dL. BUN 16 mg/dL  
BUN/CREA 20. ALT 242 U/L. AST 56 U/L. ALKP 309 U/L

11/10/2022. ALT 145 U/L. AST 24 U/L. ALP 212 U/L

## SEX

Spayed Female

Current Medications: Enrofloxacin 68 mg Tablets #21 Give 1 tablet by mouth once daily prescribed 1/16/2023

## ULTRASONOGRAPHIC EXAMINATION OF THE ABDOMEN

### AGE

10.30.2013

#### Urinary System

The urinary bladder wall is normal in thickness and the mucosal surface is smooth. The bladder lumen is moderately distended with anechoic urine. No masses, inflammatory changes or calculi are observed. Ureteral papillae and visualized portion of the proximal urethra, visible to a depth of 2 cm, are normal.

### WEIGHT

29 lbs

The left kidney is normal in size (4.97 cm in length) with a normal shape, architecture and smooth peripheral margins. There is a normal 1:3 cortex to medulla ratio with mild loss of corticomedullary distinction. There is no evidence of pyelectasia, nephroliths, infarcts or hydronephrosis. Renal vasculature is normal.

## INTERPRETED BY

Andrea Nicastro, DVM,  
Diplomate ACVIM (*Small  
Animal Internal Medicine*)

The right kidney is normal in size (5.46 cm in length) with a normal shape, architecture and smooth peripheral margins. There is a normal 1:3 cortex to medulla ratio with mild loss of corticomedullary distinction. There is no evidence of pyelectasia, nephroliths, infarcts or hydronephrosis. Renal vasculature is normal.

## IMAGING PERFORMED BY

Andrea Nicastro, DVM,  
Diplomate ACVIM (*Small  
Animal Internal Medicine*)

#### Adrenal Glands

The left adrenal gland is mildly enlarged (4.80 cm at cranial pole) (0.70 cm at caudal pole) with a normal shape and homogenous parenchyma. The glandular echogenicity and detail are unremarkable. Capsule, cortex, and medullary definition are normal. The phrenicoabdominal vein and surrounding vasculature are normal.

## HOSPITAL NAME

Salt Marsh AH

The right adrenal gland is mildly enlarged (1.15 cm at cranial pole) (0.86 cm at caudal pole) with a slightly irregular shape. The parenchyma is subtly homogenous with some loss of glandular detail. The phrenicoabdominal vein and surrounding vasculature are normal.

## REFERRING VET

Dr. Christie Wiles

#### Spleen

The spleen is normal in size (1.37 cm in width at the level of the hilus) with a normal capsular contour. The parenchyma is subtly mottled in appearance. A 1.59 x 1.04 cm isoechoic to slightly heterogenous nodule is observed at the lateral aspect. The lesion does not appear to cause capsular expansion.

## INVOICE

12072

## DATE

1.20.23

### **Liver**

The liver is prominent in size with slightly swollen peripheral contours. The parenchyma is isoechoic relative to the spleen with a few small, ill-defined hypoechoic nodules/areas on the right side. Hepatic vasculature and intrahepatic biliary tracts are of normal volume with no evidence of congestion.

The gall bladder is distended. The wall is normal in thickness. A moderate amount of echogenic debris/sludge is observed within the lumen (most of which is gravity dependent and some of which is suspended). Luminal contents are anechoic. The cystic and common bile ducts are normal/not seen.

### **Gastrointestinal**

The stomach and intestine are free of stasis and exhibit normal peristaltic activity. The gastric lumen is not distended. The gastric wall and pylorus are normal in thickness with a normal layering pattern. The pyloric outflow tract is patent. The small intestinal lumen is not dilated. The small intestinal wall thickness is normal with a normal layering pattern and appropriate mural detail. Discreet masses are not identified. The colonic wall is normal. There is no evidence of an obstructive pattern.

### **Pancreas**

The right limb of the pancreas is visible with normal curvilinear peripheral contours. The parenchyma is largely slightly hyperechoic relative to surrounding omental fat and slightly mottled in appearance. The pancreatic duct is visible but not overtly dilated. There is no evidence of peripancreatic inflammation or effusion.

### **Free Abdomen**

The peritoneal cavity is normal. There is no evidence of inflammation or effusion. The abdominal lymph nodes are normal/not visible.

### **Other**

A brief echocardiogram reveals no evidence of pericardial effusion or obvious right atrial/auricular mass.

## **ULTRASONOGRAPHIC FINDINGS**

### **Primary Findings**

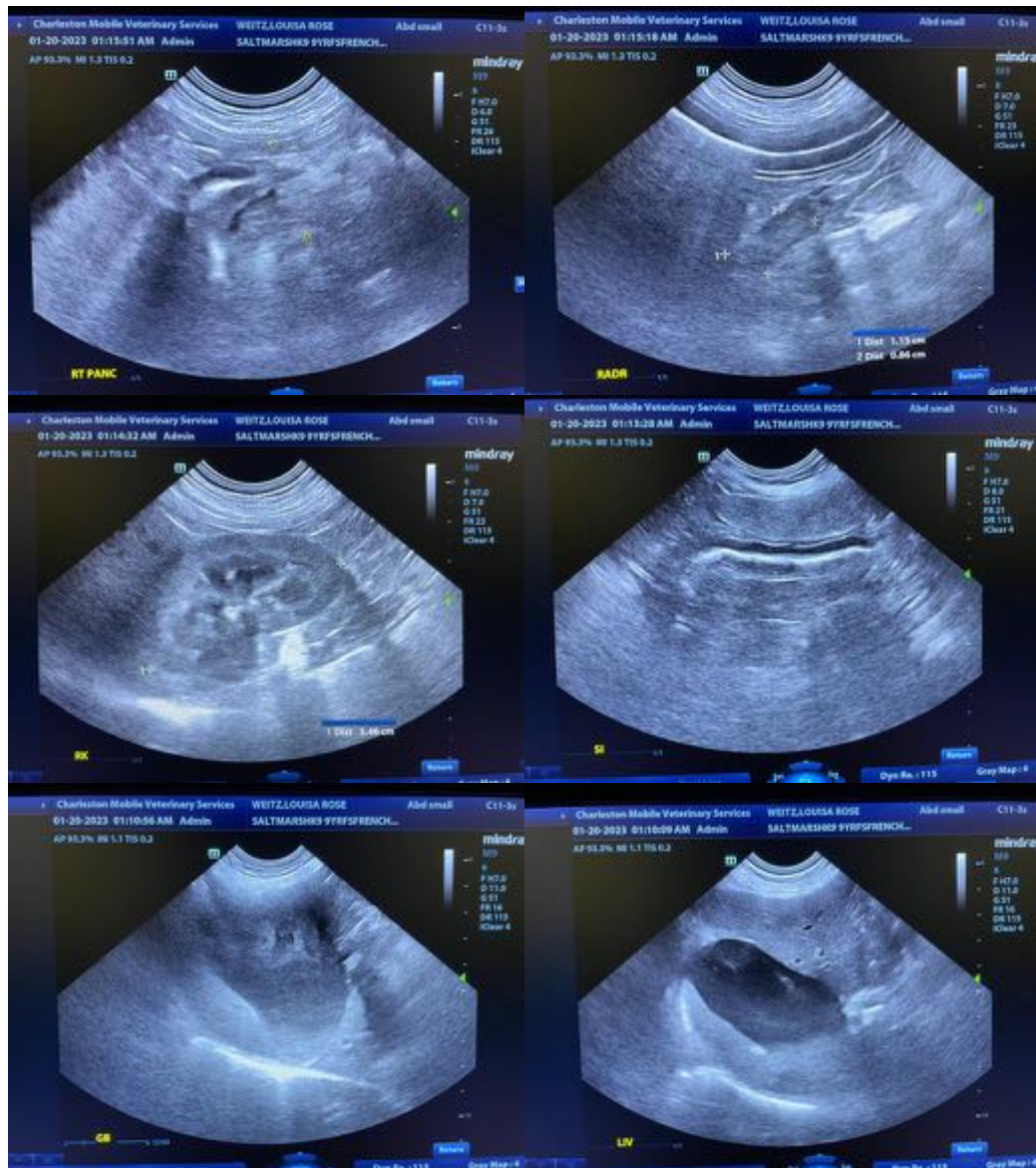
- Nonspecific diffuse hepatopathy. Differentials include inflammatory disease (i.e., chronic hepatitis, bacterial cholangiohepatitis), hepatotoxicosis (i.e., copper), Leptospirosis (less likely given the chronicity of the liver enzyme elevations), other hepatopathy, +/- benign age-related change (i.e., vacuolar hepatopathy, regenerative nodular hyperplasia).
- Gall bladder debris/sludge – non-mucocele
- The mild bilateral adrenomegaly is most consistent with hyperplastic change.
- The splenic nodule could be consistent with an emerging tumor or a benign focus (i.e., lymphoid hyperplasia, or similar). Differentials for the diffuse splenic parenchymal changes are the same as for the nodule.

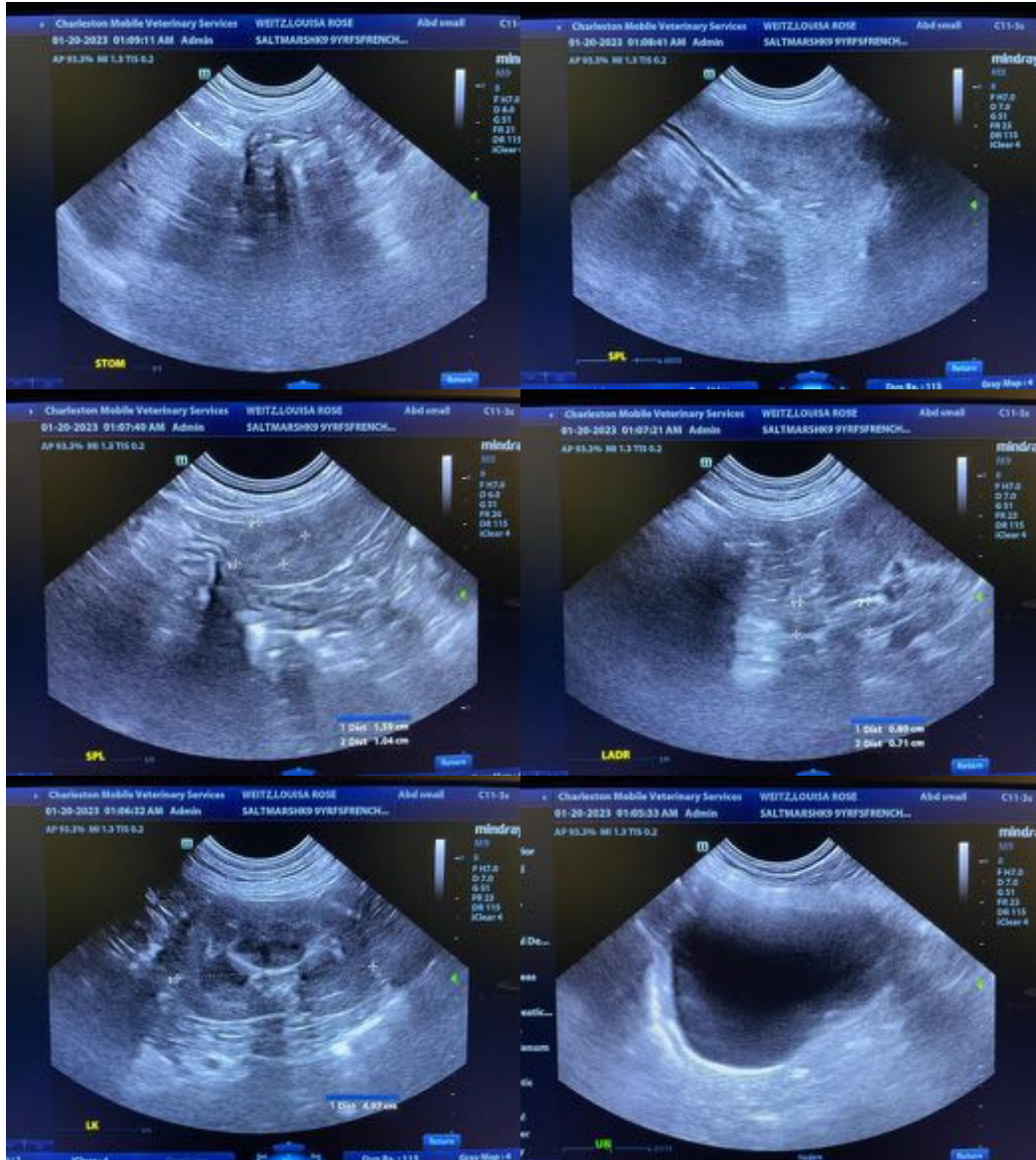
### **Secondary Findings**

- The pancreatic changes are most consistent with age-related parenchymal remodeling, potentially secondary to a prior inflammatory episode, early fibrosis or chronic pancreatitis.
- Mild bilateral age-related renal changes

## INTERPRETATION OF THE FINDINGS & FURTHER RECOMMENDATIONS

- Consider fine-needle aspirates of the splenic nodule and liver (if clotting status is appropriate). Twenty-five gauge-needles should be used. If the cytology results are inconclusive, surgical biopsies of the liver and splenic nodule can be considered. If biopsies are pursued, aerobic and anaerobic bile cultures are also recommended, along with hepatic copper quantitation. If hepatic tissue sampling is not pursued at this time, consider initiation of a hepatic antioxidant (i.e., Denamarin), a recheck of liver values and an abdominal ultrasound in 4 weeks.
- Thoracic radiographs can also be considered to assess for pulmonary metastatic disease (given the splenic nodule).





The information and recommendations provided are based on the images presented by the referring veterinarian/sonographer. No evaluation can be communicated regarding pathology that was not visible in the image/video clips provided.

Thank you for this referral. If the clinical or image interpretation does not parallel your findings or if I can be of any further assistance, please contact me.

**Andrea Nicastro, MPH, DVM, Diplomate DACVIM (Small Animal Internal Medicine)**  
[info@SonoPath.com](mailto:info@SonoPath.com)