



**PATIENT PRESENTING CLINICAL SIGNS**

Piper Whaley History: Pet has an elevated ALP 1524. Pet is otherwise healthy.

**SPECIES ULTRASONOGRAPHIC EXAMINATION OF THE ABDOMEN**

**Canine Urinary System**

The urinary bladder wall is normal in thickness and the mucosal surface is smooth. The bladder lumen is moderately distended with mostly anechoic urine. No masses, inflammatory changes or calculi are observed. The region of the trigone and visible portion of the proximal urethra are normal.

**BREED**

NP

The left kidney is normal in size (6.39 cm in length) with a normal shape, architecture and smooth peripheral margins. The cortex is isoechoic relative to the spleen. There is a normal 1:3 cortex to medulla ratio with minimal to mild loss of corticomedullary distinction. There is no evidence of pyelectasia, nephroliths, infarcts or hydroureter. Renal vasculature is normal.

**SEX**

Spayed Female

The right kidney is normal in size (6.64 cm in length) with a normal shape, architecture and smooth peripheral margins. The cortex is isoechoic relative to the spleen. There is a normal 1:3 cortex to medulla ratio with minimal to mild loss of corticomedullary distinction. There is no evidence of pyelectasia, nephroliths, infarcts or hydroureter. Renal vasculature is normal.

**AGE**

10 years

**Adrenal Glands**

The left adrenal gland is borderline enlarged (0.67 cm at cranial pole) (0.85 cm at caudal pole) with a normal shape and homogenous parenchyma. The glandular echogenicity and detail are unremarkable. Capsule, cortex, and medullary definition are normal. The phrenicoabdominal vein and surrounding vasculature are normal.

**WEIGHT**

70.6 lbs

The caudal pole of the right adrenal gland is visualized and is normal in size (0.76 cm in width) with normal shape, glandular echogenicity and detail. Surrounding vasculature appears normal.

**INTERPRETED BY**

Andrea Nicastro, DVM,  
Diplomate ACVIM (*Small  
Animal Internal Medicine*)

**Spleen**

The spleen is normal in size (2.77 cm in width at the level of the hilus) with a normal capsular contour. The parenchyma is subtly mottled in appearance. A 1.13 cm ill-defined hypoechoic nodule/area is observed approximately mid-spleen. Splenic vasculature is normal.

**IMAGING PERFORMED BY**

Dr. Sheldon

**Liver**

The liver is normal to slightly prominent in size with normal curvilinear peripheral contours. The parenchyma is hyperechoic relative to the spleen and diffusely homogeneous in appearance. No distinct focal lesions are observed. Vascular and biliary tracts are of normal volume with no evidence of congestion.

**HOSPITAL NAME**

Advanced PC of  
Oakland

The gall bladder lumen is moderately distended. The wall is thin and smooth. A moderate amount of aggregated, echogenic to mineralized, gravity dependent debris/sludge is observed within the lumen. The cystic and common bile ducts are normal/not seen.

**REFERRING VET**

Dr. Sheldon

**Gastrointestinal**

The lumen is not distended. The gastric wall is normal in thickness with a normal layering pattern. The small intestinal lumen is not dilated. The small intestinal wall thickness is normal with a normal layering pattern and appropriate mural detail. Discreet masses are not identified. The colonic wall is normal. There is no evidence of an obstructive pattern.

**INVOICE**

12069

**DATE**

1.19.23

### **Pancreas**

The region of the pancreas is isoechoic relative to surrounding omental fat. No obvious parenchymal abnormalities are observed. There is no evidence of regional inflammation or effusion.

### **Free Abdomen**

The peritoneal cavity is normal. There is no evidence of inflammation or effusion. The abdominal lymph nodes are normal/not visible.

## **ULTRASONOGRAPHIC FINDINGS**

### **Primary Findings**

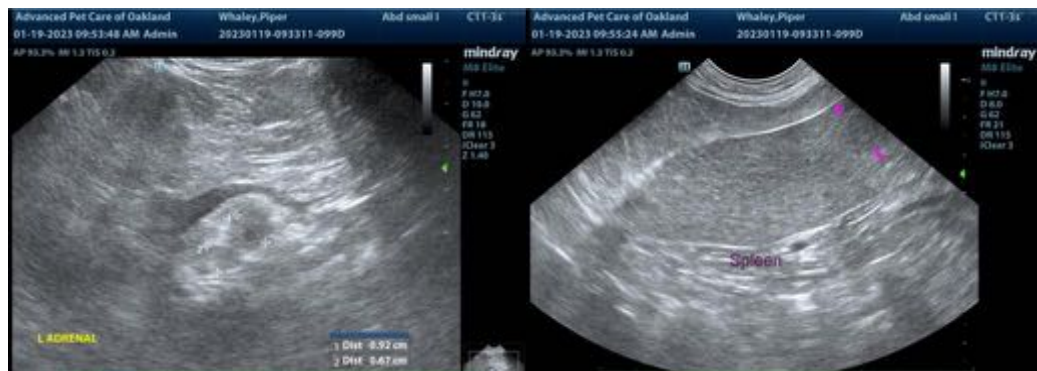- The hepatic parenchyma changes are most consistent with a benign vacuolar hepatopathy (i.e., idiopathic, endocrine). Infiltrative neoplasia is possible but considered less likely given the sonographic appearance of the liver. In light of the normal ALT, inflammatory disease is also considered less likely.
- Gall bladder sludge, non-mucocele

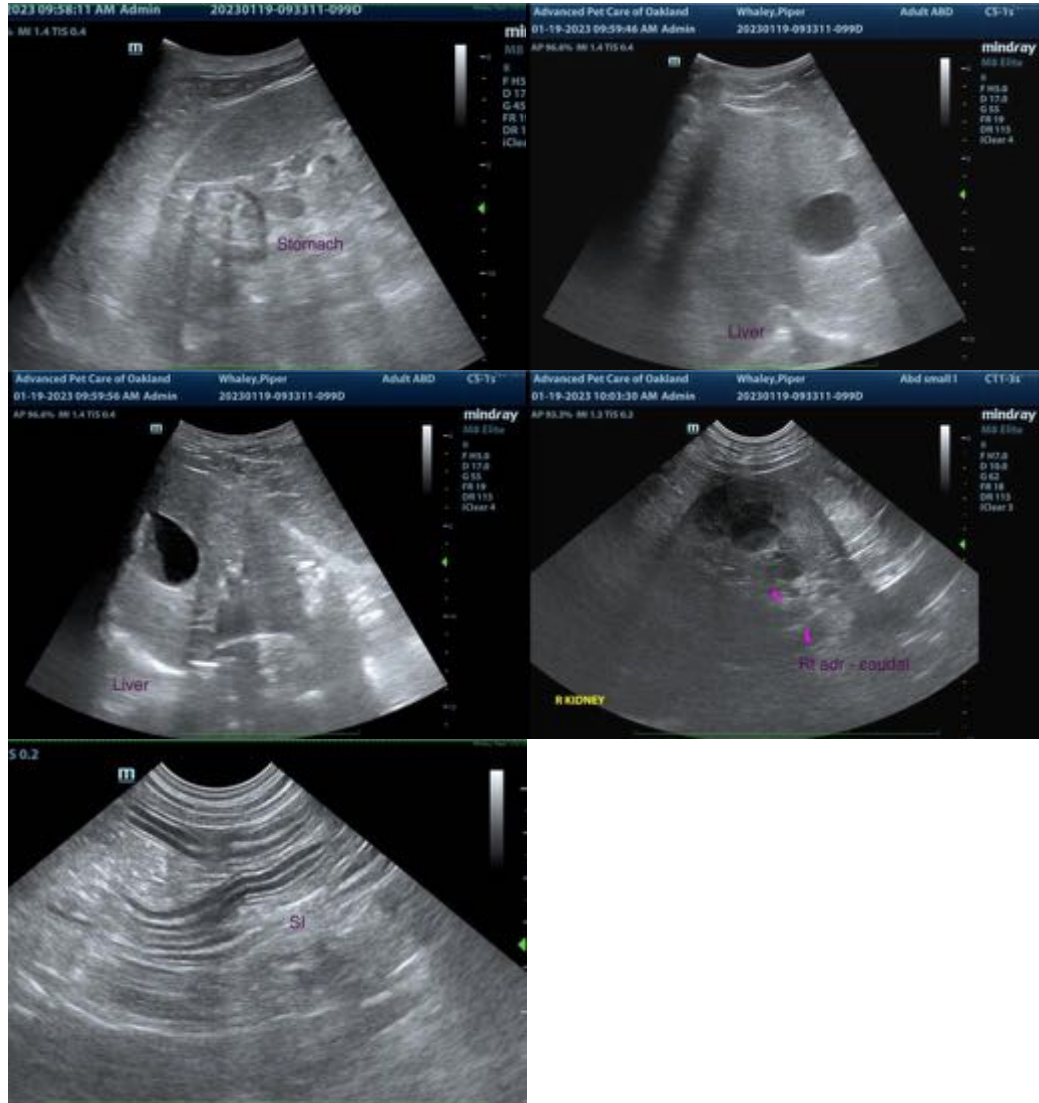
### **Secondary Findings**

- Minor bilateral age-related renal changes
- The splenic parenchymal changes, including the ill-defined nodule, trend toward the benign (i.e., lymphoid hyperplasia, extramedullary hematopoiesis or similar) with a lower possibility of emerging neoplasia (i.e., round cell tumor).
- Borderline left adrenomegaly

## **INTERPRETATION OF THE FINDINGS & FURTHER RECOMMENDATIONS**

- Serial monitoring (i.e., every 3-4 months) of the patient's liver values is recommended. If values continue to increase, a repeat abdomen ultrasound +/- a more advanced hepatic work-up (i.e., tissue sampling) may be warranted.
- Consider testing for hyperadrenocorticism with a low-dose dexamethasone suppression test or ACTH stimulation test if clinical signs (i.e., PU/PD) develop.





The information and recommendations provided are based on the images presented by the referring veterinarian/sonographer. No evaluation can be communicated regarding pathology that was not visible in the image/video clips provided.

Thank you for this referral. If the clinical or image interpretation does not parallel your findings or if I can be of any further assistance, please contact me.

**Andrea Nicastro, MPH, DVM, Diplomate DACVIM (Small Animal Internal Medicine)**  
[info@SonoPath.com](mailto:info@SonoPath.com)