



PATIENT

Teddy Bendsond

SPECIES

Canine

BREED

JRT

SEX

Neutered Male

AGE

14 Years

WEIGHT

12.7 kg

INTERPRETED BY

Andrea Nicastro,
DVM, Diplomate
ACVIM (Small Animal
Internal Medicine)

IMAGING PERFORMED BY

Kelly Reshny, RVT

HOSPITAL NAME

Wellington AH

REFERRING VET

Dr. Grodecki

INVOICE

13493

DATE

1/19/22

PRESENTING CLINICAL SIGNS

History: PUPD, elevated ALT, ALP Additional History: Blood work from December 31st, 2021: CBC normal, ALP 1172, ALT 255, Urine Spec Gravity 1.031, 2+ proteinuria, inactive sediment
Abnormal PE/Chem/CBC/UA Results: please see attached labs

ULTRASONOGRAPHIC EXAMINATION OF THE ABDOMEN

Urinary System

The urinary bladder is mildly distended with anechoic urine. The wall in the region of the apex is thickened (up to 0.55 cm) and irregular. No cystic calculi are observed. The region of the trigone and the visible portion of the proximal urethra are normal.

The prostate is normal in size (1.15 cm in width) and shape. Parenchyma is homogenous. The prostatic urethra appears normal without evidence of dilation or obstruction.

The left kidney presented normal size (4.79 cm in length); normal shape and architecture with smooth peripheral margins. There is a normal 1:3 cortex to medulla ratio with moderate loss of corticomedullary distinction. There is no evidence of pyelectasia, nephroliths, infarcts or hydronephrosis. Renal vasculature is normal.

The right kidney presented normal size (5.31 cm in length); normal shape and architecture with smooth peripheral margins. There is a normal 1:3 cortex to medulla ratio with moderate loss of corticomedullary distinction. A 0.53 cm cortical cyst is observed at the caudal aspect. There is no evidence of pyelectasia, nephroliths, infarcts or hydronephrosis. Renal vasculature is normal.

Adrenal Glands

The left adrenal gland is enlarged (0.59 cm at cranial pole) (0.82 cm at caudal pole) (2.12 cm in length); normal shape; homogenous parenchyma. The glandular echogenicity and detail are unremarkable. Capsule, cortex, and medullary definition are normal. The phrenicoabdominal vein and surrounding vasculature are normal.

The right adrenal gland is mildly enlarged (1.49 cm at cranial pole) (0.71 cm at caudal pole) (2.41 cm in length); normal shape; homogenous parenchyma. The glandular echogenicity and detail are unremarkable. Capsule, cortex, and medullary definition are normal. The phrenicoabdominal vein and surrounding vasculature are normal.

Spleen

The spleen is normal in size (1.54 cm in width at the level of the hilus) with a normal capsular contour. There is appropriate echogenicity and echotexture. No focal lesions are observed. Splenic vasculature is normal.

Liver

The liver is subjectively prominent in size with slightly swollen peripheral contours. The parenchyma is hypoechoic relative to the spleen and diffusely mottled in appearance. A 2.92 cm irregular



PATIENT

Teddy Bendsond

hyperechoic nodule/mass is observed on the right side. Hepatic vasculature and intrahepatic biliary tracts are of normal volume with no evidence of congestion.

SPECIES

Canine

The gall bladder is moderately distended. The wall is normal in thickness. A few small polypoid-like lesions are arising from the luminal surface. Luminal contents are mostly anechoic. The cystic and common bile ducts are normal/not seen.

Gastrointestinal

BREED

JRT

The stomach and intestine are free of stasis and exhibit normal peristaltic activity. The gastric lumen is not distended. The gastric wall and pylorus are normal in thickness with a normal layering pattern. The small intestinal lumen is not dilated. The small intestinal wall thickness is normal with a normal layering pattern and appropriate mural detail. Discreet masses are not identified. The colonic wall is normal. No obstructive or overt infiltrative disease is noted.

SEX

Neutered Male

Pancreas

AGE

14 Years

The right limb of the pancreas is visible with normal curvilinear peripheral contours. The parenchyma is largely isoechoic relative to surrounding omental fat and slightly mottled in appearance. The pancreatic duct is visible but not overtly dilated (0.21 cm in diameter). There is no evidence of peripancreatic inflammation or effusion.

WEIGHT

12.7 kg

Free Abdomen

The peritoneal cavity is normal. There is no evidence of inflammation or effusion. The abdominal lymph nodes are normal/not visible.

INTERPRETED BY

Andrea Nicastro,
DVM, Diplomate
ACVIM (Small Animal
Internal Medicine)

ULTRASONOGRAPHIC FINDINGS

Primary Findings

- Mild bilateral adrenomegaly
- The right hepatic nodule/mass trends toward the benign (i.e., regenerative nodule). However, a neoplastic process (i.e., adenoma, adenocarcinoma) cannot be completely excluded. The diffuse hepatic parenchymal changes are nonspecific and could be secondary to a benign age-related process (i.e., vacuolar hepatopathy, regenerative nodular hyperplasia, age-related remodeling). Inflammatory disease is considered less likely given the liver enzyme pattern.
- The urinary bladder wall changes could be consistent with cystitis or may be artifactual due to lack of full repletion. Correlation with clinical findings is recommended.

IMAGING PERFORMED BY

Kelly Reshny, RVT

HOSPITAL NAME

Wellington AH

Secondary Findings

- Bilateral nonspecific chronic nephropathy
- Age-related pancreatic remodeling +/- fibrosis

INVOICE

13493

INTERPRETATION OF THE FINDINGS & FURTHER RECOMMENDATIONS

- Although the sonographic changes and liver enzyme pattern are consistent with pituitary-dependent Cushing's disease, the lack of isosthenuria suggests that the PU/PD reported in

DATE

1/19/22



PATIENT

Teddy Bendsond

SPECIES

Canine

BREED

JRT

SEX

Neutered Male

AGE

14 Years

WEIGHT

12.7 kg

INTERPRETED BY

Andrea Nicastro,
DVM, Diplomate
ACVIM (Small Animal
Internal Medicine)

**IMAGING
PERFORMED BY**

Kelly Reshny, RVT

HOSPITAL NAME

Wellington AH

REFERRING VET

Dr. Grodecki

INVOICE

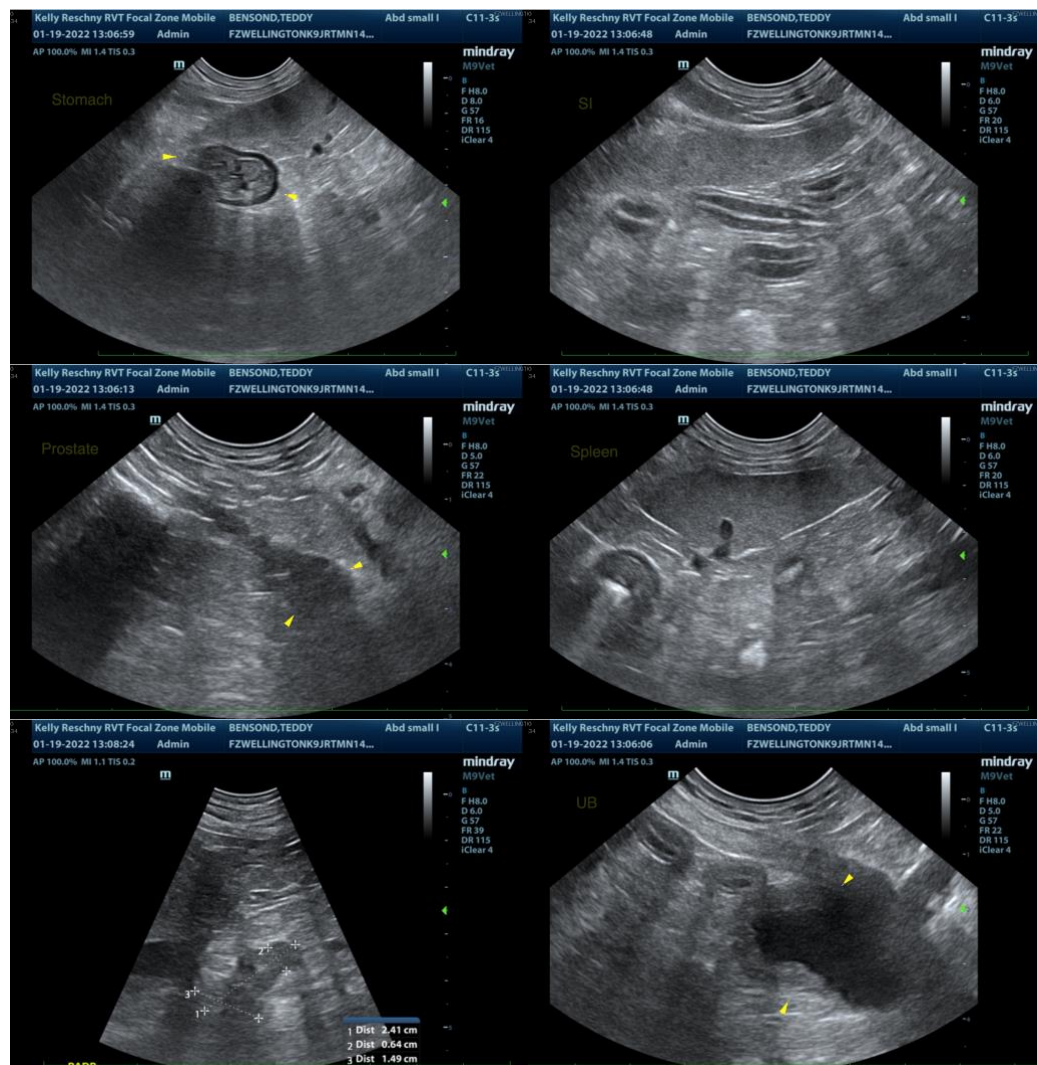
13493

DATE

1/19/22

the history may not be persistent. Further testing for Cushing's disease (i.e., low-dose Dexamethasone suppression test or ACTH stimulation test) can be considered. However, if confirmed, treatment may not be warranted at this time if the patient is not overtly clinical for the disease. If Cushing's disease is confirmed, a baseline blood pressure measurement is recommended to assess for systemic hypertension.

- Regarding the urinary bladder wall changes, consider a urine culture and sensitivity to assess for an occult urinary tract infection.
- Given the proteinuria, a UPC should also be considered.
- Regarding the hyperechoic hepatic nodule/mass, a fine needle aspirate can be considered, if the lesion is accessible. Alternatively, a recheck ultrasound in 4-6 weeks can be considered to assess for progression. Surgical biopsy may be warranted to get a definitive diagnosis.





PATIENT

Teddy Bendsond

SPECIES

Canine

BREED

JRT

SEX

Neutered Male

AGE

14 Years

WEIGHT

12.7 kg

INTERPRETED BY

Andrea Nicastro,
DVM, Diplomate
ACVIM (Small Animal
Internal Medicine)

**IMAGING
PERFORMED BY**

Kelly Reshny, RVT

HOSPITAL NAME

Wellington AH

REFERRING VET

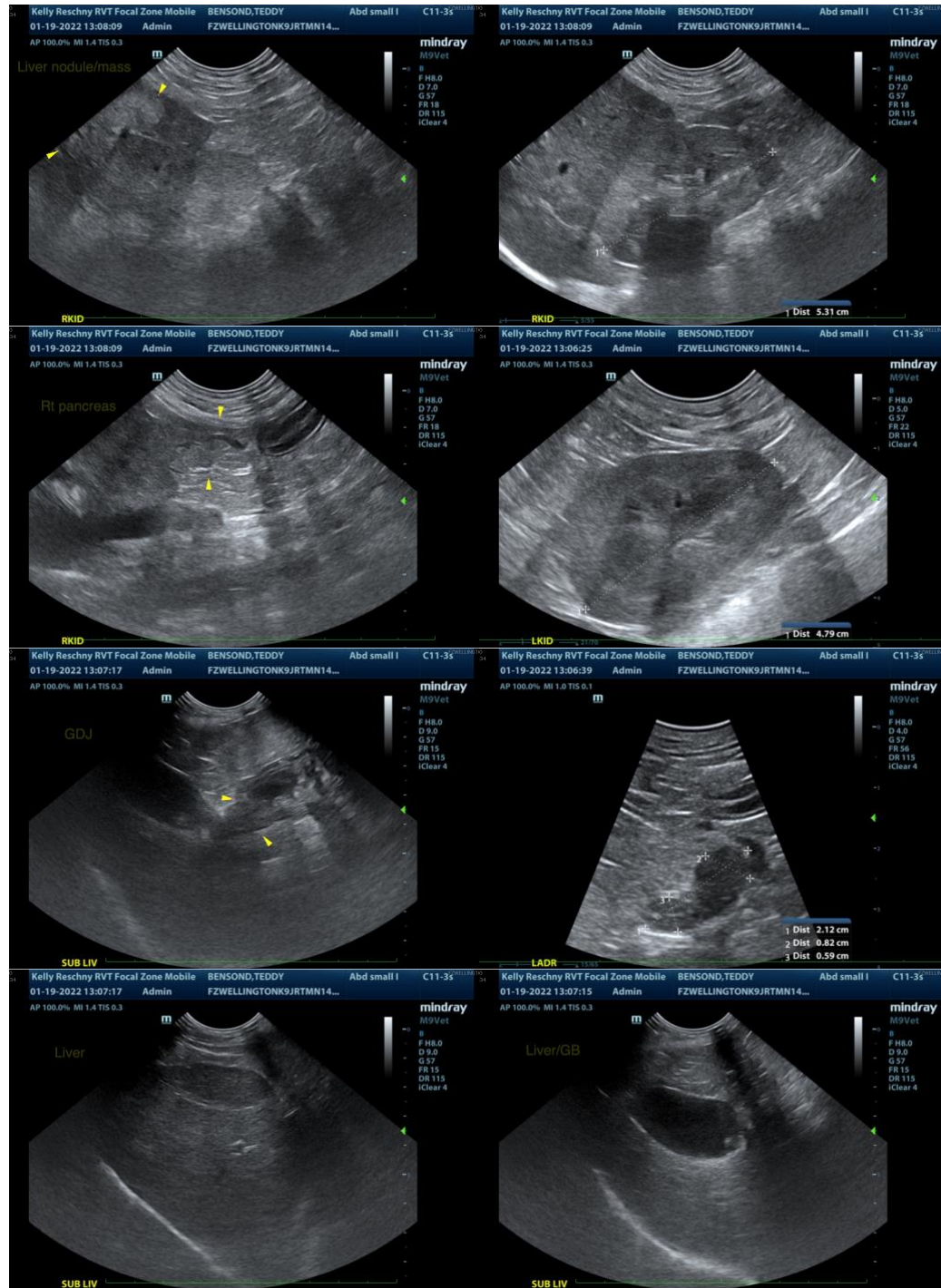
Dr. Grodecki

INVOICE

13493

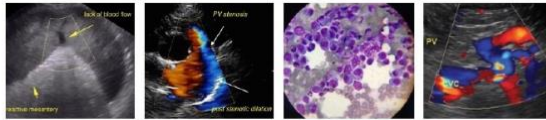
DATE

1/19/22



The information and recommendations provided are based on the images presented by the referring veterinarian. No evaluation can be communicated regarding pathology that was not visible in the image/video clips provided.

Thank you for this referral. If the clinical or image interpretation does not parallel your findings or if I can be of any further assistance please contact me.



PATIENT

Teddy Bendsond

Andrea Nicastro, DVM, Diplomate ACVIM (*Small Animal Internal Medicine*)

andrea_nicastro2@hotmail.com

SPECIES

Canine

BREED

JRT

SEX

Neutered Male

AGE

14 Years

WEIGHT

12.7 kg

INTERPRETED BY

Andrea Nicastro,
DVM, Diplomate
ACVIM (*Small Animal
Internal Medicine*)

**IMAGING
PERFORMED BY**

Kelly Reshny, RVT

HOSPITAL NAME

Wellington AH

REFERRING VET

Dr. Grodecki

INVOICE

13493

DATE

1/19/22