



PATIENT

Pebbles Rodriguez

SPECIES

Canine

BREED

Shih Tzu

SEX

Female, intact

AGE

13 Yrs.

WEIGHT

8.9 lbs.

INTERPRETED BY

Andrea Nicastro, DVM,
Diplomate ACVIM
(Small Animal Internal
Medicine)

**IMAGING
PERFORMED BY**

Dr. Ferrer

HOSPITAL NAME

Paseos VC

REFERRING VET

Dr. Davila

INVOICE

12878

DATE
1/18/22

PRESENTING CLINICAL SIGNS

History: Presented as a referral for an abdominal ultrasound for evaluation of elevated liver enzymes (ALP) and abdominal pain. Patient presented originally to another veterinarian with a complain of hematuria. At that clinic patient was treated with enrofloxacin, but no improvement was seen. Patient returned again to that clinic for a second time and a Cerenia inj SQ was given since that visit patient worsen. Pt is currently inappetant, vomiting every day and has feces that are mucousy. Medications: Famotidine injection, Cerenia injection, metronidazole injection and IV fluids.
Abnormal PE/Chem/CBC/UA Results: Bloodwork: HCT: 32.9% (37-61) EOS: 0.03 (0.06-1.23) PLT: 683 (148-484) PCT: 0.70% (0.14-0.46%) CHEM Glucose: on 1/11/22: 114 on 1/14/22: 69 (70-143) ALP > 2000. (23-212) ALT on 1/11/22: 145 (10-125) on 1/14/22: 116 GGT: 19 (0-11) Tbili on 1/11/22: 1.2 (0-0.9) on 1/14/22: 0.5

ULTRASONOGRAPHIC EXAMINATION OF THE ABDOMEN

Urinary System

The urinary bladder is mildly distended with anechoic urine. The wall is slightly thickened (up to 0.26 cm) with a mildly irregular mucosal surface. No cystic calculi are observed. The region of the trigone and the visible portion of the proximal urethra are normal.

The left kidney is normal size (3.87 cm in length) with a slightly irregular shape. There is a normal 1:3 cortex to medulla ratio with minimal to mild loss of corticomedullary distinction. A hyperechoic medullary band is observed adjacent to the corticomedullary junction. Trace pyelectasia is present (0.13 cm in the transverse plane). There is no evidence of nephroliths or hydronephrosis.

The right kidney is normal size (4.04 cm in length) with a slightly irregular shape. There is a normal 1:3 cortex to medulla ratio with minimal to mild loss of corticomedullary distinction. A hyperechoic medullary band is observed adjacent to the corticomedullary junction. Mild pyelectasia is present (0.39 cm in the transverse plane). There is no evidence of nephroliths or hydronephrosis.

Adrenal Glands

The left adrenal gland is enlarged (0.44 cm at cranial pole) (0.70 cm at caudal pole) (1.89 cm in length) with a slightly irregular shape. A 0.68 x 0.69 cm hypoechoic nodule is observed at the caudal pole. Glandular echogenicity and detail at the cranial pole are normal. Surrounding vasculature appears normal.

A mass effect is suspected in the right adrenal gland (1.61 x 0.90 cm). The gland is enlarged, irregular and heterogeneous. There appears to be invasion into the caudal vena cava - a 1.56 x 0.72 cm tumor thrombus is visible within the lumen.

Spleen

The spleen is normal in size (0.64 cm in width at the level of the hilus) with a normal capsular contour. There is appropriate echogenicity and echotexture. A 0.62 x 0.50 cm irregular, hypoechoic to slightly heterogeneous nodule is observed just distal to the hilus. Splenic vasculature is normal.

Liver

The liver is subjectively enlarged with slightly swollen peripheral contours. The parenchyma is hyperechoic relative to the spleen and diffusely homogeneous in appearance. No distinct focal lesions are observed. Vascular and biliary tracts are of normal volume with no evidence of congestion. The gall bladder lumen is moderately distended. The wall is thin and smooth. A small amount of aggregated



PATIENT

Pebbles Rodriguez

echogenic partially dependent debris is observed within the lumen. The cystic and common bile ducts are normal/not seen. The gall bladder lumen is moderately distended. The wall is thin and smooth. A small to moderate amount of aggregated echogenic debris/sludge is observed within the lumen, most of which is gravity-dependent and some of which is suspended. The cystic and common bile ducts are normal/not seen.

SPECIES

Canine

Gastrointestinal

The gastric lumen is not distended. The gastric wall in the region of the fundus is normal in thickness with a normal layering pattern. In the region of the pyloric antrum, the muscularis layer is prominent. The pyloric outflow tract is patent. The small intestinal lumen is not dilated. The small intestinal wall thickness is normal with a normal layering pattern and appropriate mural detail. Discreet masses are not identified. The ileocecal colic junction and colonic wall are normal. No obstructive disease is noted.

BREED

Shih Tzu

SEX

Female, intact

Pancreas

The region of the pancreas is isoechoic relative to surrounding omental fat. No obvious parenchymal abnormalities are observed. There is no evidence of regional inflammation or effusion.

AGE

13 Yrs.

Free Abdomen

Trace free fluid is present. A few prominent mesenteric lymph nodes are visualized, the largest measuring 0.72 cm in length.

WEIGHT

8.9 lbs.

Other

The uterine body is visible (0.35 cm in width) and appears normal with no evidence of luminal distention or inflammation.

INTERPRETED BY

Andrea Nicastro, DVM,
Diplomate ACVIM
(Small Animal Internal
Medicine)

ULTRASONOGRAPHIC FINDINGS

Primary Findings:

- Suspected right adrenal mass effect with invasion into the caudal vena cava. Neoplasia (i.e., adenocarcinoma, pheochromocytoma) is suspected with a low possibility of benign pathology. A tumor thrombus is visible within the lumen of the caudal vena cava. Left adrenal nodule in the caudal pole. Differentials include nodular hyperplasia or emerging neoplasia.
- The diffuse hepatic changes are non-specific and could be consistent with vacuolar hepatopathy, regenerative nodular hyperplasia, and/or age-related remodeling. Inflammatory and infiltrative disease are considered less likely.
- The splenic nodule may represent a benign process (i.e., a focus of lymphoid hyperplasia or extramedullary hematopoiesis). However, a metastatic lesion cannot be completely excluded.
- The trace ascites may be secondary to increased hydrostatic pressure (i.e., due to the thrombus in the caudal vena cava). Increased vascular permeability is also possible.

Secondary Findings:

- Bilateral, age-related renal changes.
- Gallbladder debris- incidental.

IMAGING PERFORMED BY

Dr. Ferrer

HOSPITAL NAME

Paseos VC

REFERRING VET

Dr. Davila

INVOICE

12878

DATE

1/18/22



PATIENT

Pebbles Rodriguez

- The urinary bladder wall changes may be artifactual due to lack of full repletion. Alternatively, cystitis may be present. Correlation with clinical findings is recommended.

SPECIES

Canine

- The thickening of the muscularis layer at the level of the pyloric antrum may represent inflammation, hypertrophy or less likely, infiltrative neoplasia.

- The lymph node changes are most consistent with reactive lymphadenitis or lymphoid hyperplasia.

BREED

Shih Tzu

*An obvious cause for the patient's clinical signs is not identified in this study. However, passive congestion of the bowel as a result of the thrombus in the caudal vena cava is one possibility. Other differentials include microscopic gastrointestinal or pancreatic disease or other underlying metabolic issue.

SEX

Female, intact

INTERPRETATION OF THE FINDINGS & FURTHER RECOMMENDATIONS

- Three-view thoracic radiographs are recommended to assess for pulmonary metastases.
- To further investigate the GI signs, consider the following:
 - A fecal evaluation for ova/Giardia
 - Prophylactic deworming with Fenbendazole at 50 mg/kg once a day for 5 days is recommended. Repeat above protocol in 3 weeks.
 - Malabsorption panel including serum cobalamin, folate, TLI and PLI
 - +/- endoscopic or surgical gastrointestinal biopsies
- Regarding the history of hematuria, a urinalysis +/- a urine culture and sensitivity should be considered.
- Regarding the right adrenal mass, further evaluation could include the following:
 - Baseline blood pressure measurement
 - Low-dose dexamethasone suppression test and urine/blood catecholamine levels (Marshfield Lab) to assess for functional tumor
 - Abdominal CT scan to assess the degree of vascular invasion

AGE

13 Yrs.

WEIGHT

8.9 lbs.

INTERPRETED BY

Andrea Nicastro, DVM,
Diplomate ACVIM
(Small Animal Internal
Medicine)

IMAGING PERFORMED BY

Dr. Ferrer

HOSPITAL NAME

Paseos VC

REFERRING VET

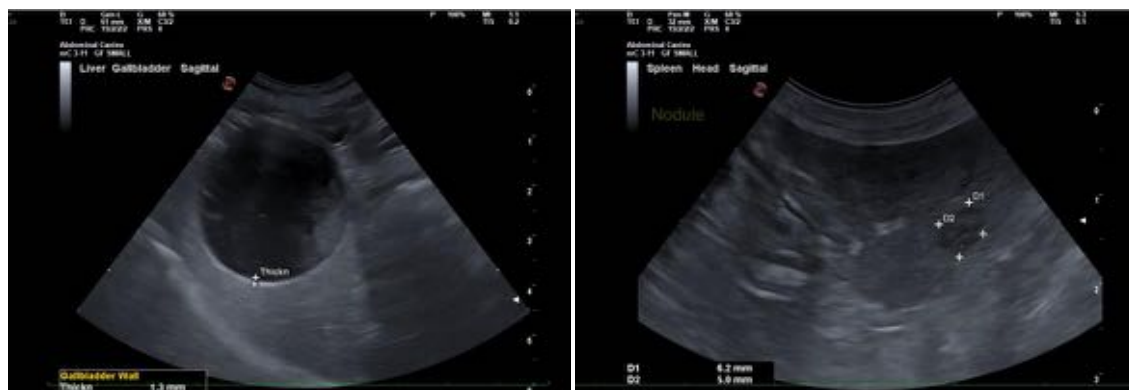
Dr. Davila

INVOICE

12878

DATE

1/18/22





PATIENT

Pebbles Rodriguez

SPECIES

Canine

BREED

Shih Tzu

SEX

Female, intact

AGE

13 Yrs.

WEIGHT

8.9 lbs.

INTERPRETED BY

Andrea Nicastro, DVM,
Diplomate ACVIM
(Small Animal Internal
Medicine)

**IMAGING
PERFORMED BY**

Dr. Ferrer

HOSPITAL NAME

Paseos VC

REFERRING VET

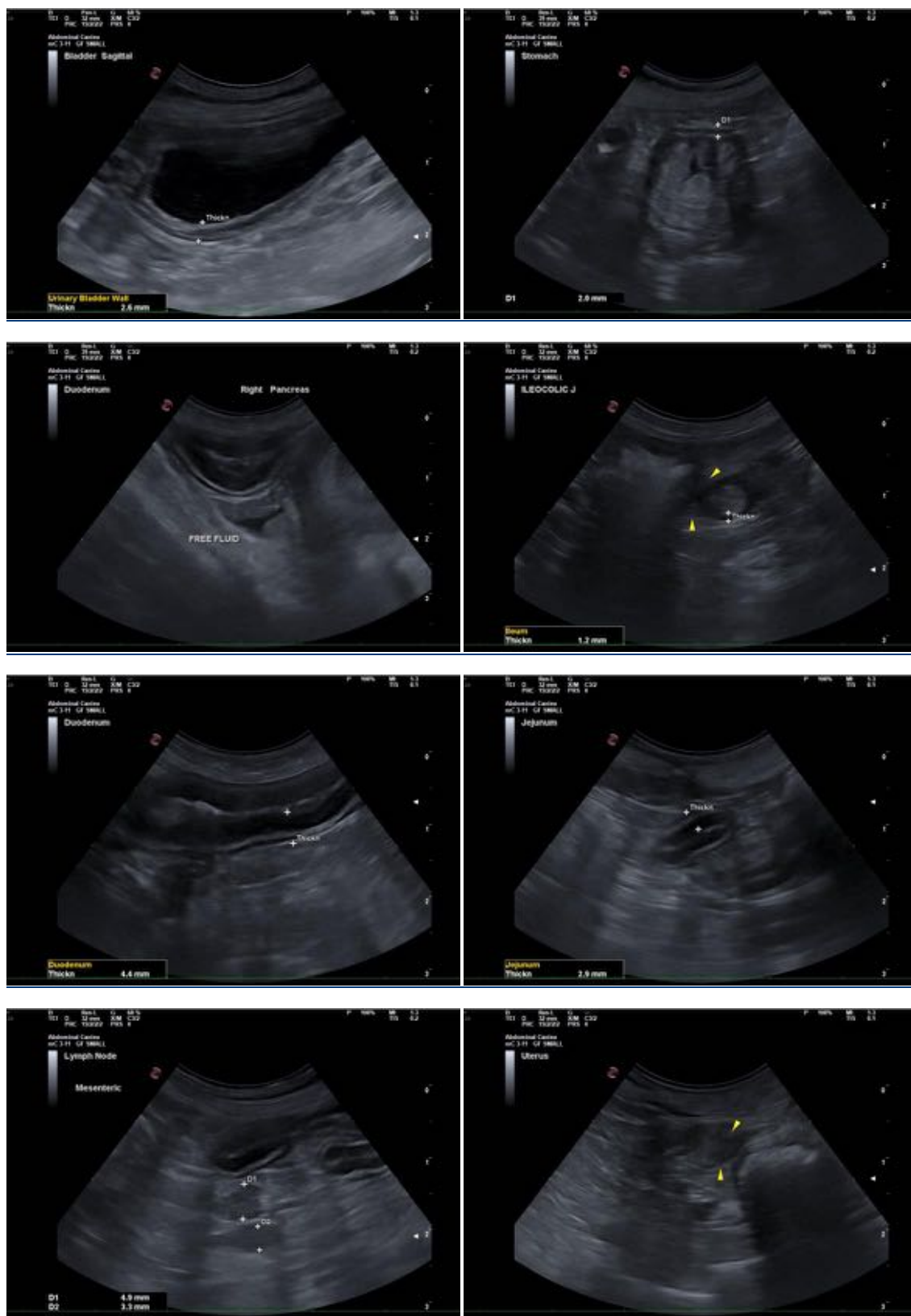
Dr. Davila

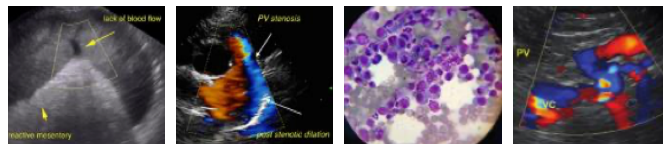
INVOICE

12878

DATE

1/18/22





PATIENT

Pebbles Rodriguez

SPECIES

Canine

BREED

Shih Tzu

SEX

Female, intact

AGE

13 Yrs.

WEIGHT

8.9 lbs.

INTERPRETED BY

Andrea Nicastro, DVM,
Diplomate ACVIM
(*Small Animal Internal
Medicine*)

**IMAGING
PERFORMED BY**

Dr. Ferrer

HOSPITAL NAME

Paseos VC

REFERRING VET

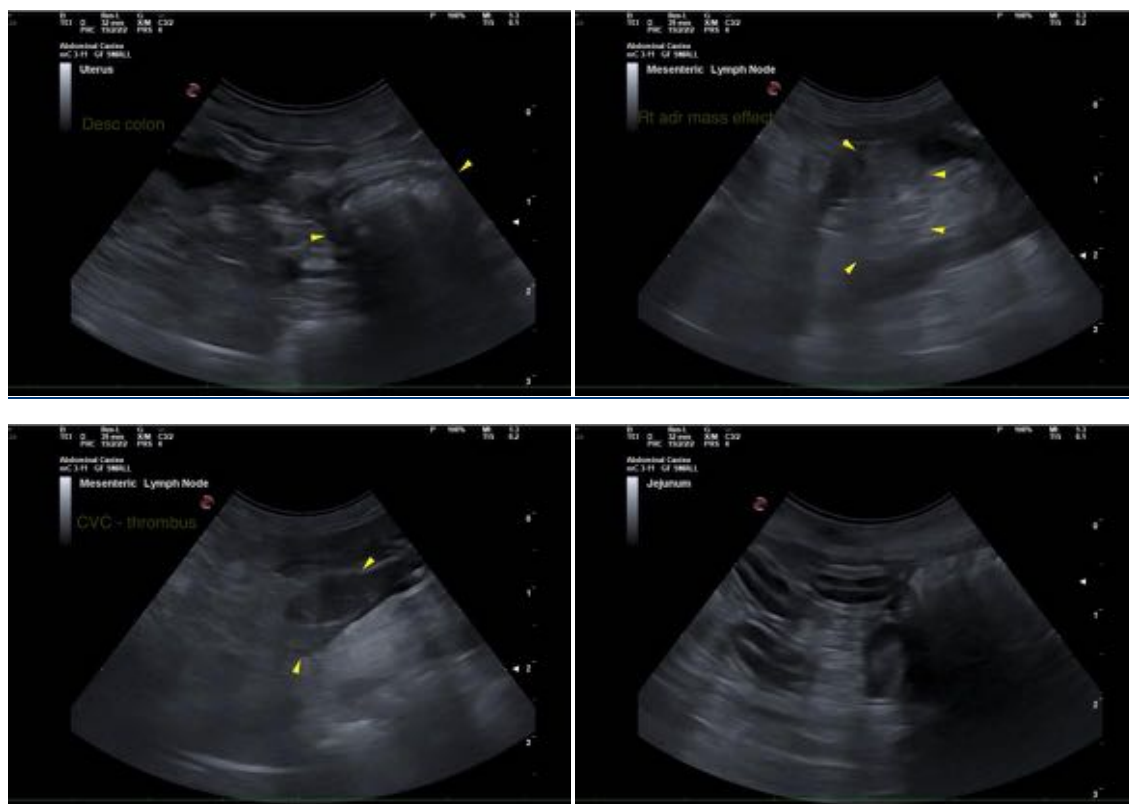
Dr. Davila

INVOICE

12878

DATE

1/18/22



The information and recommendations provided are based on the images presented by the referring veterinarian. No evaluation can be communicated regarding pathology that was not visible in the image/video clips provided.

Thank you for this referral. If the clinical or image interpretation does not parallel your findings or if I can be of any further assistance please contact me.

Andrea Nicastro, DVM, Diplomate ACVIM (*Small Animal Internal Medicine*)

Andrea.nicastro@sonopath.com