

PATIENT

Knight Maust

SPECIES

Canine

BREED

Pekipoo

SEX

Neutered Male

AGE

15

WEIGHT

17.8 lbs

INTERPRETED BY

Andrea Nicastro DVM
Diplomate ACVIM
(Sm Animal Internal Med)

**IMAGING
PERFORMED BY**

Pamela Harrigan, RDCS,
Cert Vet Sonog (IVUSS)

HOSPITAL NAME

Littleton AH

REFERRING VET

Tatyana Kalani, DVM

INVOICE

22400

DATE

1-17-26

PRESENTING CLINICAL SIGNS

History: Recheck AUS. History possible mineralization within prostatic urethra, large, cystic adrenal gland, bilateral kidney changes, mild pancreatitis, hepatopathy, possible developing GB mucocele. noted on prior AUS (7/11/24 Kathleen Sennello, DACVIM, SonoPath). Knight is clinically stable - has hyperadrenocorticism secondary to L adrenal tumor - on 10 mg Trilostane SID. Has chronic valvular disease. Recent BW showed GGT now elevated (26). On Veteryl 10 mg SID, Galliprant 20 mg SID, Dasuquin Advanced

ULTRASONOGRAPHIC EXAMINATION OF THE ABDOMEN

Urinary System

The urinary bladder is distended. The wall is normal in thickness, with a smooth mucosal surface. A scant amount of gravity-dependent mineralized sand is observed within the lumen. The region of the trigone and the proximal urethra, visible to a depth of 2 cm, are normal.

The prostate is normal in size (1.06 cm in width) with smooth peripheral contours. A 1.76 x 0.50 cm irregular, hyperechoic-to-mineralized focus is observed within the parenchyma. The remaining parenchyma is relatively homogenous in appearance. The prostatic urethra is not overtly dilated.

The left kidney is normal in size (5.10 cm in length) with a normal shape, smooth peripheral margins, and normal internal architecture. There is mild-to-moderate loss of corticomedullary distinction. Several hyperechoic shadowing diverticular foci are observed. A few, small, cortical cysts are seen. Mild pyelectasia is present (0.21 cm in the transverse plane). There is no evidence of infarcts or hydroureter.

The right kidney is normal in size (4.86 cm in length) with a normal shape, smooth peripheral margins, and normal internal architecture. There is mild-to-moderate loss of corticomedullary distinction. Several hyperechoic shadowing diverticular foci are observed. A few, small, cortical cysts are seen. Trace pyelectasia is present (0.14 cm in the transverse plane). There is no evidence of infarcts or hydroureter.

Adrenal Glands

The left adrenal gland is enlarged (1.89 cm at cranial pole) (0.86 cm at caudal pole) (3.20 cm in length), and irregular, with a mass effect. The parenchyma is diffusely heterogenous, with cystic areas. There is loss of glandular detail. There is no obvious evidence of invasion into the caudal vena cava. The mesentery surrounding the left adrenal gland is hyperechoic.

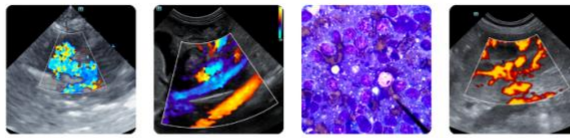
The right adrenal gland is subjectively normal in length (0.53 cm at cranial pole) (0.24 cm at caudal pole) with a slightly flattened contour. Glandular echogenicity and detail are normal. The phrenicoabdominal vein and surrounding vasculature are normal.

Spleen

The spleen is normal in size (1.07 cm in width at the level of the hilus) with a normal capsular contour. There is appropriate echogenicity and echotexture. A few, small, ill-defined myelolipomas are observed in the region of the hilus. Splenic vasculature is normal.

Liver

The liver is subjectively enlarged, with swollen peripheral contours. The parenchyma is isoechoic relative to the spleen, and mildly heterogenous in appearance. A 1.8 x 1.0 cm ill-defined, hypoechoic nodule is observed on the left side. Hepatic vasculature and intrahepatic biliary tracts are of normal volume with no evidence of congestion.



PATIENT

Knight Maust

The gallbladder lumen is moderately distended. The wall is thin and smooth. A moderate-to-large amount of aggregated, echogenic-to-mineralized, partially dependent to suspended sludge is observed within the lumen. The cystic and common bile ducts are normal/not seen.

SPECIES

Canine

Gastrointestinal

The gastric lumen is not distended. The gastric wall and pylorus are normal in thickness with a normal layering pattern. The pyloric outflow tract is patent. The small intestinal lumen is not dilated. The small intestinal wall is normal in thickness with a normal layering pattern and appropriate mural detail. Discreet masses are not identified. The colonic wall is normal. There is no evidence of an obstructive pattern.

BREED

Pekipoo

SEX

Neutered Male

Pancreas

The region of the pancreas is isoechoic relative to surrounding omental fat. No obvious parenchymal abnormalities are observed. There is no evidence of regional inflammation or effusion.

AGE

15

Lymph Nodes

The abdominal lymph nodes are normal/not visible.

WEIGHT

17.8 lbs

Free Abdomen

There is no obvious evidence of free fluid.

ULTRASONOGRAPHIC FINDINGS

INTERPRETED BY

Andrea Nicastro DVM
Diplomate ACVIM
(Sm Animal Internal Med)

Primary Findings

- Left adrenal mass effect with mild, adjacent to retroperitonitis. The right adrenal gland is atrophied, likely due to a functional left renal tumor.
- The hepatic changes are nonspecific and could be secondary to inflammatory disease (i.e., cholangiohepatitis, chronic hepatitis), hepatotoxicosis, infiltrative neoplasia (i.e., lymphoma), vacuolar hepatopathy, regenerative nodular hyperplasia, other hepatopathy, or some combination thereof.
- The gallbladder changes are consistent with a developing mucocele.
- Bilateral nonspecific age-related renal changes with dystrophic mineralization, pyelectasia, and cortical cysts
- Focus of prostatic mineralization. This finding may be a benign age-related incidental finding. Alternatively, emerging neoplasia cannot be excluded.

IMAGING PERFORMED BY

Pamela Harrigan, RDCS,
Cert Vet Sonog (IVUSS)

HOSPITAL NAME

Littleton AH

REFERRING VET

Tatyana Kalani, DVM

Secondary Findings

- Scant urinary bladder sand

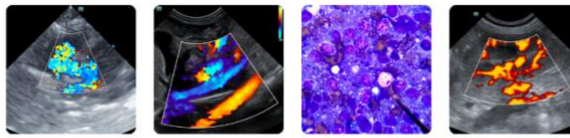
INVOICE

22400

*Overall, changes are similar to the previous sonogram. However, a splenic nodule is not visualized on today's study.

DATE

1-17-26



PATIENT

Knight Maust

SPECIES

Canine

BREED

Pekipoo

SEX

Neutered Male

AGE

15

WEIGHT

17.8 lbs

INTERPRETED BY

Andrea Nicastro DVM
Diplomate ACVIM
(Sm Animal Internal Med)

IMAGING PERFORMED BY

Pamela Harrigan, RDCS,
Cert Vet Sonog (IVUSS)

HOSPITAL NAME

Littleton AH

REFERRING VET

Tatyana Kalani, DVM

INVOICE

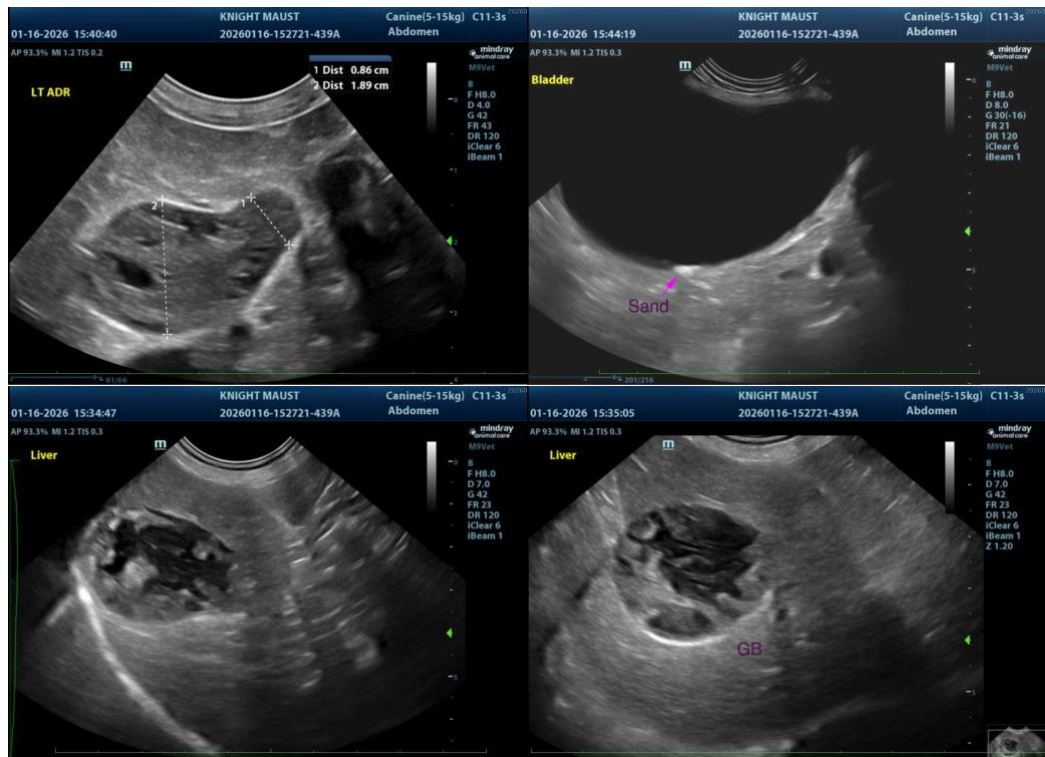
22400

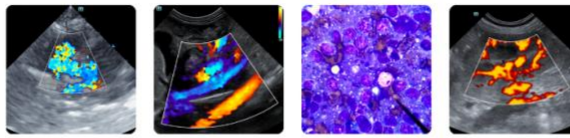
DATE

1-17-26

INTERPRETATION OF THE FINDINGS & FURTHER RECOMMENDATIONS

- Serial monitoring (i.e., every 3-4 months) of the patient's liver values is recommended. If values continue to increase, a repeat abdomen ultrasound +/- a more advanced hepatic work-up (i.e., tissue sampling) may be warranted. Continuation of Ursodiol is recommended, with close sonograph monitoring of the gallbladder to assess for progression to a fully-formed mucocele. Alternatively, a cholecystectomy with submission of the gallbladder for histopathology and aerobic and anaerobic bile cultures can be considered. If pursued, liver biopsies should also be obtained.
- Regarding the prostatic mineralization, a urine BRAF test can be considered to further evaluate for lower urinary tract neoplasia. A positive test confirms neoplasia. However, a negative test does not rule out the possibility of cancer, and further testing (i.e., tissue sampling) may be necessary to get a definitive diagnosis.





PATIENT

Knight Maust

SPECIES

Canine

BREED

Pekipoo

SEX

Neutered Male

AGE

15

WEIGHT

17.8 lbs

INTERPRETED BY

Andrea Nicastro DVM
Diplomate ACVIM
(Sm Animal Internal Med)

IMAGING PERFORMED BY

Pamela Harrigan, RDCS,
Cert Vet Sonog (IVUSS)

HOSPITAL NAME

Littleton AH

REFERRING VET

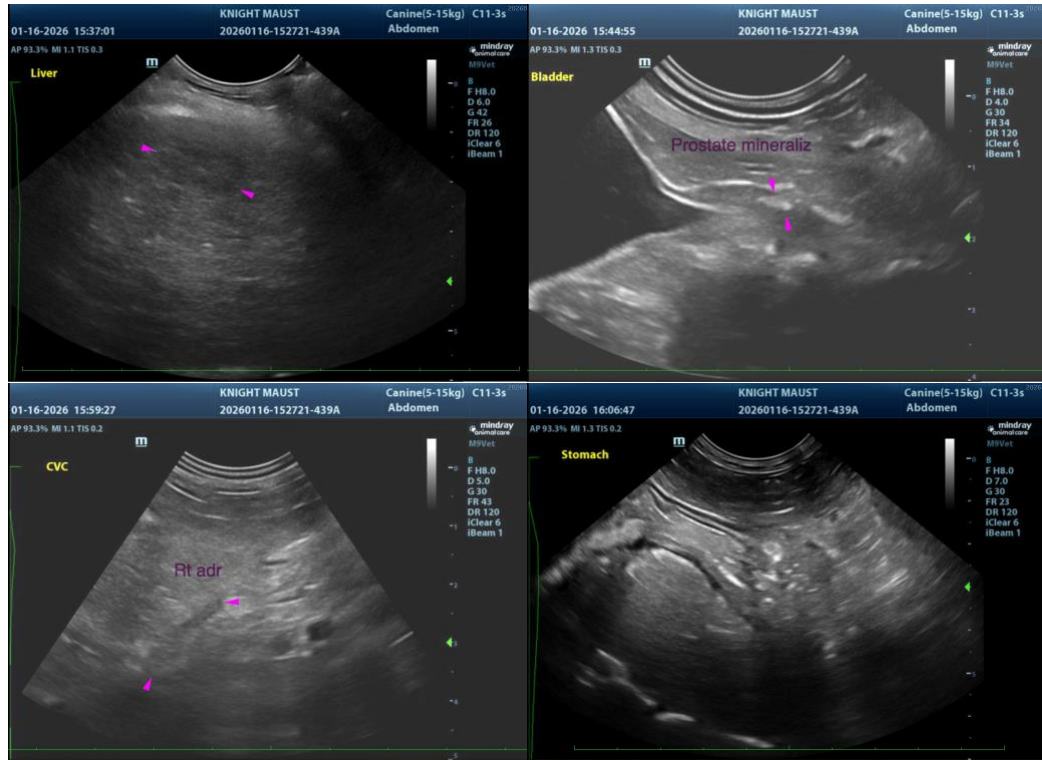
Tatyana Kalani, DVM

INVOICE

22400

DATE

1-17-26



The information and recommendations provided are based on the images presented by the referring veterinarian/sonographer. No evaluation can be communicated regarding pathology that was not visible in the image/video clips provided.

Thank you for this referral. If the clinical or image interpretation does not parallel your findings or if I can be of any further assistance, please contact me.

Andrea Nicastro, MPH, DVM, Diplomate DACVIM (Small Animal Internal Medicine)
info@SonoPath.com