

**DATE PRESENTING CLINICAL SIGNS**

1/17/23

5 days ago, got into trash. The next morning, he vomited up all of his dinner. Wasn't able to keep down any food or water for next few days. Diarrhea started 2 days ago. Went to rDVM yesterday; had BW and rads; no obvious obstruction but suspicious. Liver values elevated. Given SQ fluids and metro. Today he was able to drink and kept water down. (Regurgitated in room w/owners at presentation though.) Does have a history of "sensitive stomach" and they avoid giving him any people food as it gives him diarrhea easily.

PATIENT

Crush Corbin

Lab: ALT 701, ALP 880, T-bili 3.9, thrombocytopenia, hemoconcentration, mild leukocytosis with a neutrophilia and monocytosis

SPECIES

Canine

Current Medications: buprenorphine, ampicillin, metronidazole, ondanestron, protonix
 Radiographs: Bunched small intestines; small gas bubbles throughout several portions; stomach moderately dilated; gas dilated intestines in cranial abdomen - unable to determine if colon vs SI

BREED

Great Dane

Date of Previous IntraPet Ultrasound: No previous.
 Sedation: Not required to complete full diagnostic ultrasound.
 Stat Report: STAT requested.
 Imaging Performed By: Rachel Brillhart, RDMS.

SEX

Male, intact

ULTRASONOGRAPHIC EXAMINATION OF THE ABDOMEN**AGE**

5/16/2017

Urinary System

The urinary bladder wall is normal in thickness and the mucosal surface is smooth. The bladder lumen is moderately distended with anechoic urine. No masses, inflammatory changes or calculi are observed. The region of the trigone and the visible portion of the proximal urethra are normal.

WEIGHT

142.4 lbs.

The prostate is enlarged (6.13 cm in width) with smooth curvilinear peripheral contours. The parenchyma is hyperechoic relative to surrounding omental fat and subtly heterogeneous in appearance. A 0.24 cm cystic area is visualized. No focal lesions are observed. The prostatic urethra is not overtly dilated.

INTERPRETED BY

Andrea Nicastro, DVM,
 Diplomate ACVIM
 (Small Animal Internal
 Medicine)

The left kidney is normal size (9.44 cm in length); normal shape and architecture with smooth peripheral margins. There is a normal 1:3 cortex to medulla ratio with normal corticomedullary distinction. There is no evidence of pyelectasia, nephroliths, infarcts or hydroureter. Renal vasculature is normal.

HOSPITAL NAME

Animal Emergency
 Hospital

The right kidney is normal size (10.22 cm in length); normal shape and architecture with smooth peripheral margins. There is a normal 1:3 cortex to medulla ratio with normal corticomedullary distinction. Mild to moderate pyelectasia is present (0.46 cm in the longitudinal plane). There is no evidence of nephroliths, infarcts or hydroureter. Renal vasculature is normal.

REFERRING VET

Dr. Martinoli

Adrenal Glands

The left adrenal gland is normal size (0.53 cm at cranial pole) (0.81 cm at caudal pole) (2.93 cm in length); normal shape; homogenous parenchyma. The glandular echogenicity and detail are unremarkable. Capsule, cortex, and medullary definition are normal. The phrenicoabdominal vein and surrounding vasculature are normal.

INVOICE

14450

The right adrenal gland is normal size (0.96 cm at cranial pole) (0.70 cm at caudal pole) (3.07 cm in length); normal shape; homogenous parenchyma. The glandular echogenicity and detail are unremarkable. Capsule, cortex, and medullary definition are normal. The phrenicoabdominal vein and surrounding vasculature are normal.

Spleen

The spleen is prominent to enlarged in size (2.76 cm in width at the level of the hilus) with scalloping of the medial contour. The parenchyma is subjectively hypoechoic and subtly mottled in appearance. No focal lesions are observed. Splenic vasculature is normal with no evidence of thrombosis.

Liver

The liver is subjectively enlarged with swollen peripheral contours. The parenchyma is subjectively hypoechoic and homogeneous in appearance. There is an increase in portal markings. Vascular is of normal volume with no evidence of congestion. The gall bladder lumen is mildly to moderately distended. The wall is thickened (up to 0.46 cm) with a “double-walled” effect. A scant amount of echogenic debris is observed within the lumen. The cystic and common bile ducts are normal/not seen.

Gastrointestinal

The gastric lumen is not distended. The gastric wall is normal in thickness with a normal layering pattern. A few bowel segments are mildly to moderately fluid distended and hypomotile. The duodenal and jejunal walls are normal in thickness with a normal layering pattern. The ileum is diffusely thickened (up to 1.37 cm) with loss of the normal layering pattern. The wall of the ascending colon is also thickened (up to 0.52 cm). The wall of the descending colon is normal. The colonic lumen distally appears empty.

Pancreas

The base and limbs of the pancreas are visible with normal curvilinear peripheral contours. The parenchyma is largely isoechoic relative to surrounding omental fat and slightly mottled in appearance. The pancreatic duct is visible but not overtly dilated. There is no evidence of peripancreatic inflammation or effusion.

Free Abdomen

A small amount of free fluid is present. The mesentery in the mid-abdominal region is hyperechoic. The abdominal lymph nodes are normal/not visible.

Other

The testicles are subjectively normal in size (left testicle 3.93 x 1.90 cm; right testicle 4.00 x 1.97 cm) with normal shape. Pinpoint hyperechoic foci are observed in the parenchyma of both testes. The parenchyma is otherwise homogeneous.

A brief echocardiogram reveals no obvious evidence of pericardial effusion.

ULTRASONOGRAPHIC FINDINGS

Primary Findings:

- The ileal changes are most consistent with infiltrative neoplasia (i.e., lymphoma). However, a severe inflammatory process cannot be completely excluded. The ascending colonic wall changes could be consistent with inflammation or infiltrative neoplasia
- The hepatomegaly could be consistent with infiltrative neoplasia (i.e., lymphoma), diffuse inflammatory disease, Leptospirosis or other hepatopathy.
- The splenic changes could be consistent with infiltrative neoplasia (i.e., lymphoma) or a benign process (i.e., lymphoid hyperplasia, extramedullary hematopoiesis, antigenic stimulation or splenitis).
- Diffuse peritonitis, likely secondary to bowel +/- hepatic and splenic pathology.

Secondary Findings:

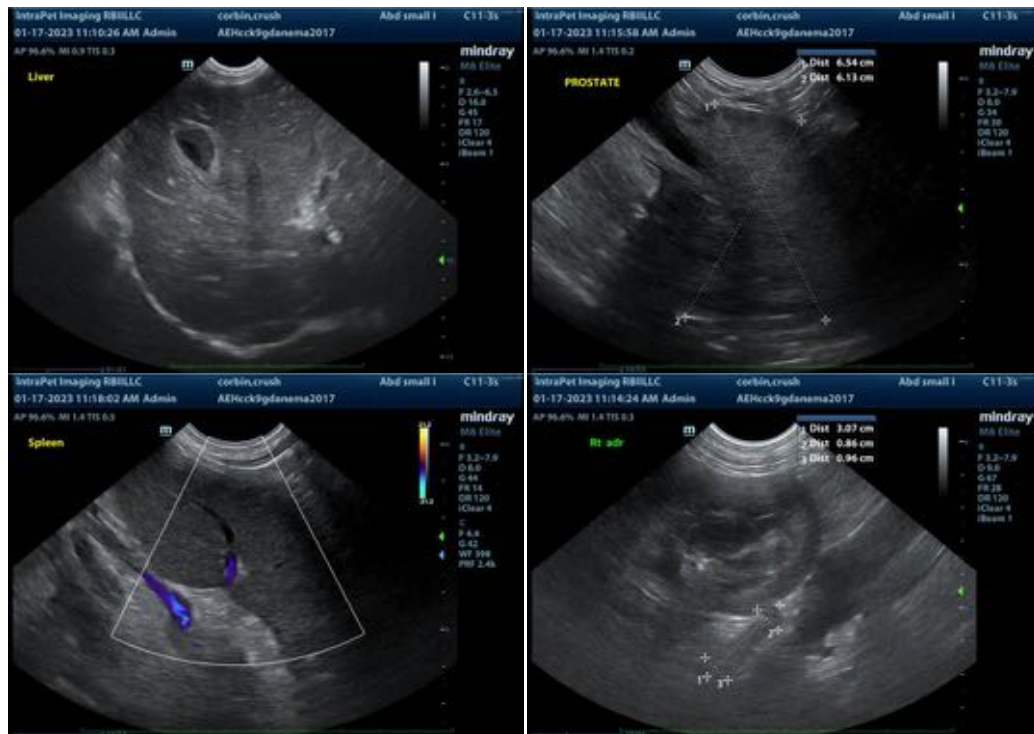
- The gallbladder wall changes could be consistent with cholestasis, increased hydrostatic pressure, low oncotic pressure (if applicable), anaphylaxis, other.
- The right pyelectasia may be secondary to IV fluid therapy, pyelonephritis or some combination thereof.

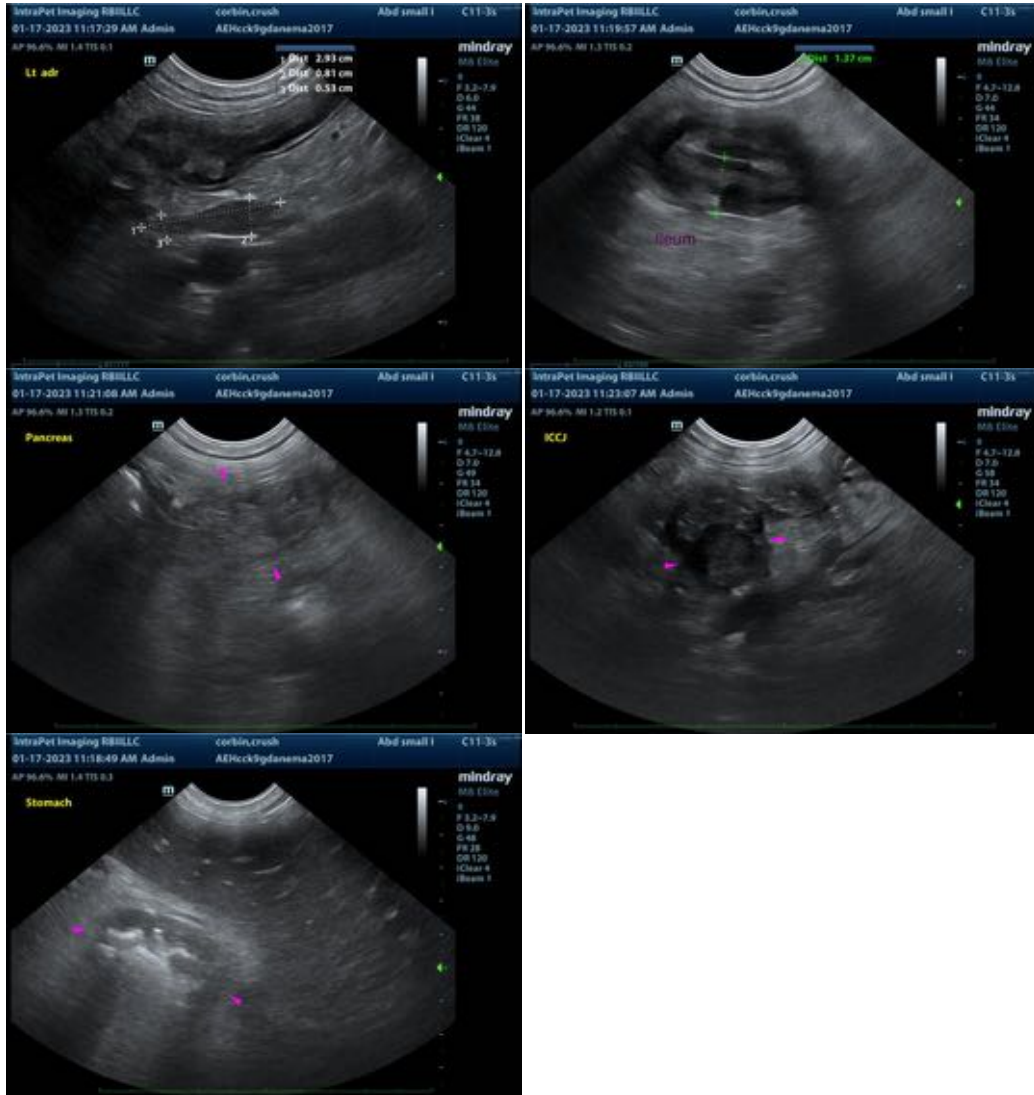
- The pancreatic changes are suggestive of edema, pancreatitis +/- parenchymal remodeling.
- The prostate changes are most consistent with benign prostatic hyperplasia.
- The mineralization within the parenchyma of both testicles is likely a benign incidental finding.

*Although there is no obvious evidence of a foreign body/obstruction, this possibility cannot be completely excluded. However, a GI foreign body does not explain the liver enzyme elevations.

INTERPRETATION OF THE FINDINGS & FURTHER RECOMMENDATIONS

- Thoracic radiographs are recommended to assess cardiopulmonary status.
- Consider fine needle aspirates of the liver, spleen and ileum, if clotting status is appropriate. 25-gauge needles should be used. Alternatively, an abdominal exploratory with biopsies of these regions can also be considered.
- Given the liver enzyme elevations, also consider Leptospirosis testing (i.e., blood and urine PCR, serology).





The information and recommendations provided are based on the images presented by the referring veterinarian. No evaluation can be communicated regarding pathology that was not visible in the image/video clips provided.

Thank you for this referral. If the clinical or image interpretation does not parallel your findings or if I can be of any further assistance please contact me.

Andrea Nicastro, MPH, DVM, Diplomate DACVIM (Small Animal Internal Medicine)
 info@SonoPath.com