



PATIENT PRESENTING CLINICAL SIGNS

Otis Altemose History: Pancreatitis (1' R/O) vs GE vs FBO vs other. Nausea/ V+, hyporexia, FUO going on a couple of weeks.

SPECIES

Canine Meds: Panoquell (just started this am); Cerenia, Ondansetron; Gabapentin + Fentanyl/Lidocaine CRI. Abnormal PE/Chem/CBC/UA Results: Glob 4.6; ALP 531; mild Neutrophilia w/N WBC COUN

BREED ULTRASONOGRAPHIC EXAMINATION OF THE ABDOMEN

Mix **Urinary System**

The urinary bladder wall is normal in thickness. The mucosal surface is smooth. The bladder is moderately distended. Luminal contents are anechoic. No cystic calculi are observed. The region of the trigone and the proximal urethra, visible to a depth of 3 cm, are normal.

SEX

Neutered Male

The prostate is normal in size (0.66 cm in width) and shape. Parenchyma is homogenous. The prostatic urethra appears normal without evidence of dilation or obstruction.

AGE

6

The left kidney is normal in size (7.03 cm in length) with a normal shape, smooth peripheral margins, and normal internal architecture. There is moderate loss of corticomedullary distinction. Several hyperechoic shadowing diverticular foci are observed. There is no evidence of pyelectasia, infarcts or hydronephrosis. Renal vasculature is normal.

WEIGHT

55.25 lbs

The right kidney is normal in size (7.67 cm in length) with a normal shape, smooth peripheral margins, and normal internal architecture. There is moderate loss of corticomedullary distinction. Several hyperechoic shadowing diverticular foci are observed. There is no evidence of pyelectasia, infarcts or hydronephrosis. Renal vasculature is normal.

INTERPRETED BY

Andrea Nicastro DVM
 Diplomate ACVIM
 (Sm Animal Internal Med)

Adrenal Glands

The left adrenal gland is normal in size (0.45 cm at cranial pole) (0.54 cm at caudal pole) with a normal shape and homogenous parenchyma. The glandular echogenicity and detail are unremarkable. Capsule, cortex, and medullary definition are normal. The phrenicoabdominal vein and surrounding vasculature are normal.

IMAGING PERFORMED BY

Shari Reffi, CVT

The right adrenal gland is normal in size (1.12 cm at cranial pole) (0.67 cm at caudal pole) with a normal shape and homogenous parenchyma. The glandular echogenicity and detail are unremarkable. Capsule, cortex, and medullary definition are normal. The phrenicoabdominal vein and surrounding vasculature are normal.

HOSPITAL NAME

Harmony AH

Spleen

The spleen is normal in size (2.02 cm in width at the level of the hilus) with a normal capsular contour. There is appropriate echogenicity and echotexture. No focal lesions are observed. Splenic vasculature is normal.

REFERRING VET

Dr. Gruber

Liver

The liver is subjectively normal in size with normal contours and structure. There is appropriate echogenicity and echotexture. No overt structural evidence of inflammatory, infiltrative, or regenerative pathology is evident. Vascular and biliary tracts are of normal volume with no evidence of congestion.

INVOICE

22393

DATE

1-16-26

The gallbladder lumen is moderately distended. The wall is thin and smooth. Luminal contents are mostly anechoic. The cystic and common bile ducts are normal/not seen.

Gastrointestinal

The gastric lumen is not distended. The gastric wall and pylorus are normal in thickness with a normal



PATIENT Otis Altemose
SPECIES Canine
BREED Mix
SEX Neutered Male
AGE 6
WEIGHT 55.25 lbs

layering pattern. small intestinal lumen is not overtly dilated. In one a focal segment of small intestine, the wall is thickened (up to 0.62 cm) and hypoechoic, with loss of the normal layering pattern. Within this region, a small amount of soft, shadowing material is observed. The remaining small intestinal segments are normal in thickness with a normal layering pattern and appropriate mural detail. The colonic wall is normal. There is no obvious evidence of an obstructive pattern.

Pancreas

The region of the pancreas is isoechoic relative to surrounding omental fat. No obvious parenchymal abnormalities are observed. There is no evidence of regional inflammation or effusion.

Lymph Nodes

At least one-to-two hypoechoic mesenteric lymph nodes are visualized (one measuring 2.8 x 1.3 cm). Surrounding mesentery is hyperechoic.

Free Abdomen

There is no obvious evidence of free fluid.

ULTRASONOGRAPHIC FINDINGS

Primary Findings

- Focal small intestinal wall thickening. This could be consistent with emerging neoplasia (i.e., lymphoma, adenocarcinoma, leiomyosarcoma, or a focal inflammatory process). The soft, shadowing material observed within this segment may represent foreign material or normal ingesta. It appears nonobstructive at the time of this study.

- The mesenteric lymphadenopathy could be consistent with emerging neoplasia or reactive change.

Secondary Findings

- Bilateral nonspecific age-related renal changes with dystrophic mineralization

INTERPRETATION OF THE FINDINGS & FURTHER RECOMMENDATIONS

Consider fine-needle aspirates of the thickened bowel segment and enlarged mesenteric lymph nodes (assuming normal clotting status). Twenty-five gauge-needles should be used. If the cytology results are inconclusive, or if these areas are not accessible for aspiration, consider an abdominal exploratory, with biopsies of these areas. Three-view thoracic radiographs are recommended prior to any anesthetic event.

INTERPRETED BY
 Andrea Nicastro DVM
 Diplomate ACVIM
 (Sm Animal Internal Med)

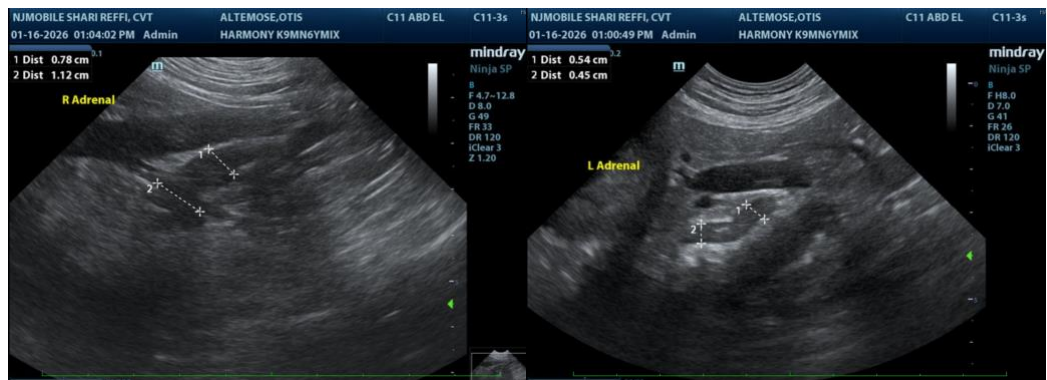
IMAGING PERFORMED BY
 Shari Reffi, CVT

HOSPITAL NAME
 Harmony AH

REFERRING VET
 Dr. Gruber

INVOICE
 22393

DATE
 1-16-26





PATIENT

Otis Altemose

SPECIES

Canine

BREED

Mix

SEX

Neutered Male

AGE

6

WEIGHT

55.25 lbs

INTERPRETED BY

Andrea Nicastro DVM
 Diplomate ACVIM
 (Sm Animal Internal Med)

IMAGING PERFORMED BY

Shari Reffi, CVT

HOSPITAL NAME

Harmony AH

REFERRING VET

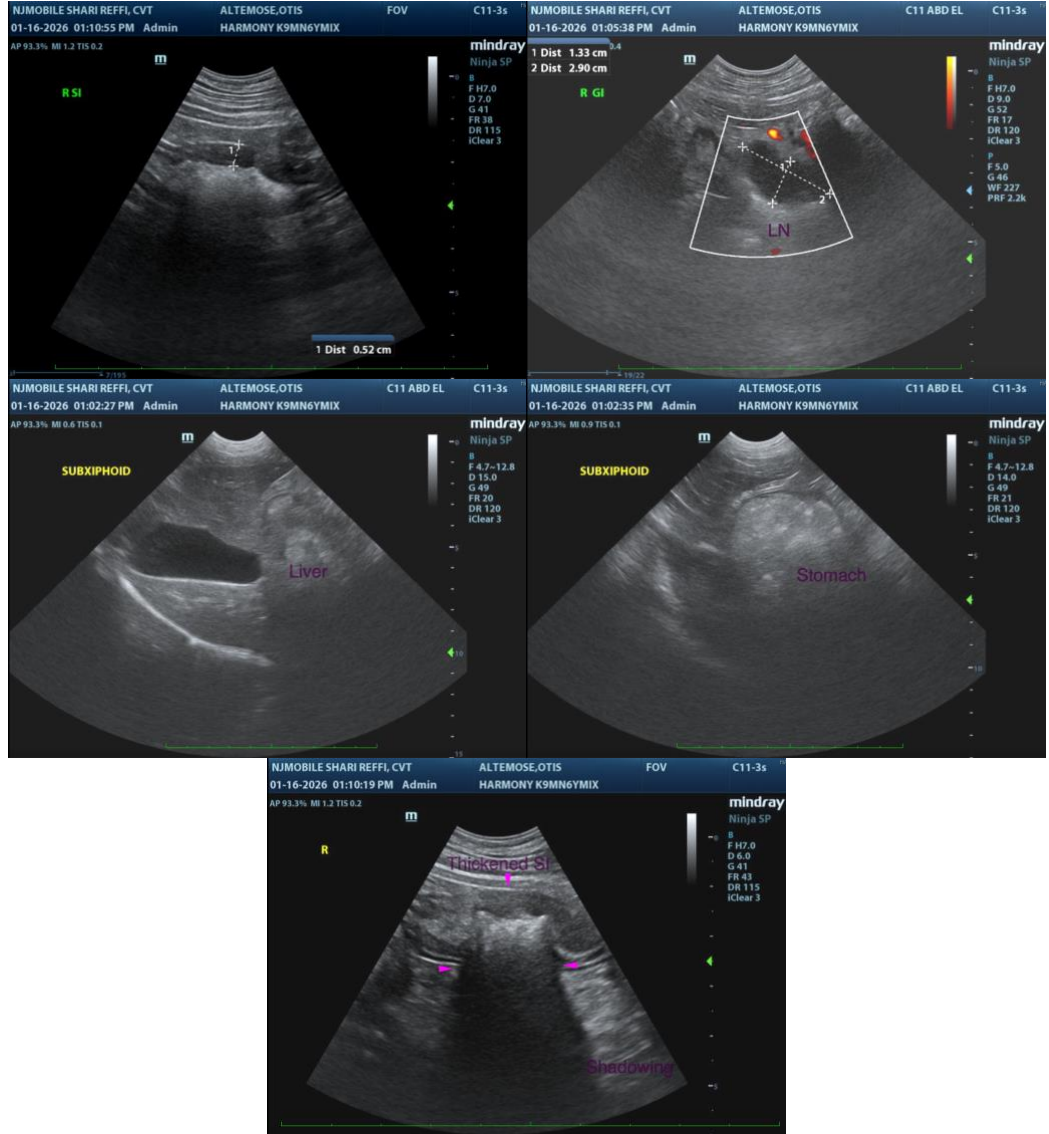
Dr. Gruber

INVOICE

22393

DATE

1-16-26



The information and recommendations provided are based on the images presented by the referring veterinarian/sonographer. No evaluation can be communicated regarding pathology that was not visible in the image/video clips provided.

Thank you for this referral. If the clinical or image interpretation does not parallel your findings or if I can be of any further assistance, please contact me.

Andrea Nicastro, MPH, DVM, Diplomate DACVIM (Small Animal Internal Medicine)
info@SonoPath.com