



PATIENT PRESENTING CLINICAL SIGNS

Chloe Gerritson History: Vomiting almost every day for the last month-bl'd in vomit. Weight loss decreased appetite. Current meds: Methimazole, Sucralfate, rec'd sqf and Cerenia 1/10.

SPECIES Abnormal PE/Chem/CBC/UA Results: 1/6/23- Lymph 0.56 (0.73L); Mono 0.06(o.07L); Cr 0.5 (0.8L); TP 5.9 (6.0L); Gluc 164 (130H); Alt 278 (100H) T4 >8.0

Feline

ULTRASONOGRAPHIC EXAMINATION OF THE ABDOMEN

BREED *Urinary System*

DSH The urinary bladder, trigone, and pelvic urethra are normal in thickness and the mucosal surface is smooth. The bladder is moderately distended. A scant amount of echogenic debris is observed within the lumen. No masses, inflammatory changes or calculi are observed. The region of the trigone and visible portion of the proximal urethra are normal.

SEX

Spayed Female The left kidney is normal in size (3.61 cm in length) with a normal shape, architecture and smooth peripheral margins. The cortex is hyperechoic. There is a normal 1:3 cortex to medulla ratio with poor corticomedullary distinction. There is no evidence of pyelectasia, nephroliths, infarcts or hydronephrosis. Renal vasculature is normal.

AGE

15 years The right kidney is normal in size (3.46 cm in length) with a slightly irregular shape, smooth peripheral margins, and normal internal architecture. The cortex is hyperechoic. There is poor corticomedullary distinction. Several hyperechoic shadowing diverticular foci are observed. There is no evidence of pyelectasia, infarcts or hydronephrosis. Renal vasculature is normal.

WEIGHT

5.5 lbs

Adrenal Glands

The left adrenal gland is normal in size (0.31 cm width). Normal shape and glandular echogenicity. The phrenicoabdominal vein and surrounding vasculature are normal.

INTERPRETED BY

Andrea Nicastro, DVM,
Diplomate ACVIM (*Small Animal Internal Medicine*)

The region of the right adrenal gland is evaluated. No obvious pathology is observed.

IMAGING PERFORMED BY

Shari Reffi, CVT

Spleen

The spleen is normal in size (0.64 cm in width at the level of the hilus) with a normal capsular contour. There is appropriate echogenicity and echotexture. A 0.16 cm hyperechoic nodule is observed cranial- to mid-spleen. Splenic vasculature is normal.

HOSPITAL NAME

Newton VH

Liver

The liver is subjectively normal in size with normal peripheral contours. The parenchyma is isoechoic relative to the spleen and diffusely homogeneous in appearance. No distinct focal lesions are observed. Vascular and biliary tracts are of normal volume with no evidence of congestion. The portal vein to caudal vena cava ratio is approximately 1: 1.

REFERRING VET

Dr. Kim

The gall bladder lumen is moderately distended. The wall is thin and smooth. A small amount of suspended, echogenic debris is observed within the lumen. The cystic and common bile ducts are normal.

INVOICE

12038

Gastrointestinal

The gastric lumen is minimally fluid-distended. A 3.00 cm segment of wall in the region of the lesser curvature is severely thickened (up to 1.27 cm) and hypoechoic with a loss of the normal layering pattern. The remaining gastric wall is normal in thickness with a normal layering pattern. The small intestinal lumen is segmentally dilated with chyme. The small intestinal wall is normal in thickness with a normal layering pattern and appropriate mural detail. The muscularis layer of the distal ileum is prominent. The colonic wall is normal. There is no evidence of an obstructive pattern.

DATE

1.12.23



PATIENT

Chloe Gerritson

Pancreas

The right limb is visible/prominent with minimal deviation from the normal peripheral contours. The parenchyma is mildly hypoechoic relative to surrounding omental fat. No focal lesions are observed. The pancreatic duct is not overtly dilated.

SPECIES

Feline

Free Abdomen

Trace free fluid is observed. A few prominent mesenteric lymph nodes are visualized (the largest measuring 2.61 cm in length).

BREED

DSH

Other

A brief echocardiogram reveals no obvious evidence of pericardial effusion.

SEX

Spayed Female

Primary Findings

- The focal gastric wall thickening is concerning for infiltrative neoplasia (i.e., lymphoma, adenocarcinoma, other). However, a focal inflammatory process cannot be completely excluded.
- The abdominal lymphadenopathy could be consistent with reactive change or emerging neoplasia.

AGE

15 years

Secondary Findings

- The pancreatic changes may be a normal variant for this patient or could be consistent with mild, chronic pancreatitis. Correlation with clinical findings is recommended.
- Bilateral degenerative renal changes with right pyelectasia
- The hyperechoic splenic nodule is most consistent with a benign process (i.e., myelolipoma) with a low possibility of an emerging tumor (i.e., mast cell tumor).

WEIGHT

5.5 lbs

INTERPRETED BY

Andrea Nicastro, DVM,
Diplomate ACVIM (*Small Animal Internal Medicine*)

IMAGING PERFORMED BY

Shari Reffi, CVT

HOSPITAL NAME

Newton VH

REFERRING VET

Dr. Kim

INTERPRETATION OF THE FINDINGS & FURTHER RECOMMENDATIONS

- Three-view thoracic radiographs are recommended to assess for pulmonary metastases.
- If accessible, a fine-needle aspirate of the thickened portion of gastric wall is recommended, along with aspiration of the prominent mesenteric lymph nodes. If the cytology results are inconclusive or if these areas are inaccessible, consider endoscopic biopsies of the stomach wall or surgical gastric and abdominal lymph node biopsies.
- A malabsorption panel, including serum cobalamin and folate, TLI and PLI is also recommended.

INVOICE

12038

DATE

1.12.23



PATIENT

Chloe Gerritson

SPECIES

Feline

BREED

DSH

SEX

Spayed Female

AGE

15 years

WEIGHT

5.5 lbs

INTERPRETED BY

Andrea Nicastro, DVM,
Diplomate ACVIM (*Small Animal Internal Medicine*)

IMAGING PERFORMED BY

Shari Reffi, CVT

HOSPITAL NAME

Newton VH

REFERRING VET

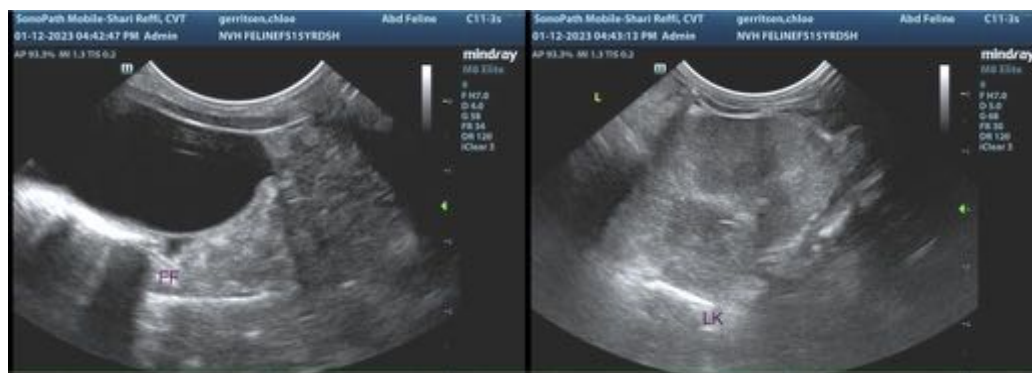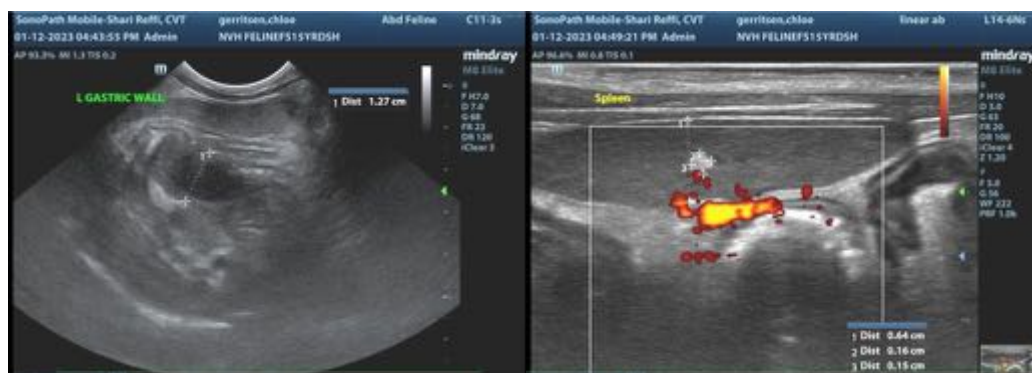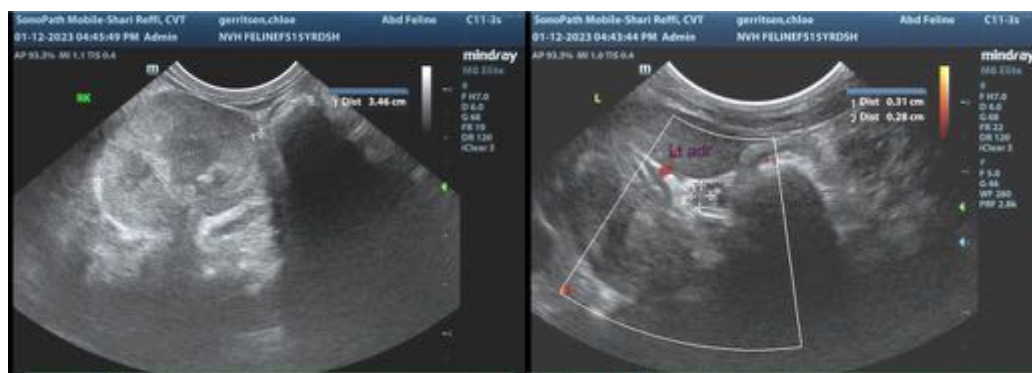
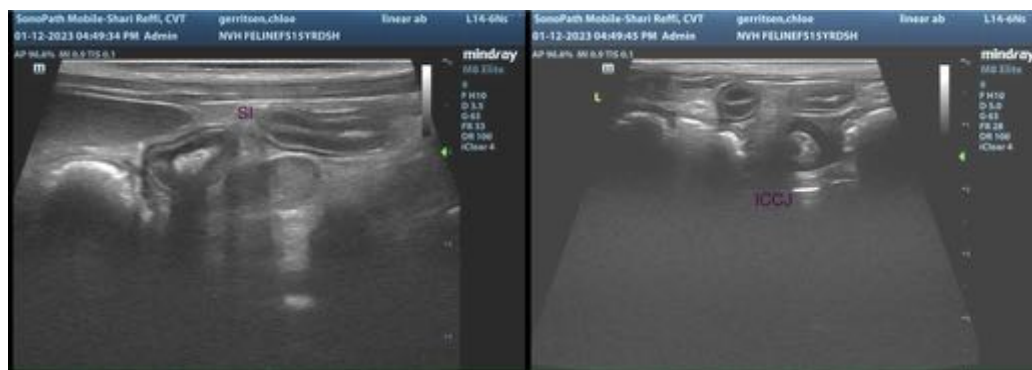
Dr. Kim

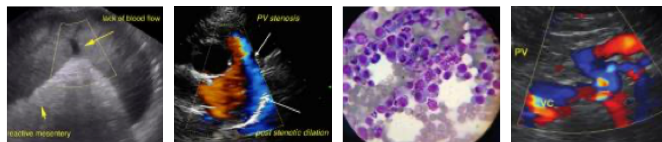
INVOICE

12038

DATE

1.12.23





PATIENT

Chloe Gerritson

SPECIES

Feline

BREED

DSH

SEX

Spayed Female

AGE

15 years

WEIGHT

5.5 lbs

INTERPRETED BY

Andrea Nicastro, DVM,
Diplomate ACVIM (*Small Animal Internal Medicine*)

IMAGING PERFORMED BY

Shari Reffi, CVT

HOSPITAL NAME

Newton VH

REFERRING VET

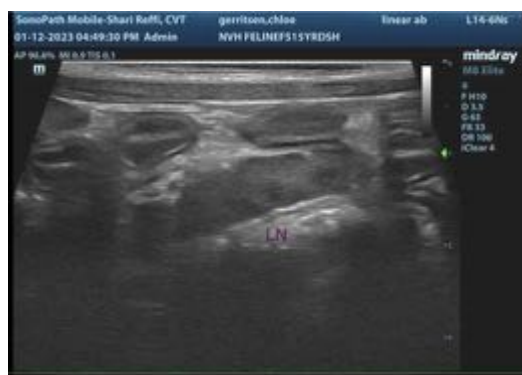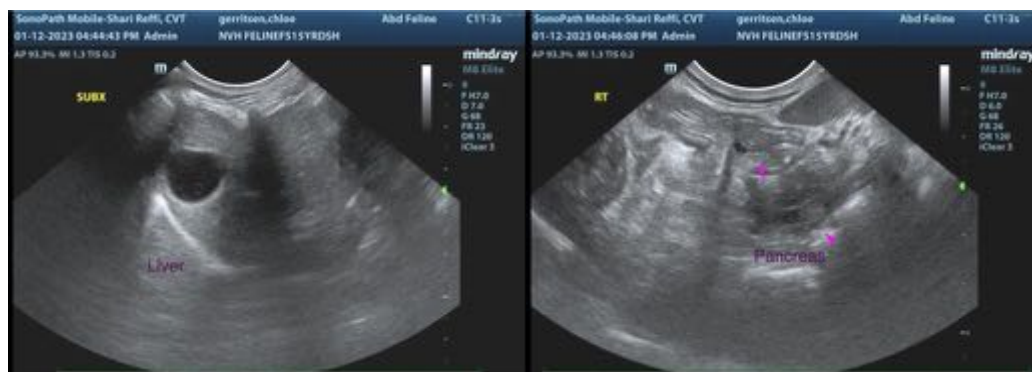
Dr. Kim

INVOICE

12038

DATE

1.12.23



The information and recommendations provided are based on the images presented by the referring veterinarian/sonographer. No evaluation can be communicated regarding pathology that was not visible in the image/video clips provided.

Thank you for this referral. If the clinical or image interpretation does not parallel your findings or if I can be of any further assistance, please contact me.

Andrea Nicastro, DVM, Diplomate DACVIM (Small Animal Internal Medicine)
info@SonoPath.com