



PATIENT

Max Echevarria

SPECIES

Canine

BREED

Terrier

SEX

Neutered Male

AGE

13 Years

WEIGHT

11.8 Lbs.

INTERPRETED BY

Andrea Nicastro, DMV,
Diplomate DACVIM
(Small Animal
Internal Medicine)

**IMAGING
PERFORMED BY**

Kelly Vazquez

HOSPITAL NAME

Animal General on
Hudson

REFERRING VET

Dr. Vivian Ng

INVOICE

13393

DATE

1/12/22

PRESENTING CLINICAL SIGNS

History: Prior elevation in liver enzymes (ALT127, ALP 149), recheck 1 month later - ALT WNL, ALP 148. Grade 3/6 heart murmur, last echo performed on 6/2/2021. Current meds: Denamarin and Cosequin.

ULTRASONOGRAPHIC EXAMINATION OF THE ABDOMEN

Urinary System

The urinary bladder and visible portion of the pelvic urethra are normal for the degree of luminal distension. The urine is anechoic with no evidence of debris. Cystic calculi and discrete masses are not observed. The region of the trigone is normal.

The prostate is normal in size (0.65 cm in width) and shape. Parenchyma is homogenous. The prostatic urethra appears normal without evidence of dilation or obstruction.

The left kidney presented normal size (4.04 cm in length); normal shape and architecture with smooth peripheral margins. There is a normal 1:3 cortex to medulla ratio with minimal to mild loss of corticomedullary distinction. There is no evidence of pyelectasia, nephroliths, infarcts or hydronephrosis. Renal vasculature is normal.

The right kidney presented normal size (3.48 cm in length); normal shape and architecture with smooth peripheral margins. There is a normal 1:3 cortex to medulla ratio with normal corticomedullary distinction. There is no evidence of pyelectasia, nephroliths, infarcts or hydronephrosis. Renal vasculature is normal.

Adrenal Glands

The left adrenal gland is normal size (0.41 cm at cranial pole) (0.53 cm at caudal pole) (1.31 cm in length); normal shape; homogenous parenchyma. The glandular echogenicity and detail are unremarkable. Capsule, cortex, and medullary definition are normal. The phrenicoabdominal vein and surrounding vasculature are normal.

The right adrenal gland is normal size (0.94 cm at cranial pole) (0.51 cm at caudal pole) (1.53 cm in length); normal shape; homogenous parenchyma. The glandular echogenicity and detail are unremarkable. Capsule, cortex, and medullary definition are normal. The phrenicoabdominal vein and surrounding vasculature are normal.

Spleen

The spleen is normal in size (1.11 cm in width at the level of the hilus) with a normal capsular contour. The parenchyma is slightly mottled appearance. No focal lesions are observed. Splenic vasculature is normal.

Liver

The liver is subjectively prominent in size with slightly swollen peripheral contours. The parenchyma is isoechoic relative to the spleen and subtly mottled in appearance. No distinct focal lesions are observed. Hepatic vasculature and intrahepatic biliary tracts are of normal volume with no evidence of congestion.

The gall bladder lumen is moderately distended. The wall is normal in thickness. A few polypoid like lesions are arising from the luminal surface. Luminal contents are otherwise anechoic. The cystic and



PATIENT common bile ducts are normal/not seen.

Max Echevarria

Gastrointestinal

SPECIES

Canine

The gastric wall is normal to mildly thickened (up to 0.55 cm) with apparent retention of the normal layering pattern. The gastric lumen is not dilated. The pyloric outflow tract is patent. The small intestinal lumen is not distended. The small intestinal wall thickness is normal with a normal layering pattern and appropriate mural detail. Discreet masses are not identified. The colonic wall is normal. No obstructive or overt infiltrative disease is noted.

BREED

Terrier

Pancreas

The left limb of the pancreas is prominent in size with minimal deviation from the normal peripheral contours. The parenchyma is hypoechoic relative to surrounding omental fat. No distinct focal lesions are observed. The pancreatic duct is not overtly dilated. The mesentery effacing the serosal surface is slightly hyperechoic.

SEX

Neutered Male

Free Abdomen

There is no evidence of free fluid. The abdominal lymph nodes are normal/not visible.

AGE

13 Years

ULTRASONOGRAPHIC FINDINGS

WEIGHT

11.8 Lbs.

Primary Findings

- Nonspecific diffuse hepatopathy. A benign process (i.e., regenerative nodular hyperplasia, vacuolar hepatopathy, age-related remodeling) is suspected given the now normal ALT. However, a low-grade inflammatory process, hepatotoxicosis or other hepatopathy cannot be completely excluded.
- The pancreatic changes are consistent with chronic +/- active pancreatitis

INTERPRETED BY

Andrea Nicastro, DMV,
Diplomate DACVIM
(Small Animal
Internal Medicine)

Secondary Findings

- Bilateral nonspecific age-related renal changes
- The mild gastric wall thickening may represent a low-grade inflammatory process or may be a normal variant for this patient. Emerging neoplasia is possible but considered less likely.
- The diffuse splenic changes are non-specific and could be consistent with lymphoid hyperplasia, extramedullary hematopoiesis, infiltrative neoplasia (less likely), other.

IMAGING PERFORMED BY

Kelly Vazquez

HOSPITAL NAME

Animal General on
Hudson

REFERRING VET

Dr. Vivian Ng

- If an aggressive approach is desired, hepatic tissue sampling (i.e., fine needle aspirate or surgical biopsy) can be considered, if clotting status is appropriate.

INVOICE

13393

- If a more conservative approach is to be pursued, serial monitoring (i.e., every 3-4 months) of the patient's liver values is recommended. If values continue to increase, a repeat abdominal ultrasound +/- hepatic tissue sampling may be warranted.

DATE

1/12/22

- Pre- and postprandial serum bile acids can also be performed to assess hepatic function.



PATIENT

Max Echevarria

SPECIES

Canine

BREED

Terrier

SEX

Neutered Male

AGE

13 Years

WEIGHT

11.8 Lbs.

INTERPRETED BY

Andrea Nicastro, DMV,
Diplomate DACVIM
(Small Animal
Internal Medicine)

IMAGING PERFORMED BY

Kelly Vazquez

HOSPITAL NAME

Animal General on
Hudson

REFERRING VET

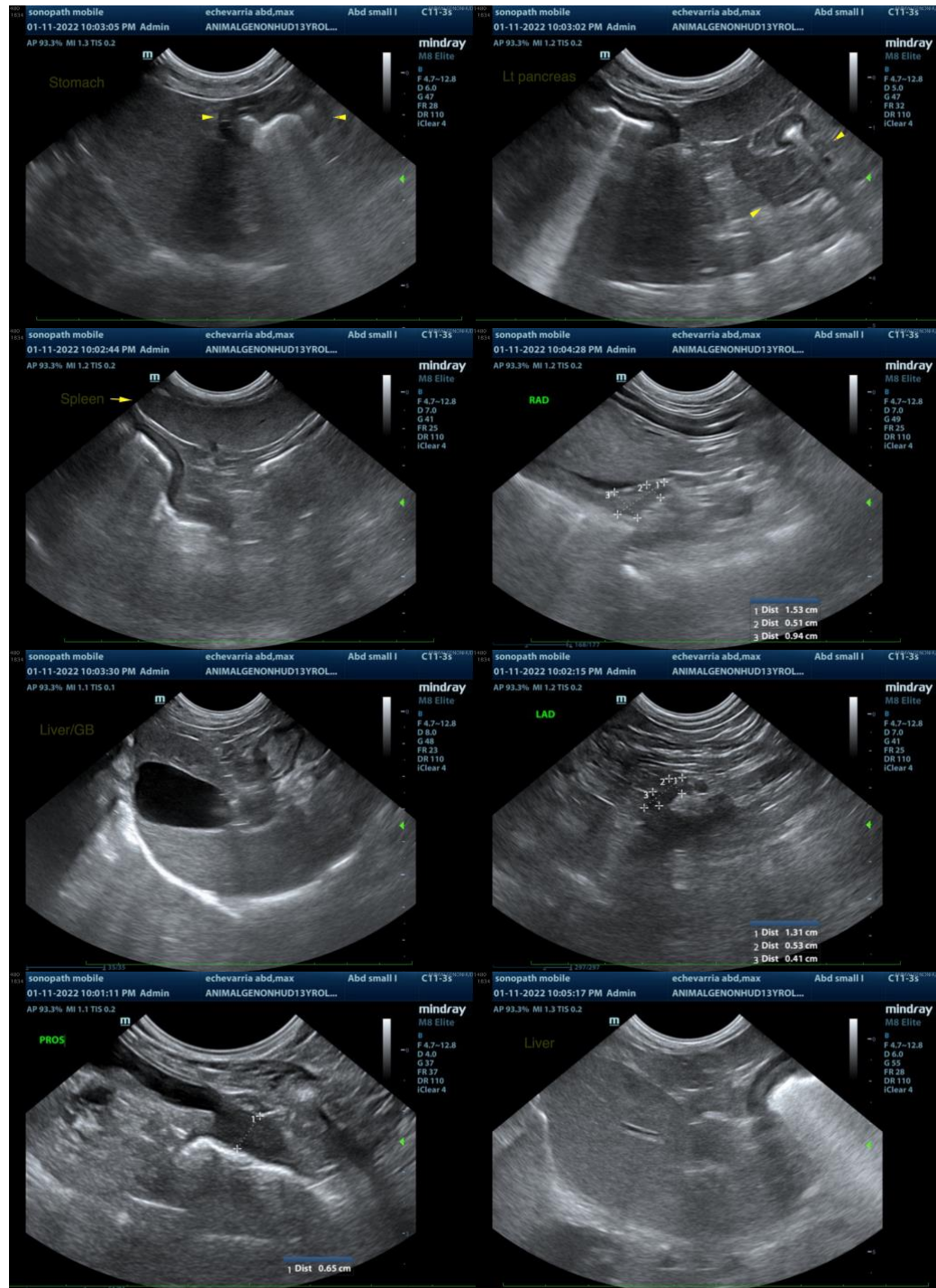
Dr. Vivian Ng

INVOICE

13393

DATE

1/12/22





PATIENT

Max Echevarria

SPECIES

Canine

BREED

Terrier

SEX

Neutered Male

AGE

13 Years

WEIGHT

11.8 Lbs.

INTERPRETED BY

Andrea Nicastro, DMV,
Diplomate DACVIM
(Small Animal
Internal Medicine)

**IMAGING
PERFORMED BY**

Kelly Vazquez

HOSPITAL NAME

Animal General on
Hudson

REFERRING VET

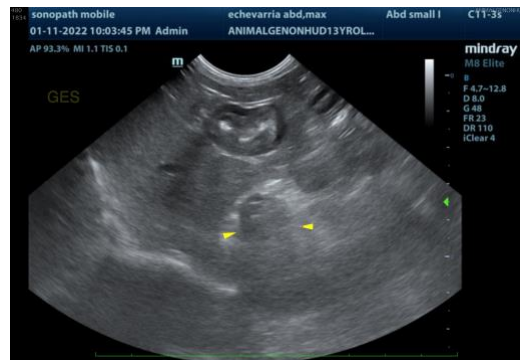
Dr. Vivian Ng

INVOICE

13393

DATE

1/12/22



The information and recommendations provided are based on the images presented by the referring veterinarian. No evaluation can be communicated regarding pathology that was not visible in the image/video clips provided.

Thank you for this referral. If the clinical or image interpretation does not parallel your findings or if I can be of any further assistance please contact me.

Andrea Nicastro, DVM, Diplomate DACVIM (Small Animal Internal Medicine)
info@SonoPath.com