



**PATIENT**

Maggie Komyati

**SPECIES**

Canine

**BREED**

Border Collie

**SEX**

Spayed Female

**AGE**

6 Years

**WEIGHT**

33.8 Lbs.

**INTERPRETED BY**

Andrea Nicastro, DMV,  
Diplomate DACVIM  
(Small Animal  
Internal Medicine)

**IMAGING  
PERFORMED BY**

Kelly Vazquez

**HOSPITAL NAME**

Animal General on  
Hudson

**REFERRING VET**

Dr. Vivian Ng

**INVOICE**

13385

**DATE**

1/12/22

**PRESENTING CLINICAL SIGNS**

History: History of intermittent vomiting, now vomiting more often. Some improvement on RC G.I. food.

Abnormal PE/Chem/CBC/UA Results: Blood work WNL.

**ULTRASONOGRAPHIC EXAMINATION OF THE ABDOMEN**

**Urinary System**

The urinary bladder, trigone, and pelvic urethra are normal in thickness and the mucosal surface is smooth. The bladder lumen is moderately distended with anechoic urine. No masses, inflammatory changes or calculi are observed. Ureteral papillae and visualized portion of the proximal urethra, visible to a depth of 2 cm, are normal.

The left kidney presented normal size (5.23 cm in length); normal shape and architecture with smooth peripheral margins. There is a normal 1:3 cortex to medulla ratio with normal corticomedullary distinction. There is no evidence of pyelectasia, nephroliths, infarcts or hydronephrosis. Renal vasculature is normal.

The right kidney presented normal size (4.82 cm in length); normal shape and architecture with smooth peripheral margins. There is a normal 1:3 cortex to medulla ratio with normal corticomedullary distinction. There is no evidence of pyelectasia, nephroliths, infarcts or hydronephrosis. Renal vasculature is normal.

**Adrenal Glands**

The left adrenal gland is normal size (0.63 cm at cranial pole) (0.51 cm at caudal pole) (1.77 cm in length); normal shape; homogenous parenchyma. The glandular echogenicity and detail are unremarkable. Capsule, cortex, and medullary definition are normal. The phrenicoabdominal vein and surrounding vasculature are normal.

The right adrenal gland is normal size (0.93 cm at cranial pole) (0.72 cm at caudal pole) (2.27 cm in length); normal shape; homogenous parenchyma. The glandular echogenicity and detail are unremarkable. Capsule, cortex, and medullary definition are normal. The phrenicoabdominal vein and surrounding vasculature are normal.

**Spleen**

The spleen is normal in size (1.65 in width at the level of the hilus) with a normal capsular contour. There is appropriate echogenicity and echotexture. No focal lesions are observed. Splenic vasculature is normal.

**Liver**

The liver is subjectively normal in size with normal contours and structure. There is appropriate echogenicity and echotexture. No overt structural evidence of inflammatory, infiltrative or regenerative pathology is evident. Vascular and biliary tracts are of normal volume with no evidence of congestion. No pathological hepatic lymphadenopathy observed.

The gall bladder is of normal contours and contains some gravity dependent echogenic debris. The wall is normal in thickness. No choleliths are observed. The cystic and common bile ducts are normal/not seen.



**PATIENT**

Maggie Komyati

**SPECIES**

Canine

**BREED**

Border Collie

**SEX**

Spayed Female

**AGE**

6 Years

**WEIGHT**

33.8 Lbs.

**INTERPRETED BY**

Andrea Nicastro, DMV,  
Diplomate DACVIM  
(Small Animal  
Internal Medicine)

**IMAGING  
PERFORMED BY**

Kelly Vazquez

**HOSPITAL NAME**

Animal General on  
Hudson

**REFERRING VET**

Dr. Vivian Ng

**INVOICE**

13385

**DATE**

1/12/22

***Gastrointestinal***

The gastric lumen is mildly distended with ingesta and chyme. The gastric wall is normal in thickness with a normal layering pattern. The small intestinal lumen is not dilated. The small intestinal wall thickness is normal with a normal layering pattern and appropriate mural detail. Discreet masses are not identified. The colonic wall is normal. The lumen of the descending colon contains shadowing fecal material. There is no obvious evidence of an obstructive pattern.

***Pancreas***

The region of the pancreas is isoechoic relative to surrounding omental fat. No obvious parenchymal abnormalities are observed. There is no evidence of regional inflammation or effusion.

***Free Abdomen***

The peritoneal cavity is normal. There is no evidence of inflammation or effusion. The abdominal lymph nodes are normal/not visible.

**ULTRASONOGRAPHIC FINDINGS**

- Some retained gastric ingesta without obvious evidence of a foreign body.
- The remainder of the abdomen is unremarkable.

\*An obvious cause for the patient's clinical signs is not identified in the study. Differentials include primary gastrointestinal disease (i.e., food allergy, intestinal dysbiosis, inflammatory bowel disease), low-grade pancreatitis, underlying metabolic issue, other.

**INTERPRETATION OF THE FINDINGS & FURTHER RECOMMENDATIONS**

- GI panel (send to Texas A&M)
- A resting cortisol level to screen for hypoadrenocorticism. If resting cortisol level is < 2.0 mcg/dL, an ACTH stimulation test is recommended.
- A fecal evaluation for ova/Giardia
- A 6-week limited antigen diet trial is recommended, if the patient will tolerate it.
- Three-view thoracic radiographs should be considered to evaluate for occult esophageal disease.
- Depending on the above results, endoscopic or surgical gastrointestinal biopsies may be warranted.



**PATIENT**

Maggie Komyati

**SPECIES**

Canine

**BREED**

Border Collie

**SEX**

Spayed Female

**AGE**

6 Years

**WEIGHT**

33.8 Lbs.

**INTERPRETED BY**

Andrea Nicastro, DMV,  
Diplomate DACVIM  
(Small Animal  
Internal Medicine)

**IMAGING  
PERFORMED BY**

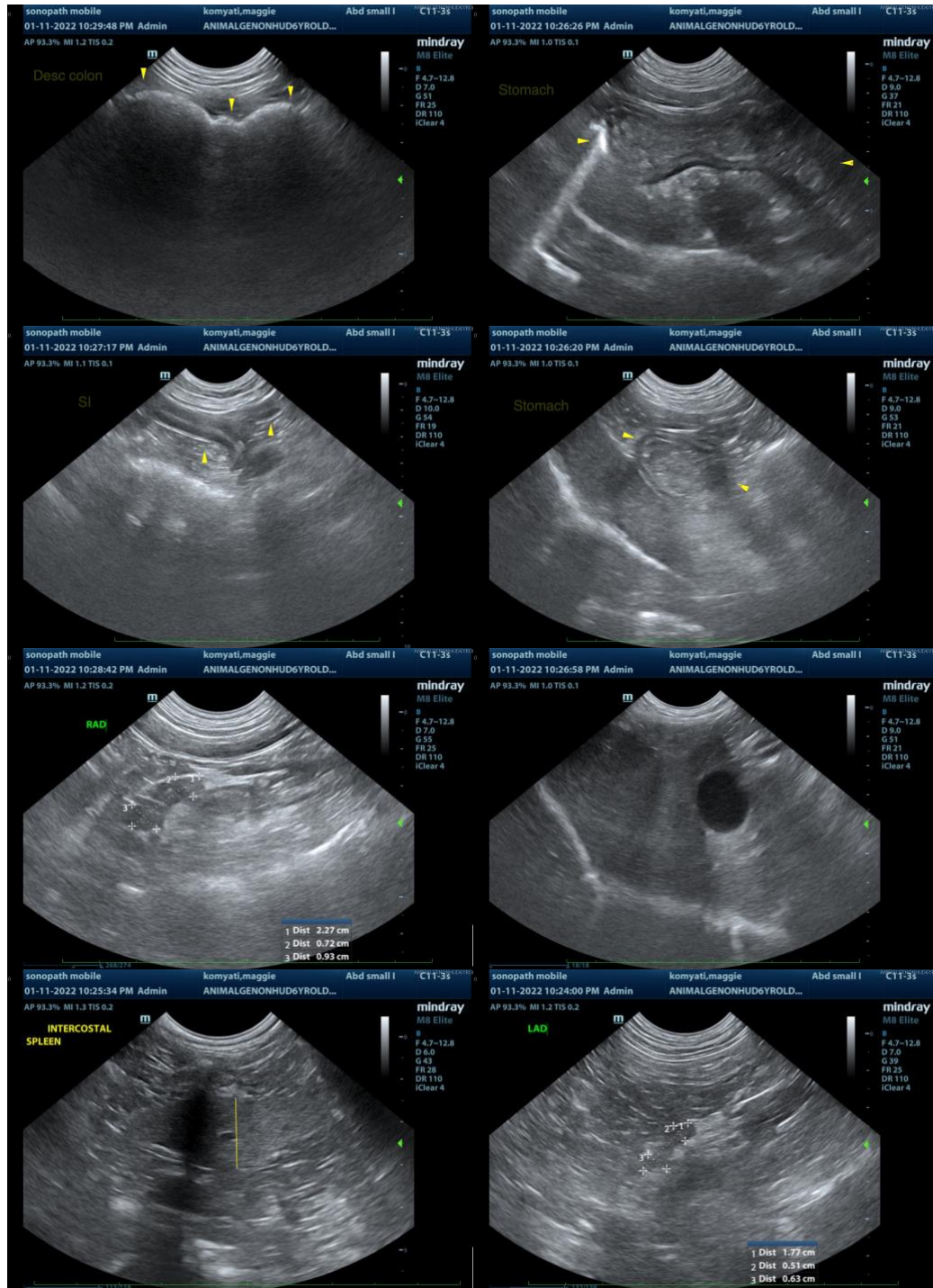
Kelly Vazquez

**HOSPITAL NAME**

Animal General on  
Hudson

**REFERRING VET**

Dr. Vivian Ng



**INVOICE**

13385

**DATE**

1/12/22



**PATIENT**

Maggie Komyati

**SPECIES**

Canine

**BREED**

Border Collie

**SEX**

Spayed Female

**AGE**

6 Years

**WEIGHT**

33.8 Lbs.

**INTERPRETED BY**

Andrea Nicastro, DMV,  
Diplomate DACVIM  
(Small Animal  
Internal Medicine)

**IMAGING  
PERFORMED BY**

Kelly Vazquez

**HOSPITAL NAME**

Animal General on  
Hudson

**REFERRING VET**

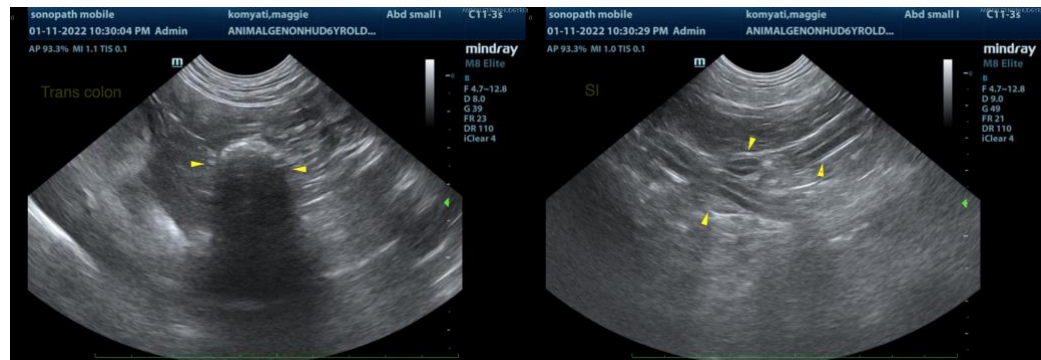
Dr. Vivian Ng

**INVOICE**

13385

**DATE**

1/12/22



The information and recommendations provided are based on the images presented by the referring veterinarian. No evaluation can be communicated regarding pathology that was not visible in the image/video clips provided.

Thank you for this referral. If the clinical or image interpretation does not parallel your findings or if I can be of any further assistance please contact me.

**Andrea Nicastro**, DVM, Diplomate DACVIM (Small Animal Internal Medicine)  
info@SonoPath.com