**DATE PRESENTING CLINICAL SIGNS**

1/11/23

Decreased appetite and lethargic. Exam: pale mm's, abdominal distension. aFAST showed multiple cavitated splenic masses. No gross free fluid. Unable to visualize liver well.

**PATIENT**

Molly Moskunas

Current Medications: None.

Lab Results: Anemia, microcytic and regenerative.

Radiographs: aFAST showed multiple cavitated splenic masses. No gross free fluid. Unable to visualize liver well. Initial thx rads look good; radiologist interpretation pending.

**SPECIES**

Canine

Date of Previous IntraPet Ultrasound: No previous.

Sedation: Not required to complete full diagnostic ultrasound.

Stat Report: Not requested.

Imaging Performed By: Andi Parkinson, BS, RDMS.

**BREED**

Labrador mix

**ULTRASONOGRAPHIC EXAMINATION OF THE ABDOMEN****Urinary System**

The urinary bladder wall is normal in thickness and the mucosal surface is smooth. The bladder lumen is moderately distended with anechoic urine. No masses, inflammatory changes or calculi are observed. Ureteral papillae and visualized portion of the proximal urethra, visible to a depth of 2 cm, are normal.

**AGE**

12/13/2013

The left kidney is normal in size (6.65 cm in length) with a normal shape, smooth peripheral margins and normal internal architecture. There is minimal loss of corticomedullary distinction. Several hyperechoic shadowing diverticular foci are observed. There is no evidence of pyelectasia, infarcts or hydronephrosis. Renal vasculature is normal.

**WEIGHT**

58 lbs.

The right kidney is normal size (6.43 cm in length) with a normal shape, smooth peripheral margins and normal internal architecture. There is minimal loss of corticomedullary distinction. Several hyperechoic shadowing diverticular foci are observed. There is no evidence of pyelectasia, infarcts or hydronephrosis. Renal vasculature is normal.

**INTERPRETED BY**

Andrea Nicastro, DVM,  
Diplomate ACVIM  
(*Small Animal Internal  
Medicine*)

**Adrenal Glands**

The left adrenal gland is normal size (0.65 cm at cranial pole) (0.66 cm at caudal pole) (2.37 cm in length); normal shape; homogenous parenchyma. The glandular echogenicity and detail are unremarkable. Capsule, cortex, and medullary definition are normal. The phrenicoabdominal vein and surrounding vasculature are normal.

**HOSPITAL NAME**

Perry Hall AH

The right adrenal gland is normal size (0.95 cm at cranial pole) (0.70 cm at caudal pole) (2.13 cm in length); normal shape; homogenous parenchyma. The glandular echogenicity and detail are unremarkable. Capsule, cortex, and medullary definition are normal. The phrenicoabdominal vein and surrounding vasculature are normal.

**REFERRING VET**

Dr. Hatzigiannakis

**Spleen**

The spleen is enlarged with irregular peripheral contours. Multiple heterogeneous cavitated, sometimes coalescing masses are observed through the organ. Splenic vasculature appears normal with no evidence of thrombosis. The mesentery surrounding the spleen is mildly hyperechoic.

**INVOICE**

14429

**Liver**

The liver is subjectively normal in size with curvilinear peripheral contours. The parenchyma is of appropriate echogenicity and echotexture. A 0.96 x 0.68 cm hyperechoic nodule is observed deep on the left side. Vascular and biliary tracts are of normal volume with no evidence of congestion. The gall bladder lumen is moderately distended. The wall is thin and smooth. A small to moderate amount of mostly gravity-dependent echogenic debris/sludge is observed within the lumen. The cystic and common bile ducts are normal/not seen.

### ***Gastrointestinal***

The gastric lumen is not distended. The gastric wall is normal in thickness with a normal layering pattern. The small intestinal lumen is not dilated. The small intestinal wall thickness is normal with a normal layering pattern and appropriate mural detail. Discreet masses are not identified. The colonic wall is normal. There is no evidence of an obstructive pattern.

### ***Pancreas***

A portion of the pancreas is obscured by the splenic pathology. In the visualized portion, no obvious abnormalities are seen.

### ***Free Abdomen***

Trace free fluid is observed. The abdominal lymph nodes are normal/not visible.

### ***Other***

A brief echocardiogram reveals no obvious evidence of pericardial effusion.

## **ULTRASONOGRAPHIC FINDINGS**

### **Primary Findings:**

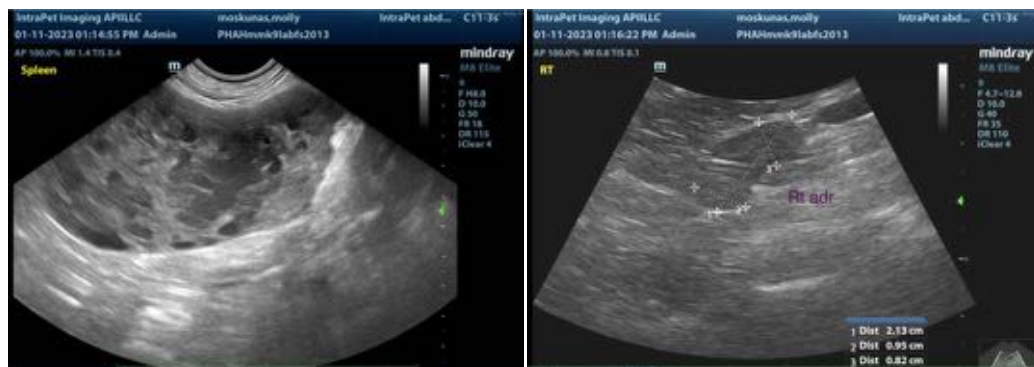- Multiple cavitated splenic masses. Neoplasia (i.e., hemangiosarcoma, hemangioma) is considered likely. Adjacent peritonitis is present. The trace free fluid is likely secondary to splenic pathology.

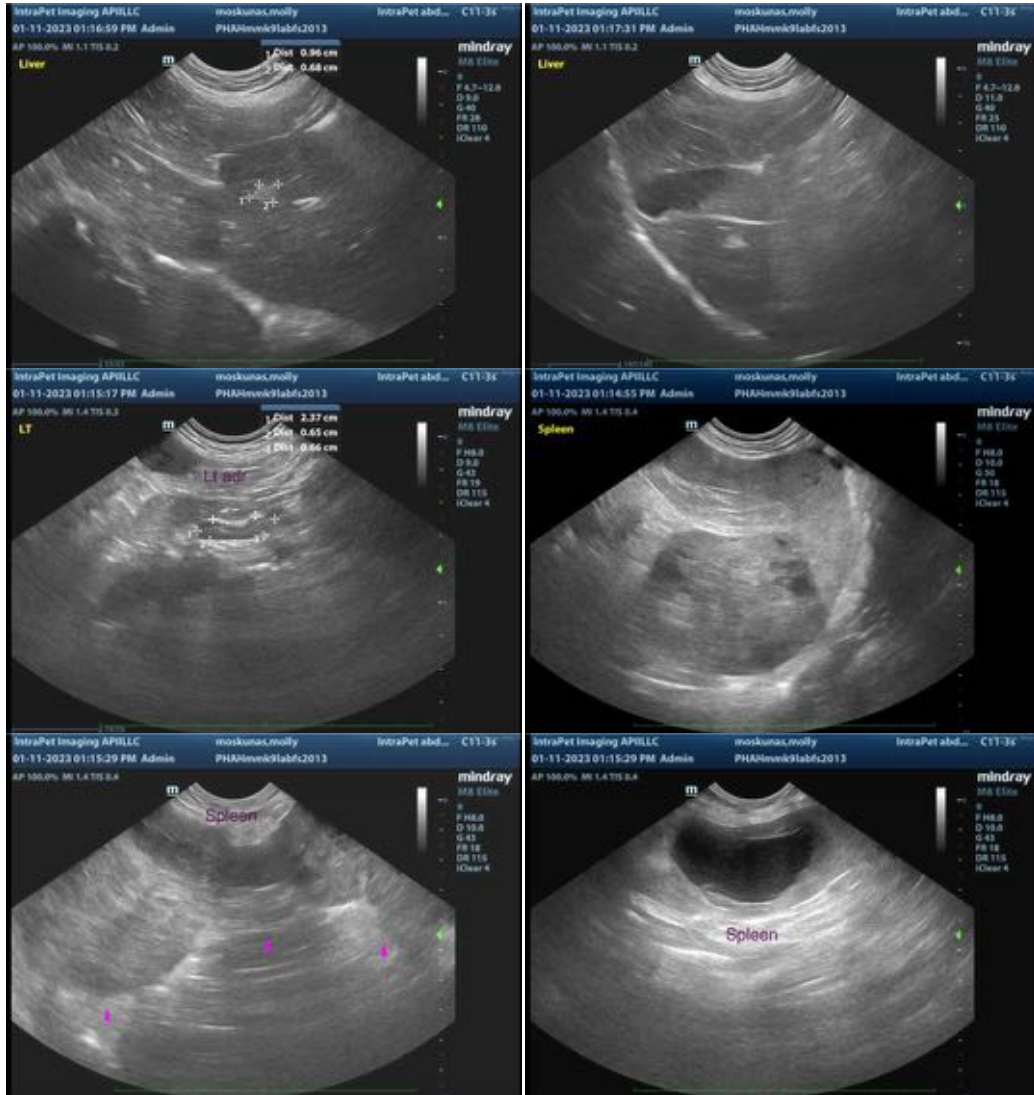
### **Secondary Findings:**

- Minor bilateral, age-related renal changes with subtle dystrophic mineralization.
- The hyperechoic hepatic nodule trends toward the benign (i.e., regenerative nodule) with a lower possibility of a neoplastic process.

## **INTERPRETATION OF THE FINDINGS & FURTHER RECOMMENDATIONS**

- Three-view thoracic radiographs are recommended to assess for pulmonary metastases.
- If there is no evidence of pulmonary metastatic disease, consider a splenectomy with submission of the spleen for histopathology. A liver biopsy should also be obtained at the time of surgery to assess for micro-metastatic disease.





The information and recommendations provided are based on the images presented by the referring veterinarian. No evaluation can be communicated regarding pathology that was not visible in the image/video clips provided.

Thank you for this referral. If the clinical or image interpretation does not parallel your findings or if I can be of any further assistance please contact me.

Andrea Nicastro, MPH, DVM, Diplomate DACVIM (Small Animal Internal Medicine)  
 info@SonoPath.com