

**DATE PRESENTING CLINICAL SIGNS**

1/10/2022

History: Inappetence, much decreased appetite x 5 days. Hx of large section of jejunal bowel resection as puppy so has controlled short bowel syndrome. Can be gassy. No improvement with Cerenia or bland diet.

**PATIENT**

Ben Brinn

Current Medications: Zonisamide seizure control.  
 Date of Previous IntraPet Ultrasound: 12-1-20 (Echo).  
 Sedation: Not required to complete full diagnostic ultrasound.  
 Stat Report: Not requested.  
 Imaging Performed By: Stephanie Pearce RDCS, RVT.

**SPECIES**

Canine

**BREED**

Labrador Retriever

**SEX**

Male, neutered

**AGE**

7/27/2009

**WEIGHT**

75 lbs.

**ULTRASONOGRAPHIC EXAMINATION OF THE ABDOMEN****Urinary System**

The urinary bladder, trigone, and pelvic urethra are normal in thickness and the mucosal surface is smooth. The bladder lumen is moderately distended with anechoic urine. No masses, inflammatory changes or calculi are observed. Ureteral papillae and visualized portion of the proximal urethra, visible to a depth of 2 cm, are normal.

The prostate is normal in size and shape. Parenchyma is homogenous. The prostatic urethra appears normal without evidence of dilation or obstruction.

The left kidney is normal size (6.55 cm in length); normal shape and architecture with smooth peripheral margins. There is a normal 1:3 cortex to medulla ratio with normal corticomedullary distinction. There is no evidence of pyelectasia, nephroliths, infarcts or hydroureter. Renal vasculature is normal.

The right kidney is normal size (7.14 cm in length); normal shape and architecture with smooth peripheral margins. There is a normal 1:3 cortex to medulla ratio with normal corticomedullary distinction. There is no evidence of pyelectasia, nephroliths, infarcts or hydroureter. Renal vasculature is normal.

**INTERPRETED BY**

Andrea Nicastro, DVM,  
 Diplomate ACVIM  
 (Small Animal Internal  
 Medicine)

**Adrenal Glands**

The left adrenal gland is normal size (0.70 cm at cranial pole) (0.81 cm at caudal pole) (3.34 cm in length); normal shape; homogenous parenchyma. The glandular echogenicity and detail are unremarkable. Capsule, cortex, and medullary definition are normal. The phrenicoabdominal vein and surrounding vasculature are normal.

**HOSPITAL NAME**

Stay Pet Veterinary

The right adrenal gland is normal size (1.13 cm at cranial pole) (0.71 cm at caudal pole) (3.13 cm in length); normal shape; homogenous parenchyma. The glandular echogenicity and detail are unremarkable. Capsule, cortex, and medullary definition are normal. The phrenicoabdominal vein and surrounding vasculature are normal.

**REFERRING VET**

Dr. Klimovitz

**Spleen**

The spleen is subjectively normal in size (1.43 cm in width at the level of the hilus) with normal curvilinear peripheral contours. The parenchyma is subtly mottled in appearance with ill-defined hypoechoic areas throughout the organ. Splenic vasculature appears normal with no evidence of thrombosis.

**INVOICE**

12807

**Liver**

The liver is subjectively normal in size with normal curvilinear peripheral contours. The parenchyma is hypoechoic relative to the spleen with minor changes consistent with age-related remodeling. No focal lesions are observed. Hepatic vasculature and biliary tracts are of normal volume with no evidence of congestion. The gall bladder lumen is moderately distended. The wall is thin and smooth. Luminal contents are anechoic. The cystic and common bile ducts are normal/not seen.

### ***Gastrointestinal***

The gastric lumen distended with gas and a small amount of fluid. The gastric wall is normal in thickness with a normal layering pattern. The small intestinal lumen is segmentally dilated with chyme. The small intestinal wall thickness is normal with a normal layering pattern and appropriate mural detail. Discreet masses are not identified. The colonic wall is normal. No obstructive disease is noted.

### ***Pancreas***

The region of the pancreas is isoechoic relative to surrounding omental fat. No obvious parenchymal abnormalities are observed. There is no evidence of regional inflammation or effusion.

### ***Free Abdomen***

The peritoneal cavity is normal. There is no evidence of inflammation or effusion. 2-3 prominent mesenteric lymph nodes are visualized, the largest measuring 3.1 cm in length. The nodes are normal in shape and echogenicity.

### ***Other***

A brief echocardiogram reveals no evidence of pericardial effusion or obvious right atrial/auricular mass.

## **ULTRASONOGRAPHIC FINDINGS**

### **Primary Findings:**

- The splenic parenchymal changes could be consistent with a benign process (i.e., lymphoid hyperplasia or extramedullary hematopoiesis). Alternatively, infiltrative neoplasia (i.e., lymphoma) is possible.

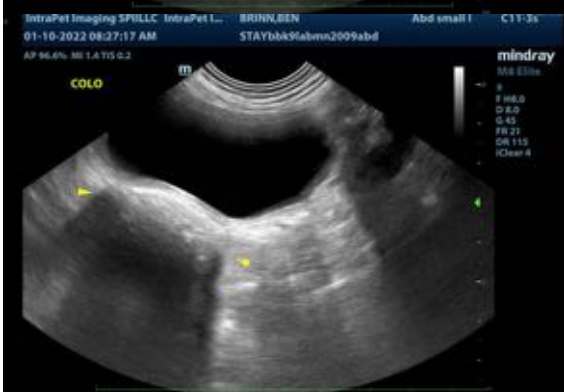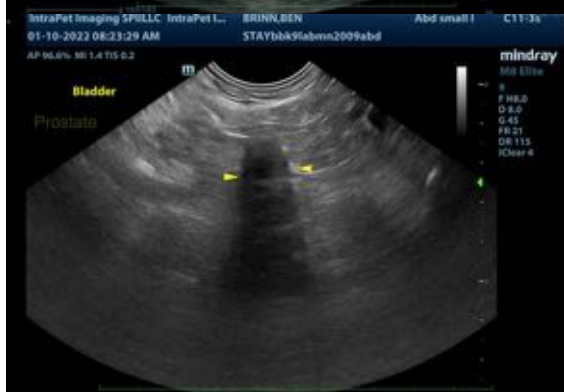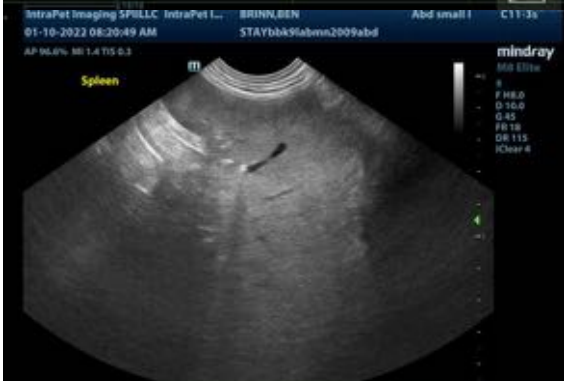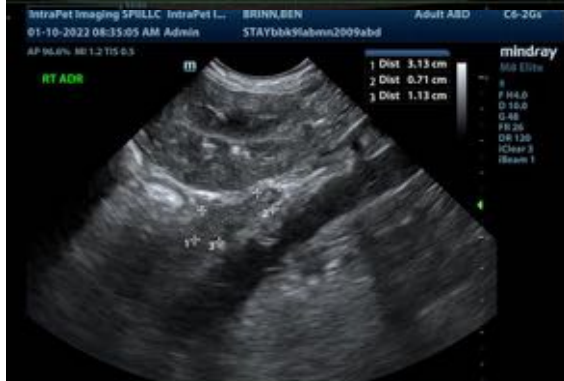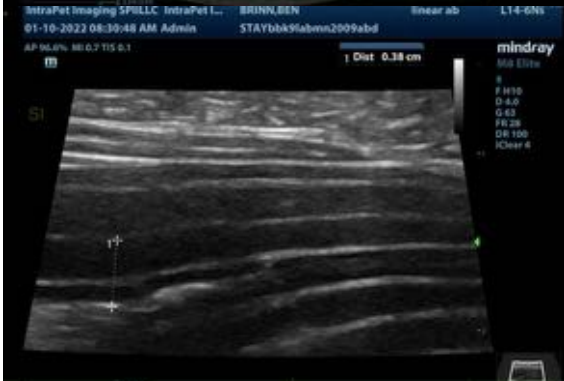
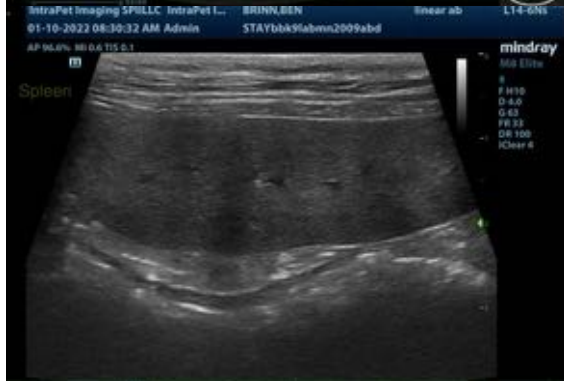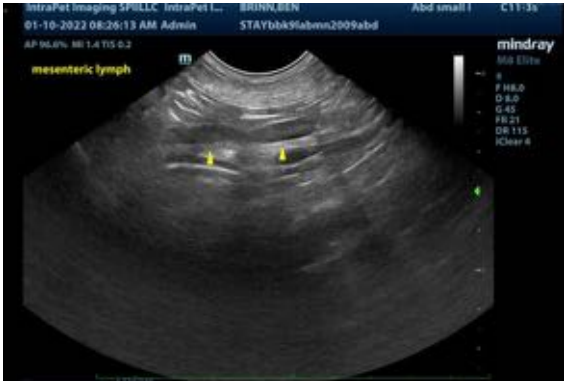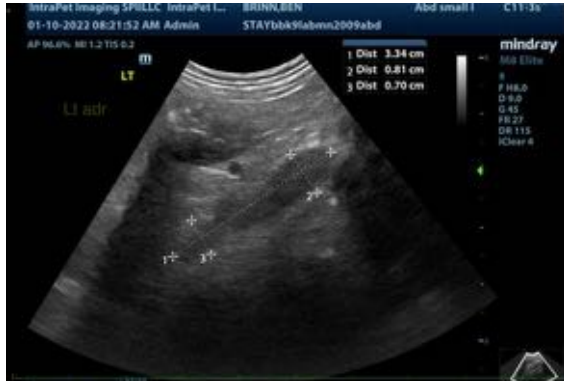### **Secondary Findings:**

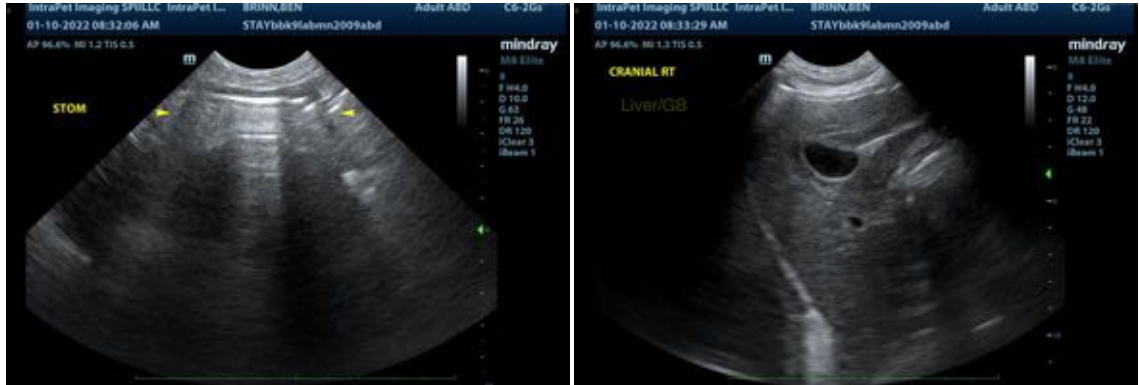- The hepatic changes are consistent with age-related parenchymal remodeling and are not considered clinically significant at this time.
- The lymph node changes are most consistent with reactive lymphadenitis or lymphoid hyperplasia.

\*An obvious cause for the patient's clinical signs is not identified in this study.

## **INTERPRETATION OF THE FINDINGS & FURTHER RECOMMENDATIONS**

- Three-view thoracic radiographs are recommended to assess for occult disease in the chest.
- Consider a fine needle aspirate of the spleen (if clotting status is appropriate) to rule out round cell neoplasia.
- Baseline labwork including a CBC chemistry panel, urinalysis and T4 is recommended, if not already performed.
- Further recommendations should be based on the results of the above diagnostics.





The information and recommendations provided are based on the images presented by the referring veterinarian. No evaluation can be communicated regarding pathology that was not visible in the image/video clips provided.

Thank you for this referral. If the clinical or image interpretation does not parallel your findings or if I can be of any further assistance please contact me.

Andrea Nicastro, DVM, Diplomate ACVIM (*Small Animal Internal Medicine*)  
Andrea.nicastro@sonopath.com