

DATE PRESENTING CLINICAL SIGNS

2/4/2022

History: Freya has had a low-grade fever for the past 4 weeks and last week developed ascites that is pretty classic for FIP (seen at prev vet for that). The owners are treating her with an unnamed medication to help resolve the FIP. She presented here on Friday, 1/28, for a second opinion. She had significant ascites and a fever of 103.4. Her hct was 19%, total bili was 2.0. She re-presented on 2/2 with lethargy and mild increased respiratory effort. Her hct was down to 13%, t. bili still at 2.1. Chest rads showed ascites and a pulmonary infiltrate thought to possibly be pneumonia but no/scant pleural effusion. She had 2 blood transfusions of 10ml each and hct on 2/3 was 21%. She was started on Doxycycline and Clavamox as well as Prednisolone.

SPECIES

Feline

Current Medications: unnamed FIP medication owners are giving, Doxycycline 10mg SID, Prednisolone 1.7mg BID, Clavamox 31.25mg BID.

BREED

Lab Results: Attached separately. (1/28) hct=19% non regen, neutrophils 13,870; t. bili=2.0; AST=150. (2/1) hct=13%; t. bili=2.1. (2/3) hct=21% after blood transfusion.

DSH

Radiographs: Attached separately & interpretation attached separately.

SEX

Date of Previous IntraPet Ultrasound: No previous IntraPet scans.

Female Intact

Sedation: Not required to complete full diagnostic ultrasound.

Stat Report: REQUESTED.

Imaging Performed By: Stephanie Pearce RDCS, RVT.

AGE

Patient was not fasted for the study. The referring veterinarian okayed proceeding with the scan with the patient in a non-fasted state.

10-10-2021

WEIGHT

4 Lbs.

ULTRASONOGRAPHIC EXAMINATION OF THE ABDOMEN

Urinary System

The urinary bladder, trigone, and pelvic urethra are normal in thickness and the mucosal surface is smooth. The bladder lumen is moderately distended with anechoic urine. No masses, inflammatory changes or calculi are observed. Ureteral papillae and visualized portion of the proximal urethra, visible to a depth of 2 cm, are normal.

The left kidney is normal size (3.83 cm in length); normal shape and architecture with smooth peripheral margins. There is a normal 1:3 cortex to medulla ratio with normal corticomedullary distinction. There is no evidence of pyelectasia, nephroliths, infarcts or hydroureter. Renal vasculature is normal.

The right kidney is normal size (3.68 cm in length); normal shape and architecture with smooth peripheral margins. There is a normal 1:3 cortex to medulla ratio with normal corticomedullary distinction. There is no evidence of pyelectasia, nephroliths, infarcts or hydroureter. Renal vasculature is normal.

Adrenal Glands

The left adrenal gland is normal size (0.38 cm width). Normal shape and glandular echogenicity. The phrenicoabdominal vein and surrounding vasculature are normal.

The right adrenal gland is normal size (0.39 cm width). Normal shape and glandular echogenicity. The phrenicoabdominal vein and surrounding vasculature are normal.

Spleen

The spleen is normal in size (0.57 cm in width at the level of the hilus) with a normal capsular contour. There is appropriate echogenicity and echotexture. No focal lesions are observed. Splenic vasculature is normal.

INTERPRETED BY

Andrea Nicastro, DMV,
Diplomate DACVIM
(Small Animal
Internal Medicine)

HOSPITAL NAME

Cat Sense Feline
Hospital

REFERRING VET

Dr. Sinclair

INVOICE

10272

Liver

The liver is subjectively enlarged with slightly swollen peripheral contours. The parenchyma is isoechoic relative to the spleen and diffusely homogeneous in appearance. No distinct focal lesions are observed. Vascular and biliary tracts are of normal volume with no evidence of congestion.

The gall bladder lumen is contracted. The wall is of appropriate thickness for the level of repletion. Luminal contents are not visible due to contraction. The cystic and common bile ducts are normal.

Gastrointestinal

The gastric lumen is distended with ingesta. The gastric wall and pylorus are normal in thickness with a normal layering pattern. The pyloric outflow tract is patent. The small intestinal lumen is segmentally dilated with chyme. The small intestinal wall thickness is normal with a normal layering pattern and appropriate mural detail. Discreet masses are not identified. The ileocecolic junction and colonic wall are normal. No obstructive disease is noted.

Pancreas

A portion of the pancreas is obscured by the gastric distention. In the visualized portions, no obvious pathology is seen.

Free Abdomen

A large amount of echogenic free fluid is present within the abdominal cavity. The mesentery is echogenic and wispy fiber strands are seen. The abdominal lymph nodes are normal/not visible.

Other

A brief evaluation of the thorax reveals questionable trace pleural and pericardial effusion. There is no obvious evidence of left atrial enlargement

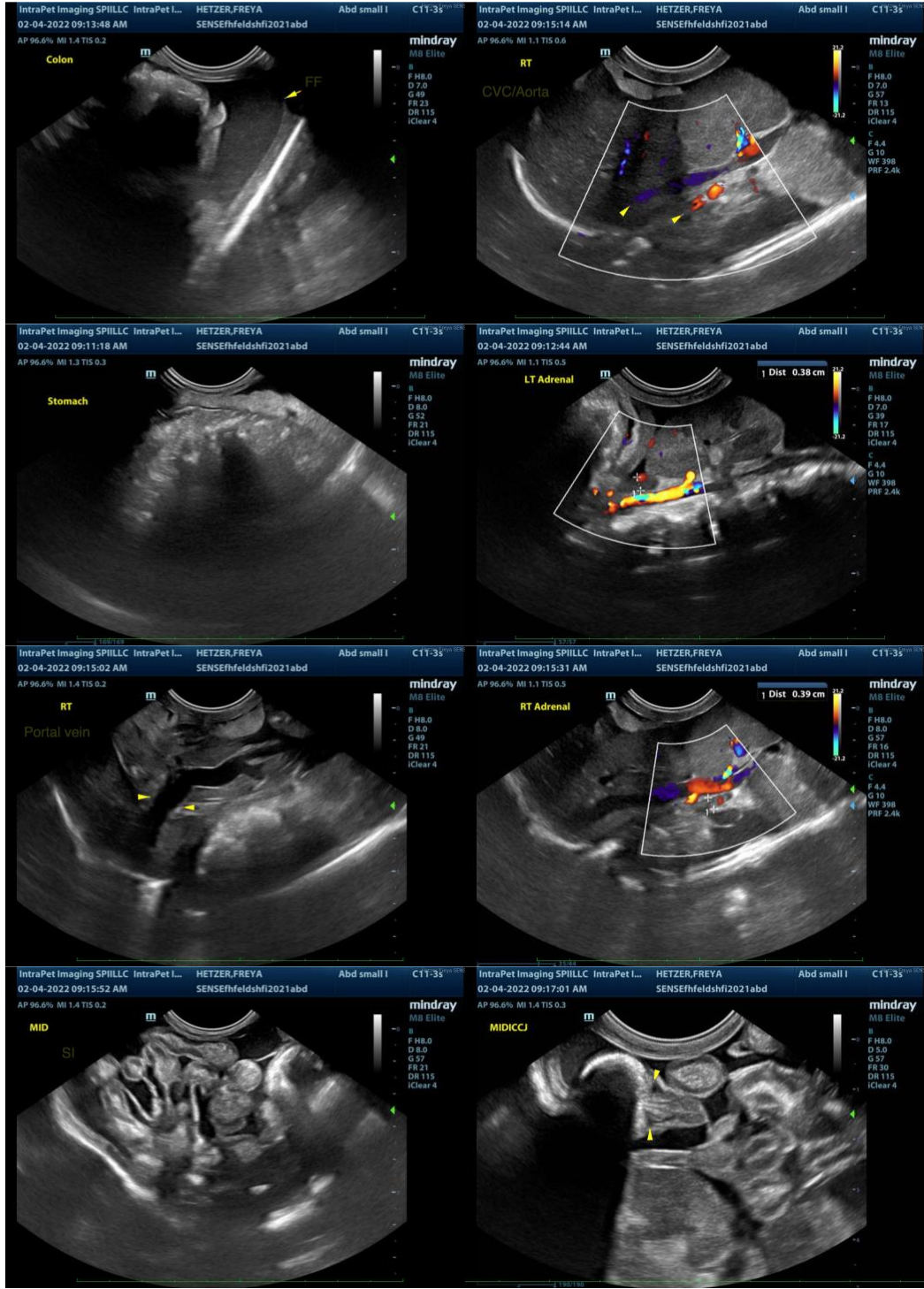
ULTRASONOGRAPHIC FINDINGS

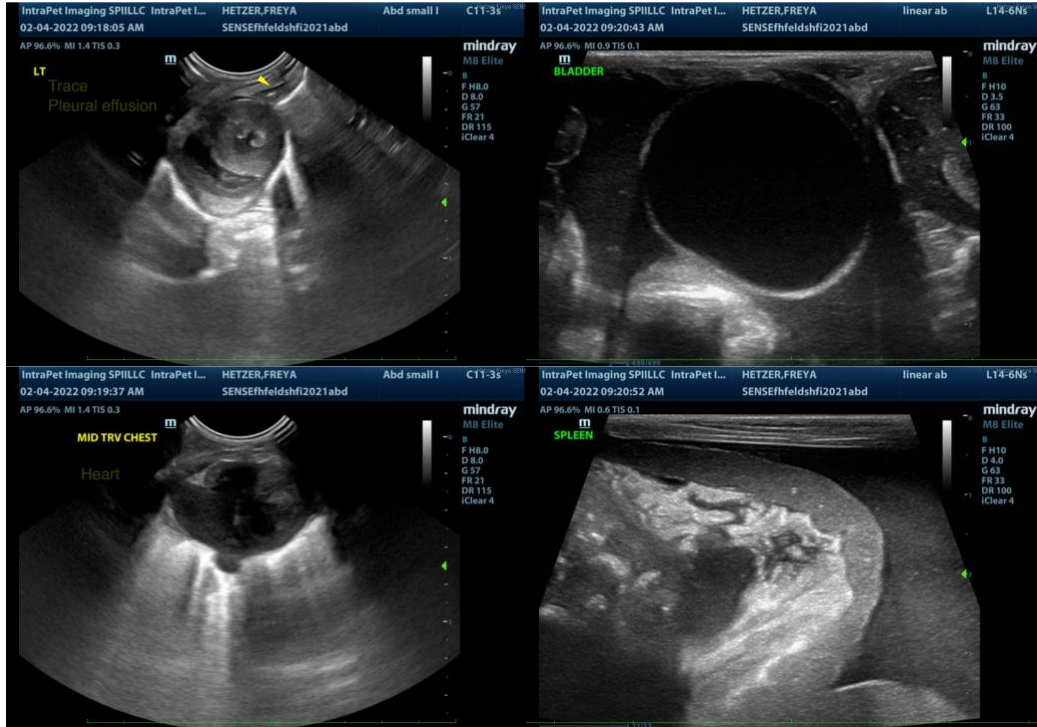
Primary Findings

- Given the patient's history and today's sonographic changes, feline infectious peritonitis remains the top differential.
- The hepatic parenchymal changes could be consistent with pyogranulomatous inflammation (i.e., secondary to FIP), other inflammatory disease, hepatic lipidosis, or other hepatopathy.

INTERPRETATION OF THE FINDINGS & FURTHER RECOMMENDATIONS

- Continued supportive care and empirical treatment for FIP is recommended. If FIP testing has not yet been performed, consider serology and/or PCR. Testing for concurrent infectious diseases (i.e., feline leukemia, FIV and Toxoplasmosis) should also be considered.
- Given the thoracic radiographic findings, empirical treatment for pneumonia +/- further testing for lungworm is recommended.





The information and recommendations provided are based on the images presented by the referring veterinarian/sonographer. No evaluation can be communicated regarding pathology that was not visible in the image/video clips provided.

Thank you for this referral. If the clinical or image interpretation does not parallel your findings or if I can be of any further assistance, please contact me.

Andrea Nicastro, DVM, Diplomate DACVIM (Small Animal Internal Medicine)
info@SonoPath.com