

**DATE PRESENTING CLINICAL SIGNS**

1/26/2022 History: Elevated ALP for 2 years. Recently significant elevated level=735. O reported more frequent vomiting/loose stool last 2 months.

PATIENT

Nick Anderson

Current Medications: Denamarin.
Date of Previous IntraPet Ultrasound: No previous IntraPet scans.
Sedation: Not required to complete full diagnostic ultrasound.
Stat Report: Not requested.

SPECIES

Canine

Imaging Performed By: Rachel Brillhart, RDMS.

ULTRASONOGRAPHIC EXAMINATION OF THE ABDOMEN**BREED**

Shih Tzu

Urinary System

The urinary bladder, trigone, and pelvic urethra are normal in thickness and the mucosal surface is smooth. The bladder lumen is moderately distended with anechoic urine. No masses, inflammatory changes or calculi are observed. Ureteral papillae and visualized portion of the proximal urethra, visible to a depth of 2 cm, are normal.

SEX

Male Neutered

The prostate is normal in size (0.82 cm in width) and shape. Parenchyma is homogenous. The prostatic urethra appears normal without evidence of dilation or obstruction.

AGE

1-17-2011

The left kidney is normal size (.4.75 cm in length); normal shape and architecture with smooth peripheral margins. The cortex is mildly thickened and there is moderate loss of corticomedullary distinction. Hyperechoic shadowing diverticular foci are visualized. There is no evidence of pyelectasia, infarcts or hydroureter. Renal vasculature is normal.

WEIGHT

19.4 Lbs.

The right kidney is normal size (4.69 cm in length); normal shape and architecture with smooth peripheral margins. The cortex is mildly thickened and there is moderate loss of corticomedullary distinction. Hyperechoic shadowing diverticular foci are visualized. There is no evidence of pyelectasia, infarcts or hydroureter. Renal vasculature is normal.

INTERPRETED BY

Andrea Nicastro, DMV,
Diplomate DACVIM
(Small Animal
Internal Medicine)

HOSPITAL NAME

Banfield Pet Hospital
of Columbia

REFERRING VET

Dr. Seon Lee

Adrenal Glands

The left adrenal gland is enlarged (1.13 cm at cranial pole) (0.69 cm at caudal pole) (2.32 cm in length); with a slightly irregular shape. A 1.40 x 1.01 cm hyperechoic to slightly heterogenous nodule is observed at the cranial aspect. The glandular echogenicity and detail at the caudal aspect are normal. Surrounding vasculature appears normal.

The right adrenal gland is enlarged (1.62 cm at cranial pole) (0.55 cm at caudal pole) (3.46 cm in length); with an irregular shape. A 2.53 x 1.50 cm hyperechoic to slightly heterogenous nodule/mass is observed in the cranial to mid-aspect. Medullar echogenicity and detail at the caudal aspect are normal. The phrenicoabdominal vein and surrounding vasculature appears normal.

Spleen**INVOICE**

10205

The spleen is subjectively normal in size (0.99 cm in width at the level of the hilus) with a normal curvilinear peripheral contours. The parenchyma is slightly mottled in appearance. Several varying-sized hyperechoic nodules are observed throughout the organ, the largest measuring 0.70 cm. Splenic vasculature appears normal with no evidence of thrombosis.

Liver

The liver is subjectively prominent in size with slightly swollen peripheral contours. The parenchyma is isoechoic relative to the spleen and mottled in appearance. No distinct focal lesions are observed. Hepatic vasculature and intrahepatic biliary tracts are of normal volume with no evidence of congestion.

The gall bladder lumen is mildly distended. The wall is thin and smooth. A small amount of aggregated echogenic debris is suspended within the lumen. The cystic and common bile ducts are normal.

Gastrointestinal

The gastric lumen is not distended. The gastric wall is borderline thickened (up to 0.48 cm) with retention of the normal layering pattern. The pyloric outflow tract is patent. The small intestinal lumen is not dilated. The small intestinal wall is normal in thickness, with a normal layering pattern. There is evidence of slight mucosal speckling in some regions. Discreet masses are not identified. The colonic wall is normal. There is no evidence of an obstructive pattern

Pancreas

The base and right limb are enlarged with slightly irregular peripheral contours. The parenchyma is hypoechoic relative to surrounding omental fat and slightly heterogenous in appearance. No distinct focal lesions are observed. The pancreatic duct is not overtly dilated. The mesentery effacing the serosal surface is subtly hyperechoic.

Free Abdomen

There is no evidence of free fluid. The abdominal lymph nodes are normal/not visible.

Other

A brief echocardiogram reveals no evidence of pericardial effusion.

ULTRASONOGRAPHIC FINDINGS

Primary Findings

- The diffuse hepatic changes are non-specific and could be consistent with vacuolar hepatopathy, regenerative nodular hyperplasia, and/or age-related remodeling. Inflammatory and infiltrative disease are considered less likely.
- Bilateral adrenal nodules/adrenomegaly. Differentials include nodular hyperplasia versus emerging tumors.
- The pancreatic changes are most consistent with chronic +/- active pancreatitis.

Secondary Findings

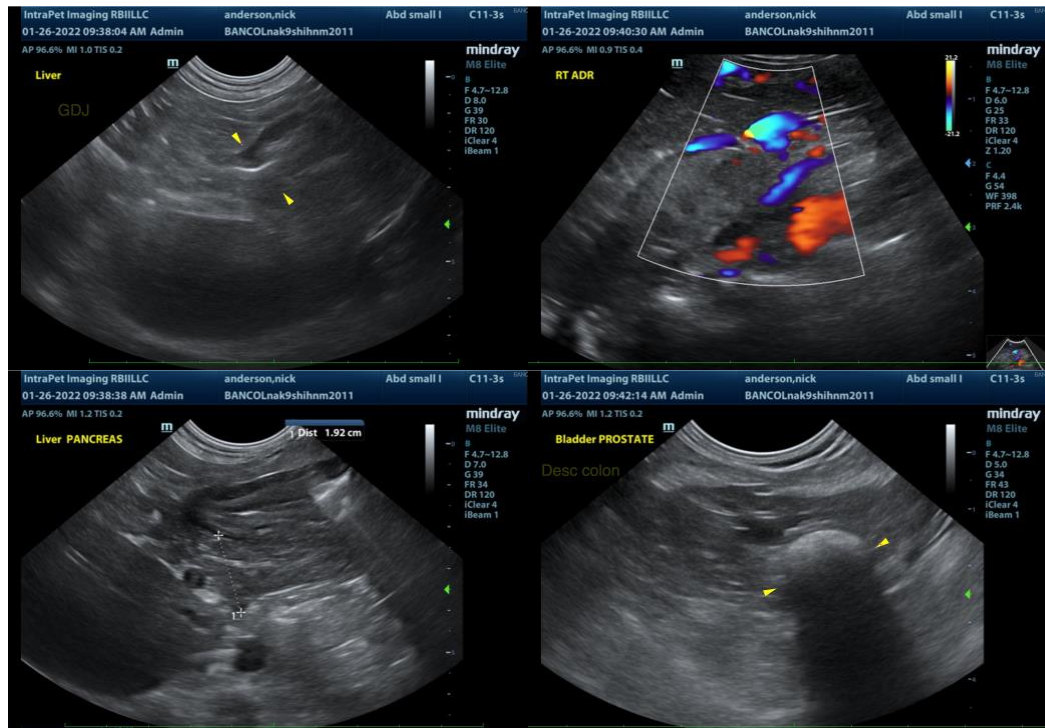
- The slight gastrointestinal mucosal speckling is sometimes seen with enteritis. Correlation with clinical findings is recommended.
- Bilateral degenerative renal changes with dystrophic mineralization.

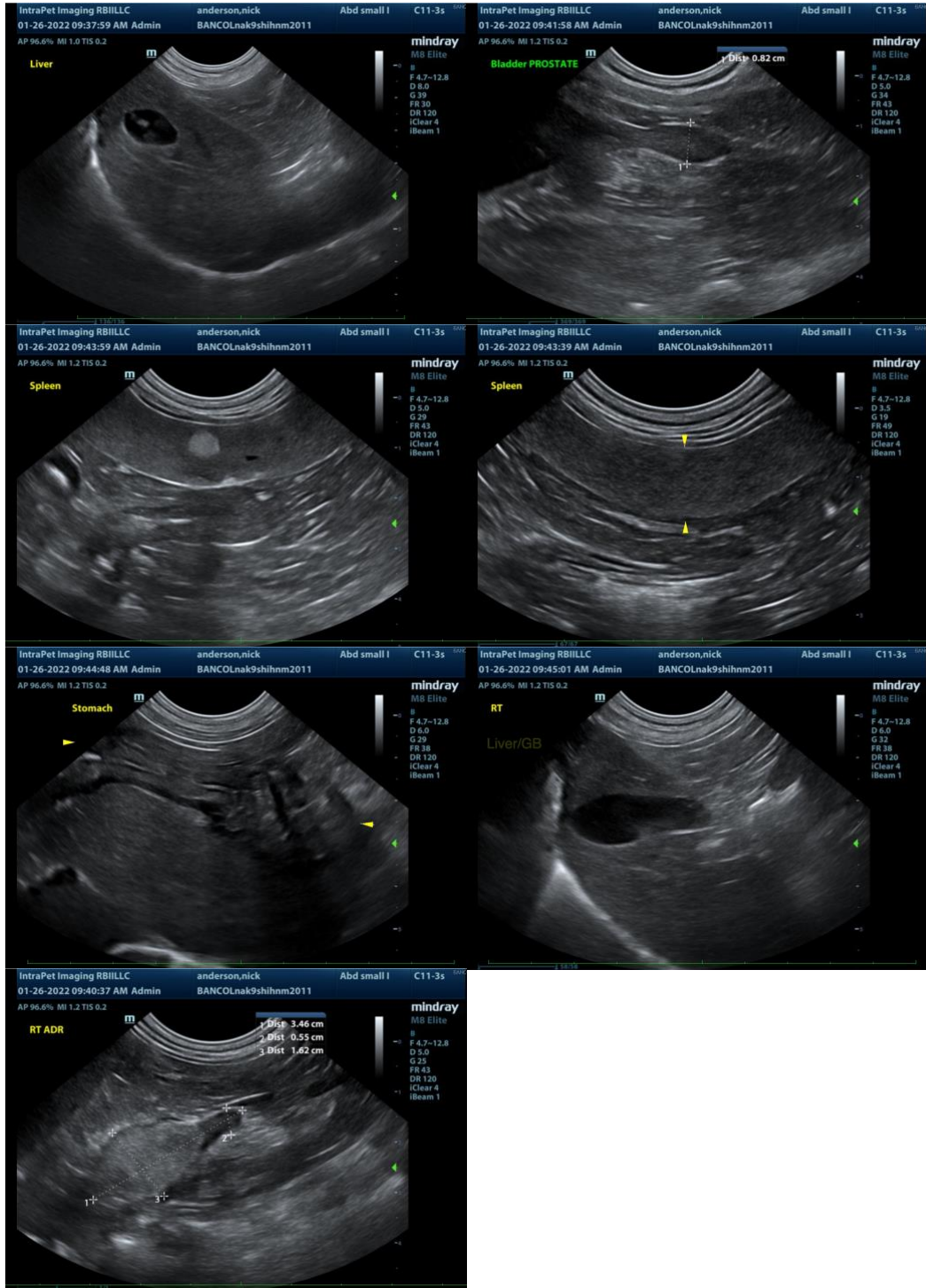
INTERPRETATION OF THE FINDINGS & FURTHER RECOMMENDATIONS

- If the patient is exhibiting clinical signs of Cushing's Disease, further testing (i.e., low-dose dexamethasone suppression test or ACTH stimulation test) may be warranted. Also consider a baseline blood pressure measurement +/- UPC (if proteinuria is present).

Regarding the GI signs, consider the following:

1. GI Panel (Send to Texas A&M)
2. Fecal evaluation for ova and Giardia
3. Prophylactic deworming with Fenbendazole at 50 mg/kg once a day for 5 days is recommended. Repeat above protocol in 3 weeks.
4. A 6-week limited antigen diet trial to assess for food allergies
5. Supportive care for pancreatitis.
6. If clinical signs do not improve and the above diagnostics are inconclusive, endoscopic or surgical gastrointestinal biopsies may be necessary to get a definitive diagnosis.
7. Given the patient's age, three-view thoracic radiographs should be performed prior to any anesthetic event.





The information and recommendations provided are based on the images presented by the referring veterinarian/sonographer. No evaluation can be communicated regarding pathology that was not visible in the image/video clips provided.

Thank you for this referral. If the clinical or image interpretation does not parallel your findings or if I can be of any further assistance, please contact me.

Andrea Nicastro, DVM, Diplomate DACVIM (Small Animal Internal Medicine)
info@SonoPath.com