

**DATE PRESENTING CLINICAL SIGNS**

1/26/2022

History: chronic hx of intermittent, but fairly consistent straining to urinate; has never fully obstructed; has been seen many times for this problem at other hospital; has had bloodwork done (wnl per owner) but never rads or UA; e/d fine but is picky; has been on Hills c/d dry for over a year; tried canned urinary diet, and he would not eat it; no v/d/c/s; indoor only; only cat; no obvious stressors for past year; 1 litter box; urinates in box; on Prazosin 0.5mg BID when seeing symptoms. Needs more prazosin; has gabapentin (to give 50mg BID) but is not giving it; has been on buprenorphine before, but not currently; was straining to urinate this morning; no blood in urine; this has been consistent per owner.

SPECIES

Feline

Current Medications: Prazosin 0.5 mg bid as needed, Gabapentin 50 mg bid as needed.

Date of Previous IntraPet Ultrasound: No previous IntraPet scans.

Sedation: Not required to complete full diagnostic ultrasound.

BREED

Ragdoll

Stat Report: Not requested.

Imaging Performed By: Rachel Brillhart, RDMS.

ULTRASONOGRAPHIC EXAMINATION OF THE ABDOMEN**SEX**

Male Neutered

Urinary System

The urinary bladder is moderately distended. The wall is normal in thickness with a smooth mucosal surface. A moderate amount of aggregated echogenic suspended debris is observed within the lumen. No cystic calculi are observed. The region of the trigone is normal. The proximal urethra is slightly dilated. The walls are normal in thickness. There is no evidence of intraluminal obstruction in the visible portion of the urethra, which can be visualized for 3-4 cm distally.

AGE

3-10-2013

WEIGHT

11.3 Lbs.

The left kidney is normal in size (4.02 cm in length); with a normal shape and architecture with smooth peripheral margins. The cortex is hyperechoic. There is a normal 1:3 cortex to medulla ratio with mild loss of corticomedullary distinction. There is no evidence of pyelectasia, nephroliths, infarcts or hydroureter. Renal vasculature is normal.

INTERPRETED BY

Andrea Nicastro, DMV,
Diplomate DACVIM
(Small Animal
Internal Medicine)

The right kidney is normal in size (4.18 cm in length); with a normal shape and architecture with smooth peripheral margins. The cortex is hyperechoic. There is a normal 1:3 cortex to medulla ratio with mild loss of corticomedullary distinction. There is no evidence of pyelectasia, nephroliths, infarcts or hydroureter. Renal vasculature is normal.

HOSPITAL NAME

Pet Vet of Clarksville

Adrenal Glands

The left adrenal gland is normal size (0.43 cm width). Normal shape and glandular echogenicity. The phrenicoabdominal vein and surrounding vasculature are normal.

REFERRING VET

Dr. Martof

The right adrenal gland is normal size (0.46 cm width). Normal shape and glandular echogenicity. The phrenicoabdominal vein and surrounding vasculature are normal.

INVOICE

10203

Spleen

The spleen is normal in size (0.48 cm in width at the level of the hilus) with a normal capsular contour. There is appropriate echogenicity and echotexture. No focal lesions are observed. Splenic vasculature is normal.

Liver

The liver is subjectively normal in size with normal contours and structure. There is appropriate echogenicity and echotexture. No overt structural evidence of inflammatory, infiltrative, or regenerative pathology is evident. Vascular and biliary tracts are of normal volume with no evidence of congestion. No pathological hepatic lymphadenopathy observed.

The gall bladder lumen is moderately distended. The wall is thin and smooth. Luminal contents are anechoic. The cystic and common bile ducts are normal.

Gastrointestinal

The gastric lumen is distended with soft shadowing material. The gastric wall and pylorus are normal in thickness with a normal layering pattern. The small intestinal lumen is not dilated. The small intestinal wall is normal to mildly thickened (up to 0.28 cm) with a normal layering pattern and appropriate mural detail. There is disruption of the normal 1:3 muscularis to mucosal ratio in most segments. Discreet masses are not identified. The ileocecolic junction and colonic wall are normal. There is no evidence of an obstructive pattern.

Pancreas

The region of the pancreas is isoechoic relative to surrounding omental fat. No obvious parenchymal abnormalities are observed. There is no evidence of regional inflammation or effusion.

Free Abdomen

There is no evidence of free fluid. One to two colic lymph nodes are visualized, the largest measuring 0.69 cm. In addition, one to two prominent caudal abdominal lymph nodes are visualized, the largest measuring 1.02 cm.

ULTRASONOGRAPHIC FINDINGS

Primary Findings

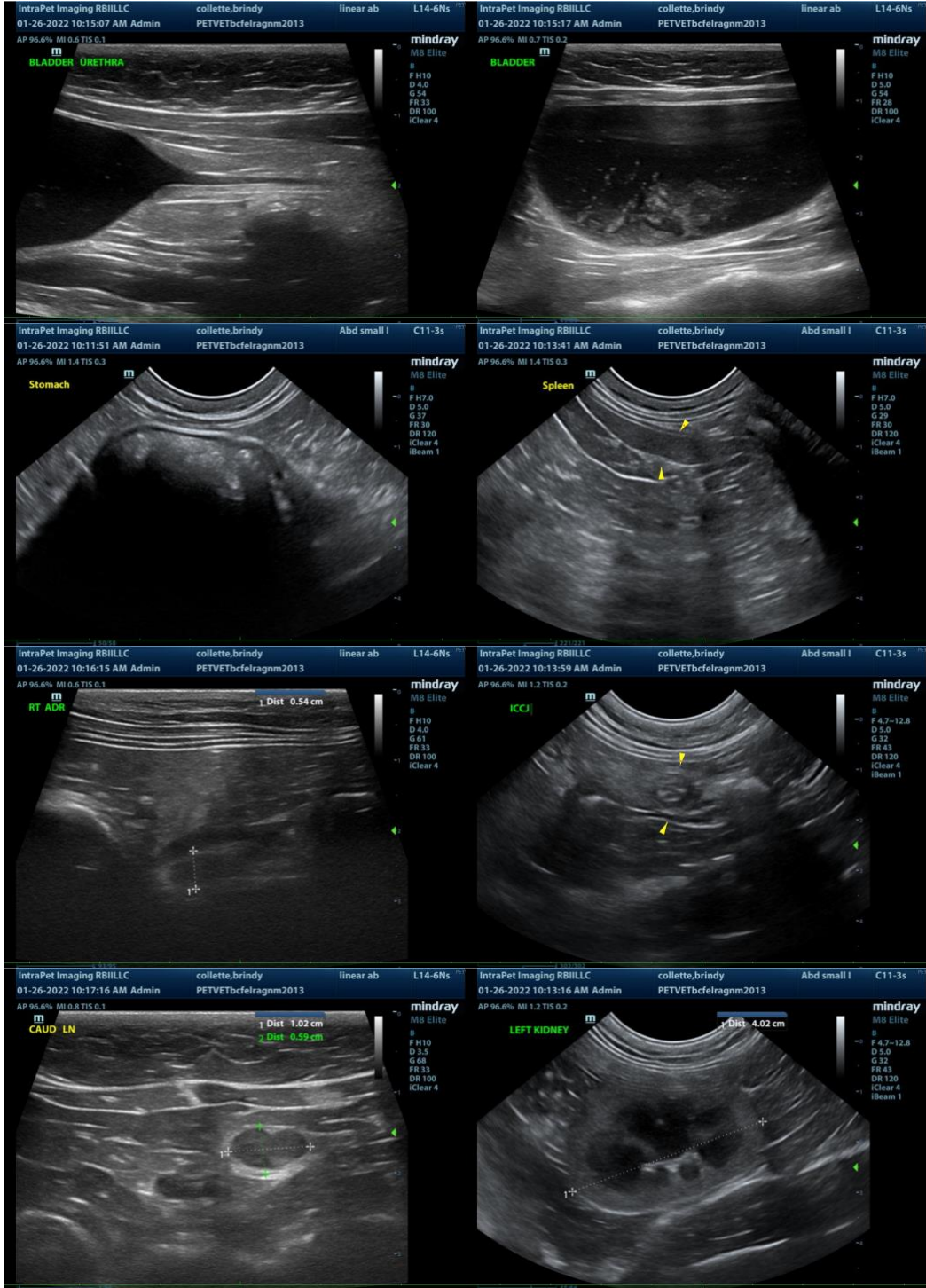
- The urinary bladder debris could be consistent with cells, crystals and/or exfoliated material.
- An obvious cause for the patient's stranguria is not identified in this study. Considerations include occult urinary tract infection, idiopathic cystitis, other.

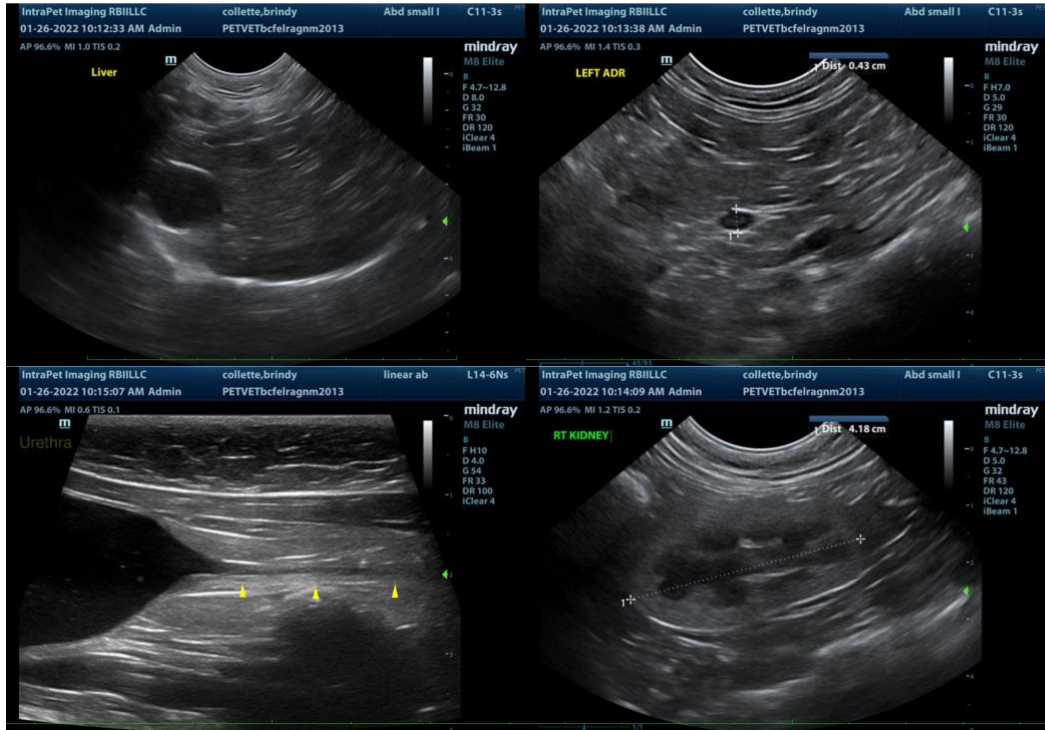
Secondary Findings

- Bilateral degenerative renal changes.
- Small intestinal wall pattern consistent with inflammatory bowel disease with some potential for emerging lymphoma.
- The lymph node changes are most consistent with reactive lymphadenitis or lymphoid hyperplasia.
- The shadowing diverticular foci material within the gastric lumen is most consistent with foreign material (i.e., trichobezoar, other). Correlation with clinical findings is recommended.

INTERPRETATION OF THE FINDINGS & FURTHER RECOMMENDATIONS

- Urine culture and sensitivity. If the urine culture is negative, continued treatment for idiopathic cystitis is recommended.
- If the patient develops gastrointestinal signs, a more advanced GI workup may be warranted.





The information and recommendations provided are based on the images presented by the referring veterinarian/sonographer. No evaluation can be communicated regarding pathology that was not visible in the image/video clips provided.

Thank you for this referral. If the clinical or image interpretation does not parallel your findings or if I can be of any further assistance, please contact me.

Andrea Nicastro, DVM, Diplomate DACVIM (Small Animal Internal Medicine)
info@SonoPath.com