



PATIENT

Emma Gildewell

SPECIES

Canine

BREED

Golden Retriever

SEX

Spayed Female

AGE

15 years

WEIGHT

62 lbs

INTERPRETED BY

Andrea Nicastro, DVM,
Diplomate ACVIM
(Small Animal Internal)

IMAGING PERFORMED BY

Loetitia Saint-Jacques, RVT

HOSPITAL NAME

Brighton Green Animal

REFERRING VET

Dr. R.

INVOICE

10163

PRESENTING CLINICAL SIGNS

History: Gender(altered?) FS Age: 15yrs Weight in #: 62 History: Having episodes of vomiting for multiple days then improving. Weight loss, o feeding home cooked bland diet 4 meals a day since episodes started around Christmas time. Prev 68lbs 8/2021, 74lbs 1/2020 Blood panel pending. Mass effect cranial abdomen on palpation- possible liver mass on ultrasound or other cranial abdominal mass. Enlarged right SMLN and left popliteal LN
Abnormal PE/Chem/CBC/UA Results:

ULTRASONOGRAPHIC EXAMINATION OF THE ABDOMEN

Urinary System

The urinary bladder is distended. The wall in the region of the apex is thickened (up to 0.60 cm) with an irregular mucosal surface. The wall tapers to a normal thickness as it extends toward the urinary bladder neck. A scant amount of echogenic debris is suspended within the lumen. No cystic calculi are observed. The region of the trigone and the visible portion of the proximal urethra are normal.

The left kidney presented normal size (6.31 cm in length); normal shape and architecture with smooth peripheral margins. There is a normal 1:3 cortex to medulla ratio with normal corticomedullary distinction. There is no evidence of pyelectasia, nephroliths, infarcts or hydroureter

The right kidney presented normal size (6.10 cm in length); normal shape and architecture with smooth peripheral margins. There is a normal 1:3 cortex to medulla ratio with normal corticomedullary distinction. There is no evidence of pyelectasia, nephroliths, infarcts or hydroureter.

Adrenal Glands

The left adrenal gland is mildly enlarged (0.91 cm at cranial pole) (0.96 cm at caudal pole) (2.68 cm in length); normal shape; homogenous parenchyma. The glandular echogenicity and detail are unremarkable. Capsule, cortex, and medullary definition are normal. The phrenicoabdominal vein and surrounding vasculature are normal.

The right adrenal gland is normal size (1.03 cm at cranial pole) (0.71 cm at caudal pole) (2.93 cm in length); normal shape; homogenous parenchyma. The glandular echogenicity and detail are unremarkable. Capsule, cortex, and medullary definition are normal. The phrenicoabdominal vein and surrounding vasculature are normal.

Spleen

The spleen is normal in size (1.66 cm in width at the level of the hilus) with a normal capsular contour. There is appropriate echogenicity and echotexture. No focal lesions are observed. Splenic vasculature is normal.

Liver

The liver is subjectively prominent in size with slightly swollen peripheral contours. The parenchyma is hypoechoic relative to the spleen and slightly mottled in appearance. A 1.52 cm hypoechoic nodule is observed within the parenchyma. Two additional isoechoic to slightly hypoechoic nodules/masses are observed on the right side, one measuring 1.95 cm, the other measuring 2.42 cm in length. Hepatic vasculature and intrahepatic biliary tracts are of normal volume with no evidence of congestion. See also "Other" category.

The gall bladder lumen is distended. The wall is normal in thickness. A large amount of aggregated echogenic suspended sludge in a partially stellate pattern is observed within the lumen. The cystic and



PATIENT common bile ducts are normal/not seen.

Emma Gildewell

Gastrointestinal

The gastric lumen is mildly distended with ingesta. The gastric wall is normal in thickness with a normal layering pattern. The small intestinal lumen is segmentally dilated with gas and chyme. The small intestinal wall thickness is normal with a normal layering pattern and appropriate mural detail. Discreet masses are not identified. The colonic wall is normal. No obstructive or overt infiltrative disease is noted.

SPECIES

Canine

BREED

Golden Retriever

Pancreas

The region of the pancreas is isoechoic relative to surrounding omental fat. No obvious parenchymal abnormalities are observed. There is no evidence of regional inflammation or effusion. (See also "Other" category)

SEX

Spayed Female

Free Abdomen

There is no obvious evidence of free fluid.

AGE

15 years

Lymph Nodes

(See "Other" category)

WEIGHT

62 lbs

Other

A brief echocardiogram reveals no evidence of pericardial effusion.

An 8.01 x 4.37 cm irregular, slightly heterogenous mass is observed in the cranial abdomen, just medial to the cranial pole of the spleen.

INTERPRETED BY

Andrea Nicastro, DVM,
Diplomate ACVIM
(Small Animal Internal)

ULTRASONOGRAPHIC FINDINGS

Primary Findings

- Cranial abdominal mass, the origin of which is unclear. It may be arising from liver, pancreas, lymph node, mesentery, other. Neoplasia (i.e., sarcoma, adenocarcinoma, round cell tumor), is suspected, with a low possibility of a benign process.
- The hepatic nodules could be consistent with metastatic disease. Alternatively, a benign process (i.e., regenerative nodules), may be present.
- The gall bladder changes are consistent with a mucocele.

IMAGING PERFORMED BY

Loetitia Saint-Jacques, RVT

Secondary Findings

- The urinary bladder wall changes are most consistent with cystitis.
- Mild left adrenomegaly

HOSPITAL NAME

Brighton Green Animal

REFERRING VET

Dr. R.

INVOICE

10163

INTERPRETATION OF THE FINDINGS & FURTHER RECOMMENDATIONS

- Three-view thoracic radiographs are recommended to assess for pulmonary metastases. If there is no evidence of pulmonary metastatic disease, and an aggressive approach is desired, consider referral to a board-certified surgeon to discuss abdominal exploratory with mass removal, liver biopsies, and cholecystectomy. An abdominal CT scan would be useful in



Portable Animal Veterinary Sonography, Inc.

IMAGING PERFORMED BY
pawsonography@gmail.com 530-786-8340

PATIENT

Emma Gildewell

SPECIES

Canine

BREED

Golden Retriever

SEX

Spayed Female

AGE

15 years

WEIGHT

62 lbs

INTERPRETED BY

Andrea Nicastro, DVM,
Diplomate ACVIM
(Small Animal Internal)

IMAGING PERFORMED BY

Loetitia Saint-Jacques, RVT

HOSPITAL NAME

Brighton Green Animal

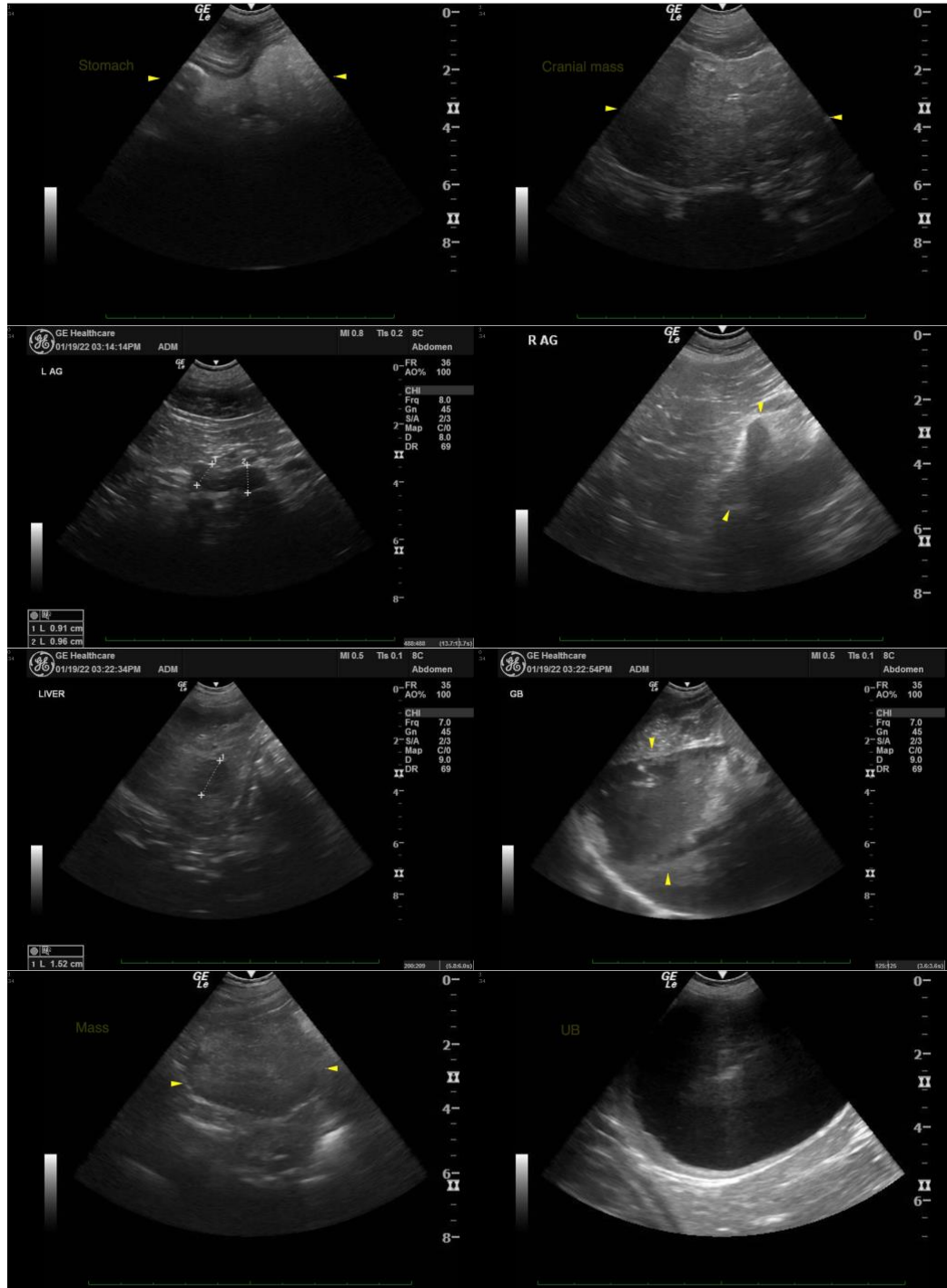
REFERRING VET

Dr. R.

INVOICE

10163

presurgical planning, particularly to help identify the origin of the cranial abdominal mass, and to evaluate for hepatic metastases. If surgery is not pursued, palliative care is recommended.





PATIENT

Emma Gildewell

SPECIES

Canine

BREED

Golden Retriever

SEX

Spayed Female

AGE

15 years

WEIGHT

62 lbs

INTERPRETED BY

Andrea Nicastro, DVM,
Diplomate ACVIM
(Small Animal Internal

IMAGING PERFORMED BY

Loetitia Saint-Jacques, RVT

HOSPITAL NAME

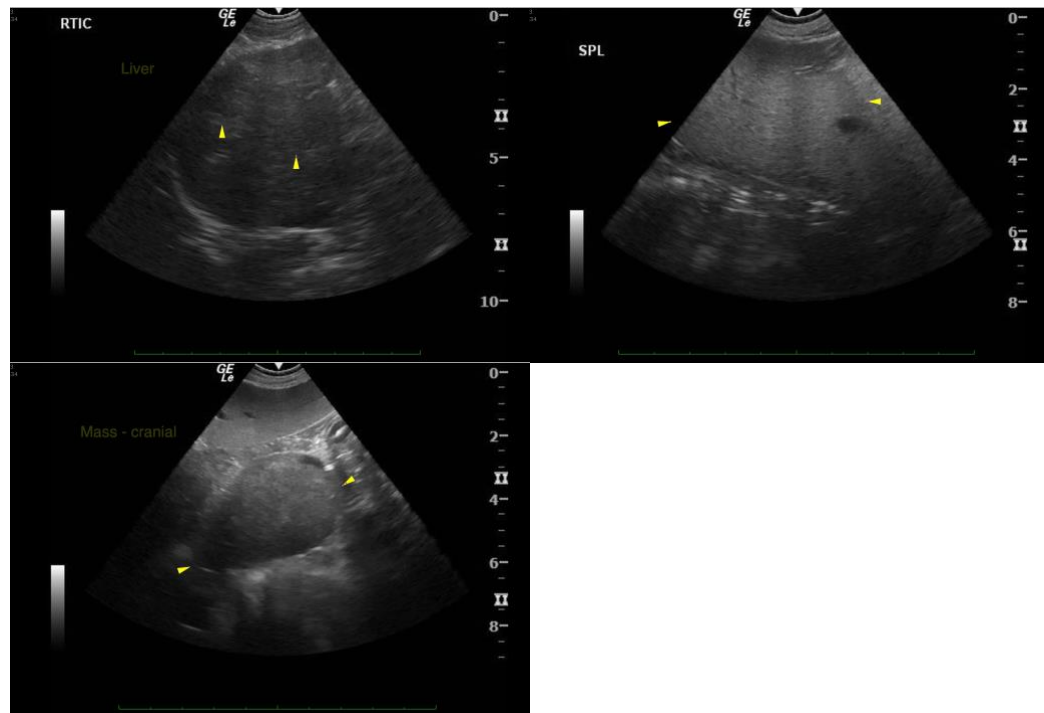
Brighton Green Animal

REFERRING VET

Dr. R.

INVOICE

10163



The information and recommendations provided are based on the images presented by the referring veterinarian. No evaluation can be communicated regarding pathology that was not visible in the image/video clips provided.

Thank you for this referral. If the clinical or image interpretation does not parallel your findings or if I can be of any further assistance, please contact me.

Andrea Nicastro, DVM, Diplomate DACVIM (Small Animal Internal Medicine)
info@SonoPath.com