



PATIENT

Snowi Matson

PRESENTING CLINICAL SIGNS

History: Snowi presented for evaluation of hematuria - seems to be a one-time event, but was quite bloody. No symptoms currently. Patient recently evaluated by cardiologist for heart murmur. Abnormal PE/Chem/CBC/UA Results: CBC/Chem/UA and 4DX are WNL.

SPECIES

Canine

ULTRASONOGRAPHIC EXAMINATION OF THE ABDOMEN

Urinary System

The urinary bladder, trigone, and pelvic urethra are normal in thickness and the mucosal surface is smooth. The bladder lumen is moderately distended with anechoic urine. No masses, inflammatory changes or calculi are observed. Ureteral papillae and visualized portion of the proximal urethra, visible to a depth of 2 cm, are normal.

BREED

Schnauzer

SEX

Neutered Male

The prostate is normal in size (1.19 cm in width) and shape. Parenchyma is homogenous. The prostatic urethra appears normal without evidence of dilation or obstruction.

AGE

8 years

The left kidney presented normal size (4.74 cm in length); normal shape and architecture with smooth peripheral margins. There is a normal 1:3 cortex to medulla ratio with normal corticomedullary distinction. There is no evidence of pyelectasia, nephroliths, infarcts or hydronephrosis. Renal vasculature is normal.

WEIGHT

18.7 lbs

The right kidney presented normal size (5.04 cm in length); normal shape and architecture with smooth peripheral margins. There is a normal 1:3 cortex to medulla ratio with normal corticomedullary distinction. There is no evidence of pyelectasia, nephroliths, infarcts or hydronephrosis. Renal vasculature is normal.

INTERPRETED BY

Andrea Nicastro, DVM,
Diplomate ACVIM (Small
Animal Internal
Medicine)

Adrenal Glands

The left adrenal gland is normal size (0.44 cm at cranial pole) (0.47 cm at caudal pole) (1.74 cm in length); normal shape; homogenous parenchyma. The glandular echogenicity and detail are unremarkable. Capsule, cortex, and medullary definition are normal. The phrenicoabdominal vein and surrounding vasculature are normal.

The right adrenal gland is normal size (0.63 cm at cranial pole) (0.38 cm at caudal pole) (2.67 cm in length); normal shape; homogenous parenchyma. The glandular echogenicity and detail are unremarkable. Capsule, cortex, and medullary definition are normal. The phrenicoabdominal vein and surrounding vasculature are normal.

IMAGING PERFORMED BY

Dr. Velasco

Spleen

The spleen is normal in size (1.43 cm in width at the level of the hilus) with a normal capsular contour. There is appropriate echogenicity and echotexture. No focal lesions are observed. Splenic vasculature is normal.

HOSPITAL NAME

Bethany Family Pet
Clinic

Liver

The liver is subjectively normal in size with normal contours and structure. There is appropriate echogenicity and echotexture. No overt structural evidence of inflammatory, infiltrative or regenerative pathology is evident. Vascular and biliary tracts are of normal volume with no evidence of congestion. No pathological hepatic lymphadenopathy observed.

REFERRING VET

Dr. Velasco

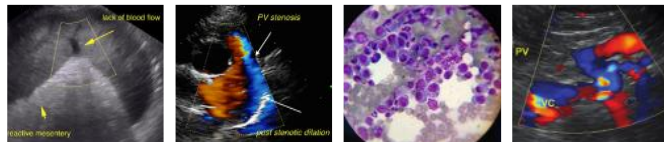
INVOICE

10154

The gall bladder is of normal contours and contains some dependent echogenic debris. The wall is normal in thickness. No choleliths are observed. The cystic and common bile ducts are normal/not seen.

DATE

1/19/22



PATIENT

Snowi Matson

SPECIES

Canine

BREED

Schnauzer

SEX

Neutered Male

AGE

8 years

WEIGHT

18.7 lbs

INTERPRETED BY

Andrea Nicastro, DVM,
Diplomate ACVIM (*Small
Animal Internal
Medicine*)

**IMAGING PERFORMED
BY**

Dr. Velasco

HOSPITAL NAME

Bethany Family Pet
Clinic

REFERRING VET

Dr. Velasco

INVOICE

10154

DATE

1/19/22

Gastrointestinal

The gastric lumen is mildly distended with ingesta. The gastric wall and pylorus are normal in thickness with a normal layering pattern. The small intestinal lumen is not dilated. The small intestinal wall thickness is normal with a normal layering pattern and appropriate mural detail. Discreet masses are not identified. The colonic wall is normal. No obstructive or overt infiltrative disease is noted.

Pancreas

The region of the pancreas is isoechoic relative to surrounding omental fat. No obvious parenchymal abnormalities are observed. There is no evidence of regional inflammation or effusion.

Free Abdomen

The peritoneal cavity is normal. There is no evidence of inflammation or effusion. The abdominal lymph nodes are normal/not visible.

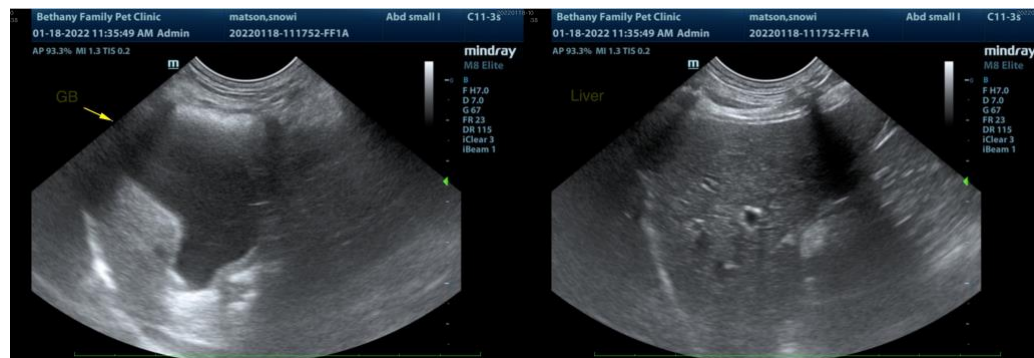
ULTRASONOGRAPHIC FINDINGS

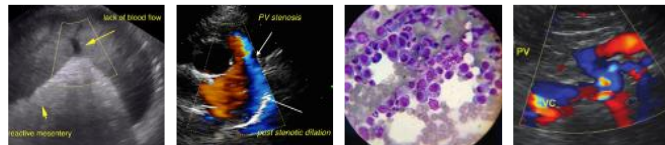
Primary Findings

- Unremarkable abdomen. An obvious cause for the patient's episode of hematuria is not identified in this study. Considerations include urinary tract infection, coagulopathy, benign essential renal hematuria, urinary bladder trauma, microscopic lower urinary tract neoplasia, passing urolith, other.

INTERPRETATION OF THE FINDINGS & FURTHER RECOMMENDATIONS

- PT/PTT
- Urine culture and sensitivity
- +/- Urine BRAF test to further evaluate for lower urinary tract neoplasia.
- If the above diagnostics are inconclusive and hematuria recurs, benign essential renal hematuria may be present. It would be ideal to re-ultrasound the patient at the time of the hematuria.





PATIENT

Snowi Matson

SPECIES

Canine

BREED

Schnauzer

SEX

Neutered Male

AGE

8 years

WEIGHT

18.7 lbs

INTERPRETED BY

Andrea Nicastro, DVM,
Diplomate ACVIM (Small
Animal Internal
Medicine)

IMAGING PERFORMED BY

Dr. Velasco

HOSPITAL NAME

Bethany Family Pet
Clinic

REFERRING VET

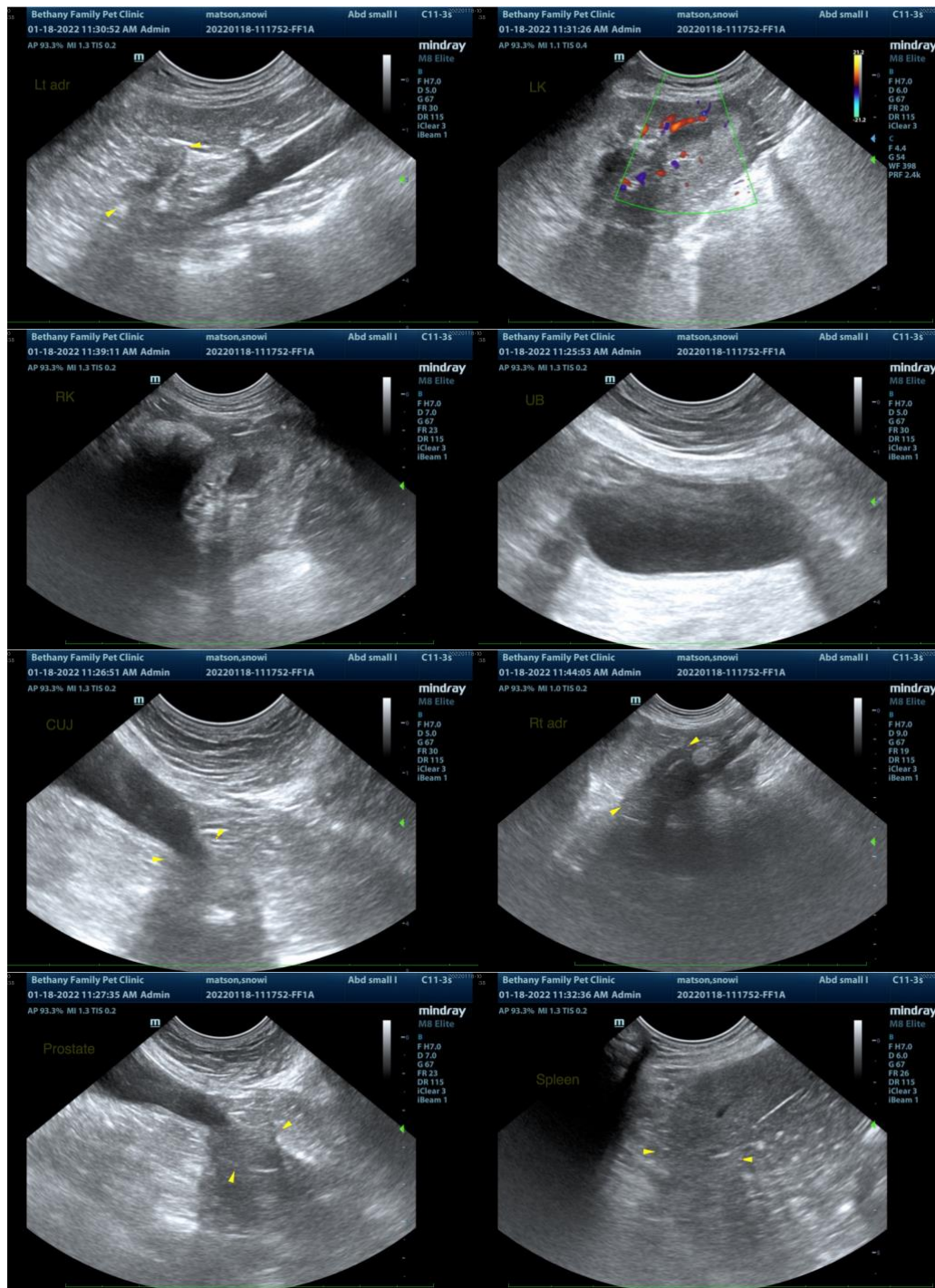
Dr. Velasco

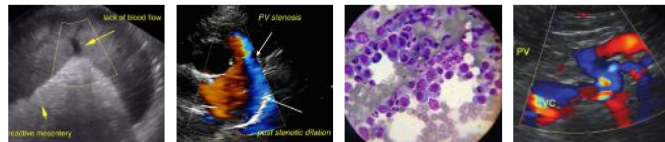
INVOICE

10154

DATE

1/19/22





PATIENT

Snowi Matson

SPECIES

Canine

BREED

Schnauzer

SEX

Neutered Male

AGE

8 years

WEIGHT

18.7 lbs

INTERPRETED BY

Andrea Nicastro, DVM,
Diplomate ACVIM (Small
Animal Internal
Medicine)

IMAGING PERFORMED BY

Dr. Velasco

HOSPITAL NAME

Bethany Family Pet
Clinic

REFERRING VET

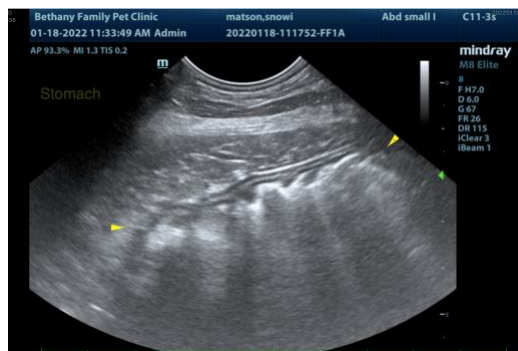Dr. Velasco

INVOICE

10154

DATE

1/19/22



The information and recommendations provided are based on the images presented by the referring veterinarian. No evaluation can be communicated regarding pathology that was not visible in the image/video clips provided.

Thank you for this referral. If the clinical or image interpretation does not parallel your findings or if I can be of any further assistance, please contact me.

Andrea Nicastro, DVM, Diplomate DACVIM (Small Animal Internal Medicine)
info@SonoPath.com