

DATE PRESENTING CLINICAL SIGNS

1/12/2022 History: UTD on vaccines. 12/7 increased urine frequency, hematuria noted. RX: Provable and simplice. Prev been on Apoquel. 12/22 persistent hematuria. 12/23 - rad revealed hepatomegaly, but no uroliths appreciated.

PATIENT

Khloe Richardson Current Medications: Gabapentin 100mg BID.
Lab Results: Hematuria. Attached separately.
Radiographs: Hepatomegaly.

SPECIES

Canine

Date of Previous IntraPet Ultrasound: No previous IntraPet scans.
Sedation: Not required to complete full diagnostic ultrasound.
Stat Report: Not requested.
Imaging Performed By: Rachel Brillhart, RDMS.

BREED

Shih Tzu Mixed Breed

Additional history: CBC unremarkable. ALP 326. T4 normal. Urine Specific Gravity 1.029. No proteinuria. Inactive sediment.

SEX

Female Spayed

ULTRASONOGRAPHIC EXAMINATION OF THE ABDOMEN

Urinary System

The urinary bladder, trigone, and pelvic urethra are normal in thickness and the mucosal surface is smooth. The bladder lumen is moderately distended with anechoic urine. No masses, inflammatory changes or calculi are observed. Ureteral papillae and visualized portion of the proximal urethra, visible to a depth of 2 cm, are normal.

AGE

6 10/2010

WEIGHT

17.5 Lbs

The left kidney is normal in size (4.42 cm in length) with a normal shape, smooth peripheral margins, and normal internal architecture. There is minimal loss of corticomedullary distinction. Pinpoint hyperechoic foci are observed within the cortex. Several hyperechoic shadowing diverticular foci are observed. There is no evidence of pyelectasia, infarcts or hydronephrosis. Renal vasculature is normal.

INTERPRETED BY

Andrea Nicastro, DMV,
Diplomate DACVIM
(Small Animal
Internal Medicine)

The right kidney is normal in size (5.09 cm in length) with a normal shape, smooth peripheral margins, and normal internal architecture. There is minimal loss of corticomedullary distinction. Pinpoint hyperechoic foci are observed within the cortex. Several hyperechoic shadowing diverticular foci are observed. There is no evidence of pyelectasia, infarcts or hydronephrosis. Renal vasculature is normal.

HOSPITAL NAME

Paradise Animal
Hospital

Adrenal Glands

The left adrenal gland is mildly enlarged (0.72 cm at cranial pole) (0.69 cm at caudal pole) (2.01 cm in length); normal shape; homogenous parenchyma. The glandular echogenicity and detail are unremarkable. Capsule, cortex, and medullary definition are normal. The phrenicoabdominal vein and surrounding vasculature are normal.

REFERRING VET

Dr. Twardzik

The right adrenal gland is mildly enlarged (0.67 cm at cranial pole) (0.64 cm at caudal pole) (1.82 cm in length); normal shape; homogenous parenchyma. The glandular echogenicity and detail are unremarkable. Capsule, cortex, and medullary definition are normal. The phrenicoabdominal vein and surrounding vasculature are normal.

INVOICE

10135

Spleen

The spleen is normal in size (1.14 cm in width at the level of the hilus) with a normal capsular contour. There is appropriate echogenicity and echotexture. No focal lesions are observed. Splenic vasculature is normal.

Liver

The liver is subjectively prominent in size with slightly swollen peripheral contours. Hepatic vasculature and intrahepatic biliary tracts are of normal volume with no evidence of congestion.

The gall bladder lumen is moderately distended. The wall is thin and smooth. A small amount of echogenic debris is observed within the lumen, some of which is gravity dependent and some of which is suspended. The cystic and common bile ducts are normal.

Gastrointestinal

The stomach and intestine are free of stasis and exhibit normal peristaltic activity. The gastric lumen is not distended. The gastric wall and pylorus are normal in thickness with a normal layering pattern. The small intestine shows evidence of mucosal speckling in some segments. Discreet masses are not identified. The colonic wall is normal. There is no evidence of an obstructive pattern.

Pancreas

The right limb of the pancreas is visible with normal curvilinear peripheral contours. The parenchyma is largely isoechoic relative to surrounding omental fat and slightly mottled in appearance. The pancreatic duct is visible but not overtly dilated. There is no evidence of peripancreatic inflammation or effusion.

Free Abdomen

The peritoneal cavity is normal. There is no evidence of inflammation or effusion. The abdominal lymph nodes are normal/not visible.

ULTRASONOGRAPHIC FINDINGS

Primary Findings

- Bilateral minor age-related renal changes with dystrophic mineralization

Secondary Findings

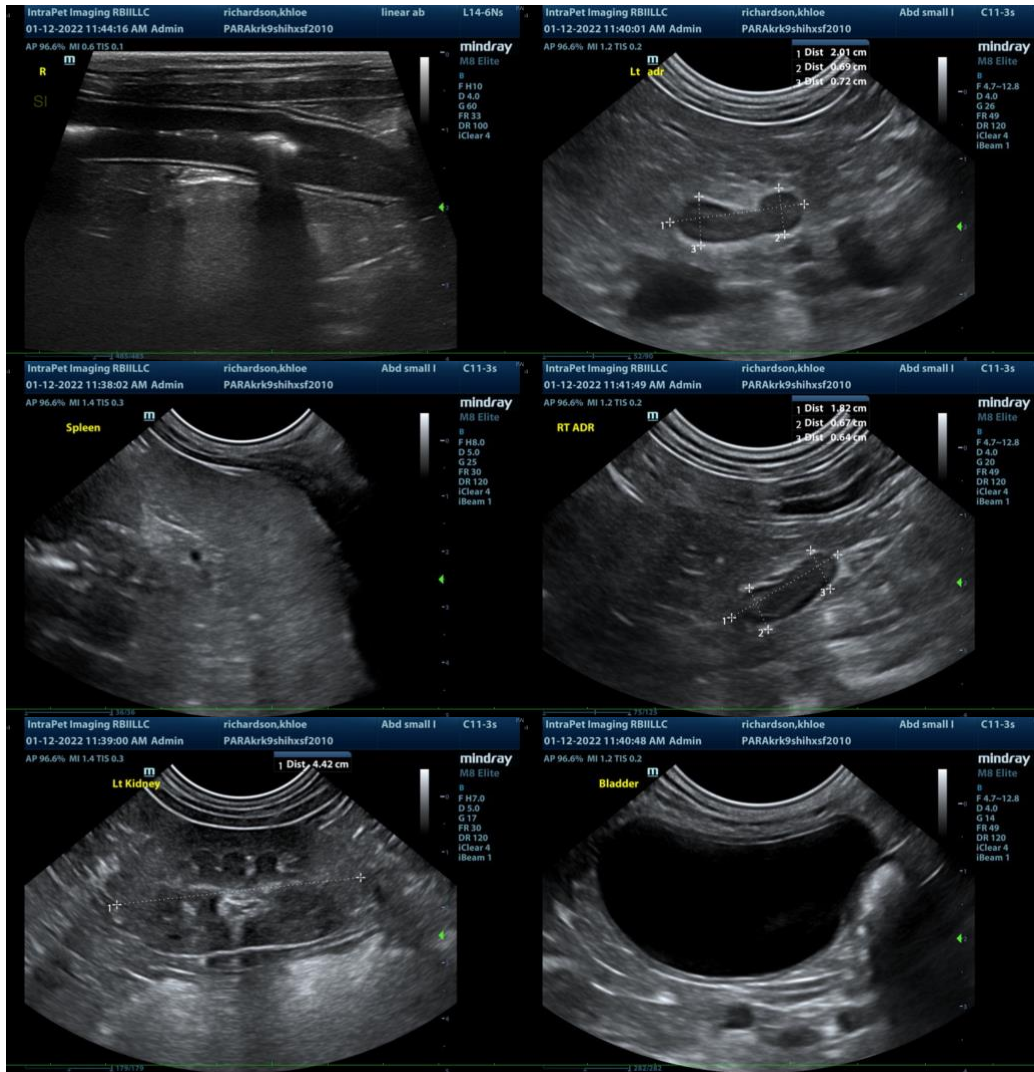
- Mild bilateral adrenomegaly
- The diffuse hepatic changes are non-specific and could be consistent with vacuolar hepatopathy, regenerative nodular hyperplasia, and/or age-related remodeling. Inflammatory and infiltrative disease are considered less likely.
- Age-related pancreatic remodeling +/- fibrosis. Low-grade inflammation may be present, particularly if the patient exhibits discomfort upon abdominal palpation.
- The small intestinal mucosal speckling can be associated with enteritis. However, correlation with clinical findings is recommended.

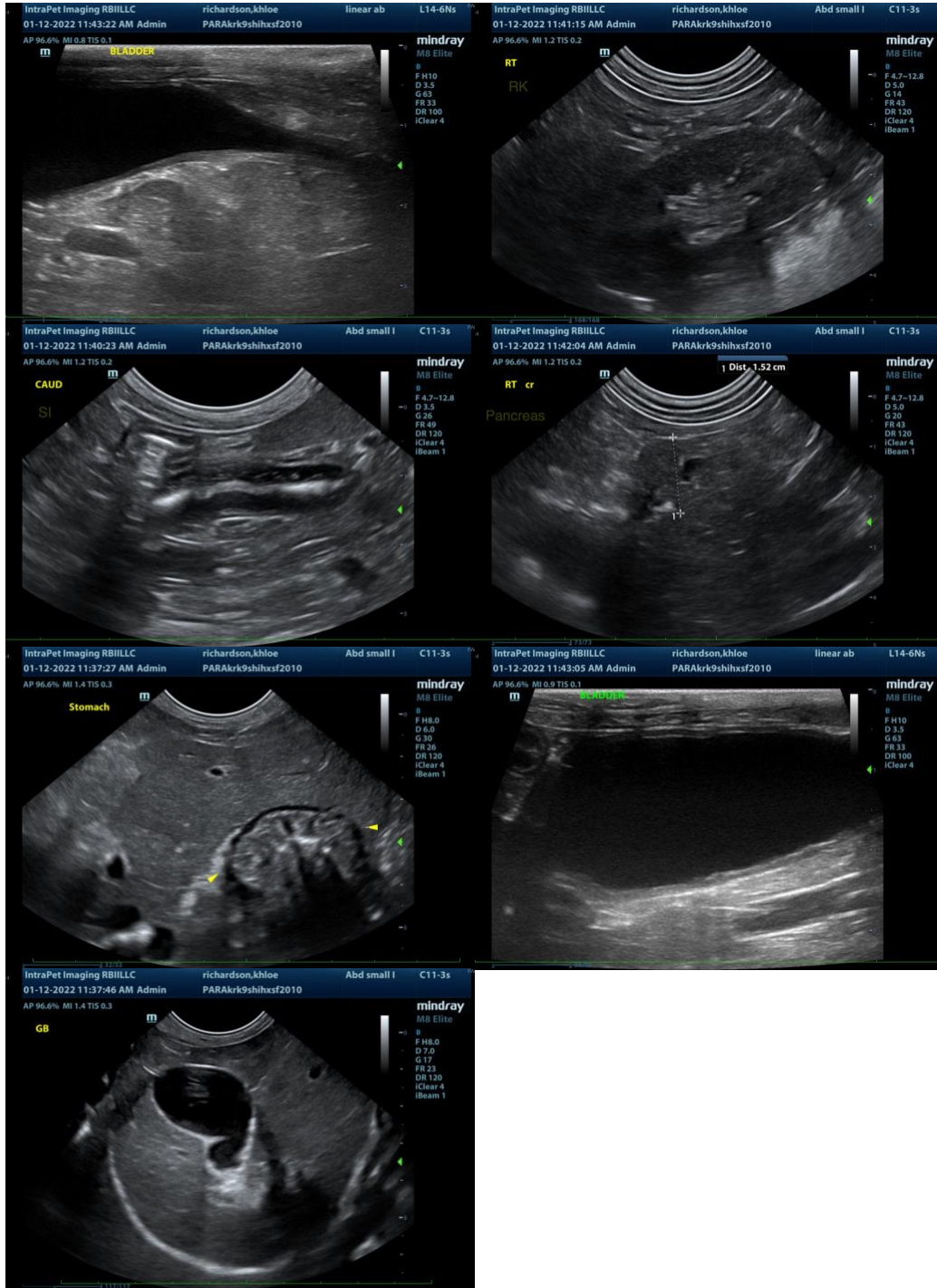
*An obvious cause for the patient's clinical signs is not identified in this study.

INTERPRETATION OF THE FINDINGS & FURTHER RECOMMENDATIONS

- Consider a urine culture and sensitivity to assess for occult pyelonephritis. A urine BRAF test can also be considered to assess for microscopic lower urinary tract neoplasia, although this is considered unlikely based on the sonographic findings.

- If the above tests are normal and hematuria (either gross or on the urine sediment) persists, benign essential renal hematuria may be present.
- Consider testing for hyperadrenocorticism with a low-dose dexamethasone suppression test or ACTH stimulation test if clinical signs (i.e., PU/PD) develop.





The information and recommendations provided are based on the images presented by the referring veterinarian. No evaluation can be communicated regarding pathology that was not visible in the image/video clips provided.

Thank you for this referral. If the clinical or image interpretation does not parallel your findings or if I can be of any further assistance, please contact me.

Andrea Nicastro, DVM, Diplomate DACVIM (Small Animal Internal Medicine)
info@SonoPath.com