

DATE PRESENTING CLINICAL SIGNS

1/12/2021 History: Hx of pemphigus diagnosed by biopsy. Previously on triamcinolone. Presented on 1/5/2022 for jaundice. Ecchymosis and diffuse jaundice present. Previous mild incr ALT prior to starting triamcinolone-- not worked up.

PATIENT

Jubilee Shannon

Current Medications: Vitamin K 6.25 mg q 12 hr, Vitamin B12 0.25 mL SQ, Doxycycline 25 mg q 12 hr, Marbofloxacin 12.5 mg q 24 hr, Denamarin cat q 24 hr, d/c triamcinolone and started prednisolone 5 mg PO q24 hr.

SPECIES

Feline

Lab Results: Elevated ALT 781, tbili 7, ggt 12, Hct=23.5%, elevated WBC 18.63 with incr neut16.91. Elevated coags; PT >70, PTT 33. CBC review no organisms. Macro/micro agglutination neg.

Date of Previous IntraPet Ultrasound: No previous IntraPet scans.

Sedation: Gabapentin.

BREED

Stat Report: Not requested.

Imaging Performed By: Rachel Brillhart, RDMS.

DSH

ULTRASONOGRAPHIC EXAMINATION OF THE ABDOMEN

SEX

Female Spayed

Urinary System

The urinary bladder, trigone, and pelvic urethra are normal in thickness and the mucosal surface is smooth. The bladder lumen is moderately distended with mostly anechoic urine. No masses, inflammatory changes or calculi are observed. Ureteral papillae and visualized portion of the proximal urethra, visible to a depth of 2 cm, are normal.

AGE

11/8/2017

The left kidney is normal size (4.61 cm in length); normal shape and architecture with smooth peripheral margins. There is a normal 1:3 cortex to medulla ratio with normal corticomedullary distinction. There is no evidence of pyelectasia, nephroliths, infarcts or hydroureter. Renal vasculature is normal.

WEIGHT

9.8 Lbs

The right kidney is normal in size (4.15 cm in length); with a slightly irregular shape. There is a normal 1:3 cortex to medulla ratio with slight loss of corticomedullary distinction. A cortical infarct is suspected at the lateral aspect. Trace pyelectasia is present. There is no evidence of nephroliths, infarcts or hydroureter. Renal vasculature is normal.

INTERPRETED BY

Andrea Nicastro, DMV,
Diplomate DACVIM
(Small Animal
Internal Medicine)

Adrenal Glands

The region of the adrenal glands is evaluated. No obvious pathology is seen.

HOSPITAL NAME

Paradise Animal
Hospital

Spleen

The spleen is subjectively normal in size (0.79 cm in width at the level of the hilus) with an undulating medial contour. There is appropriate echogenicity and echotexture. No focal lesions are observed. Splenic vasculature is normal.

REFERRING VET

Hospital Dr. Riehl

Liver

The liver is subjectively normal in size with normal curvilinear peripheral contours and structure. The parenchyma is hyperechoic relative to the spleen and subtly mottled in appearance. No distinct focal lesions are observed. Hepatic vasculature and intrahepatic biliary tracts are of normal volume with no evidence of congestion.

INVOICE

10133

The gall bladder lumen is moderately distended. The wall is thin and smooth. A scant amount of echogenic debris is suspended within the lumen. The cystic and common bile ducts are normal.

No pathological hepatic lymphadenopathy observed. The gall bladder lumen is moderately distended. The wall is thin and smooth. Luminal contents are anechoic. The cystic and common bile ducts are normal/not seen.

Gastrointestinal

The stomach and intestine are free of stasis and exhibit normal peristaltic activity. The gastric lumen is not distended. The gastric wall and pylorus are normal in thickness with a normal layering pattern. The pyloric outflow tract is patent. The small intestinal lumen is not dilated. The small intestinal wall thickness is normal with a normal layering pattern and appropriate mural detail. Discreet masses are not identified. The ileocecolic junction and colonic wall are normal. There is no evidence of an obstructive pattern.

Pancreas

The left limb is visible with normal curvilinear peripheral contours. The parenchyma is mildly hypoechoic relative to surrounding omental fat. No focal lesions are observed. The pancreatic duct is visible but not overtly dilated (1.13 cm in diameter).

Free Abdomen

There is no evidence of free fluid. The abdominal lymph nodes are normal/not visible.

ULTRASONOGRAPHIC FINDINGS

Primary Findings

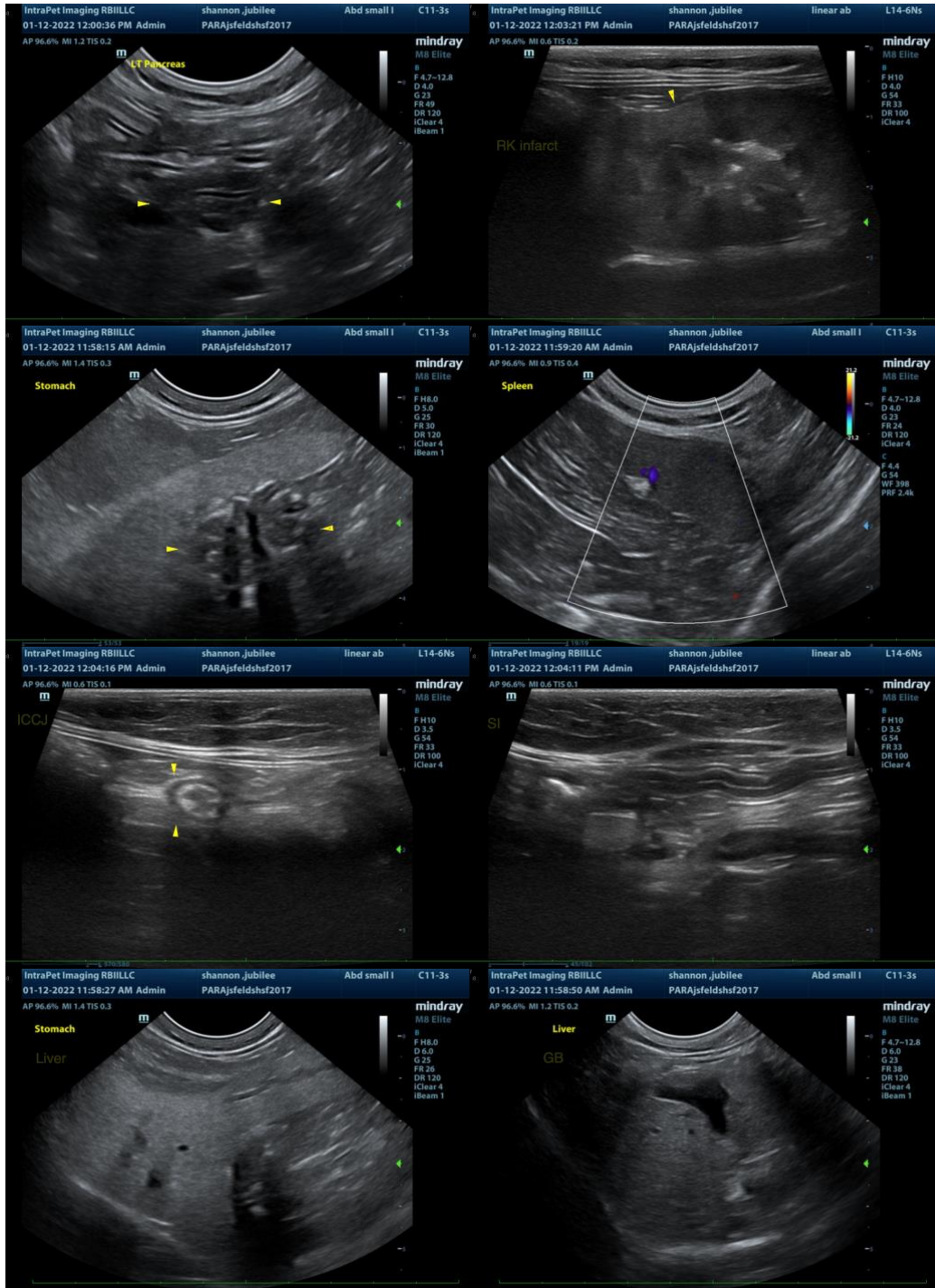
- The hepatic parenchymal changes are nonspecific and could be secondary to hepatic lipidosis, inflammatory/immune-mediated disease (i.e., bacterial cholangiohepatitis, lymphoplasmacytic hepatitis), infiltrative neoplasia (i.e., lymphoma), hepatotoxicity, other hepatopathy.

Secondary Findings

- The pancreatic changes may be a normal variant for this patient or could be consistent with mild, chronic pancreatitis. Correlation with clinical findings is recommended.
- Minor chronic right renal changes with a suspected cortical infarct

INTERPRETATION OF THE FINDINGS & FURTHER RECOMMENDATIONS

- Given the history of immunosuppression, consider further testing for infectious diseases, (i.e., toxoplasmosis, *Mycoplasma haemofelis*, feline leukemia/FIV).
- If the patient's clotting status can be stabilized (i.e., via fresh frozen plasma, a fine-needle aspirate or surgical biopsy of the liver would be beneficial in obtaining a definitive diagnosis. If surgery is pursued at some point, aerobic and anaerobic bile cultures are also recommended. In the meantime, continued empirical treatment for bacterial cholangiohepatitis and hepatic lipidosis is recommended. Nutritional support (i.e., via a temporary feeding tube is also strongly recommended to help prevent/treat hepatic lipidosis.
- Three view thoracic radiographs are recommended to evaluate cardiopulmonary status.



The information and recommendations provided are based on the images presented by the referring veterinarian. No evaluation can be communicated regarding pathology that was not visible in the image/video clips provided.

Thank you for this referral. If the clinical or image interpretation does not parallel your findings or if I can be of any further assistance, please contact me.

Andrea Nicastro, DVM, Diplomate DACVIM (Small Animal Internal Medicine)
info@SonoPath.com