

**DATE PRESENTING CLINICAL SIGNS**

1-7-2022 History: anorexia, lethargy, stage II-III dental dz, episode of vomiting, vomited tricobezoars.

**PATIENT** Current Medications: Cerenia 16mg Q 24hrs starting 1/3/22, Entyce 15mg Q 24hr, Clavamox 90mg Q 12hr, Clindamycin 75 mg Q 12hr 12/24/21-12/31/21 - no response, Carprofen 12.5mg Q12 hr 12/24/21-12/31/21 - no response.  
 Reese Hughes

**SPECIES** Lab Results: cbc/chem - GGT 18, TBil 1.0, K+ 5.4, HCT 62.1%. Attached separately.  
 Radiographs: no obvious obstructive patten. Poss foreign material in pylore region of stomach.  
 Date of Previous IntraPet Ultrasound: No previous IntraPet scans.

Canine Sedation: Not required to complete full diagnostic ultrasound.  
 Stat Report: Not requested.

**BREED PRESENTING CLINICAL SIGNS**

Dachshund

**ULTRASONOGRAPHIC EXAMINATION OF THE ABDOMEN****SEX** *Urinary System*

Female Spayed The urinary bladder, trigone, and pelvic urethra are normal in thickness and the mucosal surface is smooth. The bladder lumen is mildly distended with anechoic urine. No masses, inflammatory changes or calculi are observed. Ureteral papillae and visualized portion of the proximal urethra, visible to a depth of 2 cm, are normal.

2-14-2012 The prostate is not definitively visualized due to its pelvic location.

**WEIGHT**

12.8 Lbs. The left kidney presented normal size (4.16 cm in length); normal shape and architecture with smooth peripheral margins. There is a normal 1:3 cortex to medulla ratio with normal corticomedullary distinction.

**INTERPRETED BY** There is no evidence of pyelectasia, nephroliths, infarcts or hydroureter. Renal vasculature is normal.

Andrea Nicastro, DMV, Diplomat DACVIM (Small Animal Internal Medicine) The right kidney presented normal size (4.74 cm in length); normal shape and architecture with smooth peripheral margins. There is a normal 1:3 cortex to medulla ratio with normal corticomedullary distinction. There is no evidence of pyelectasia, nephroliths, infarcts or hydroureter. Renal vasculature is normal.

**IMAGING PERFORMED BY** *Adrenal Glands*

Stephanie Pearce RDCS, RVT The left adrenal gland is normal size (0.45 cm at cranial pole) (0.53 cm at caudal pole) (1.67 cm in length); normal shape; homogenous parenchyma. The glandular echogenicity and detail are unremarkable. Capsule, cortex, and medullary definition are normal. The phrenicoabdominal vein and surrounding vasculature are normal.

**HOSPITAL NAME**

Northwind Animal Hospital The right adrenal gland is normal size (0.83 cm at cranial pole) (0.35 cm at caudal pole) (1.72 cm in length); normal shape; homogenous parenchyma. The glandular echogenicity and detail are unremarkable. Capsule, cortex, and medullary definition are normal. The phrenicoabdominal vein and surrounding vasculature are normal.

**REFERRING VET**

Hospital Dr. Miller *Spleen*  
 The spleen is normal in size (1.15 cm in width at the level of the hilus) with a normal capsular contour. There is appropriate echogenicity and echotexture. No focal lesions are observed. Splenic vasculature is normal.

**INVOICE**

10125 *Liver*

The liver is subjectively normal in size with normal contours and structure. There is appropriate echogenicity and echotexture. No overt structural evidence of inflammatory, infiltrative or regenerative pathology is evident. Vascular and biliary tracts are of normal volume with no evidence of congestion. No

pathological hepatic lymphadenopathy observed.

The gall bladder lumen is moderately distended. The wall is thin and smooth. A small amount of suspended echogenic debris is observed within the lumen. The cystic and common bile ducts are normal.

### ***Gastrointestinal***

The stomach and intestine are free of stasis and exhibit normal peristaltic activity. The gastric lumen is minimally distended with fluid and chyme. The gastric wall and pylorus are normal in thickness with a normal layering pattern. The small intestinal lumen is not dilated. The small intestinal wall thickness is normal with a normal layering pattern and appropriate mural detail. Discreet masses are not identified. The colonic wall is normal. No obstructive or overt infiltrative disease is noted.

### ***Pancreas***

The region of the pancreas is isoechoic relative to surrounding omental fat. No obvious parenchymal abnormalities are observed. There is no evidence of regional inflammation or effusion.

### ***Free Abdomen***

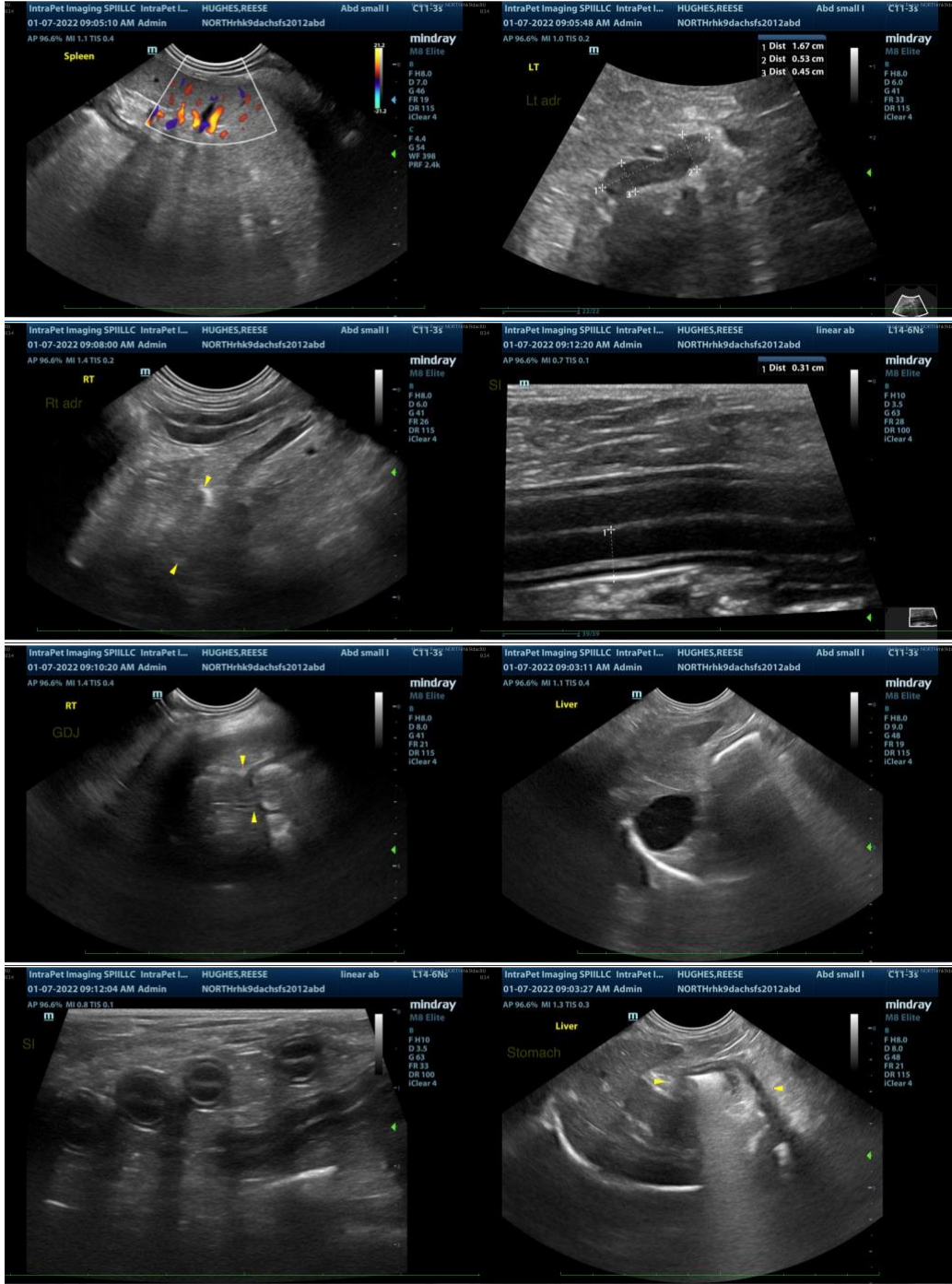
The peritoneal cavity is normal. There is no evidence of inflammation or effusion. The abdominal lymph nodes are normal/not visible.

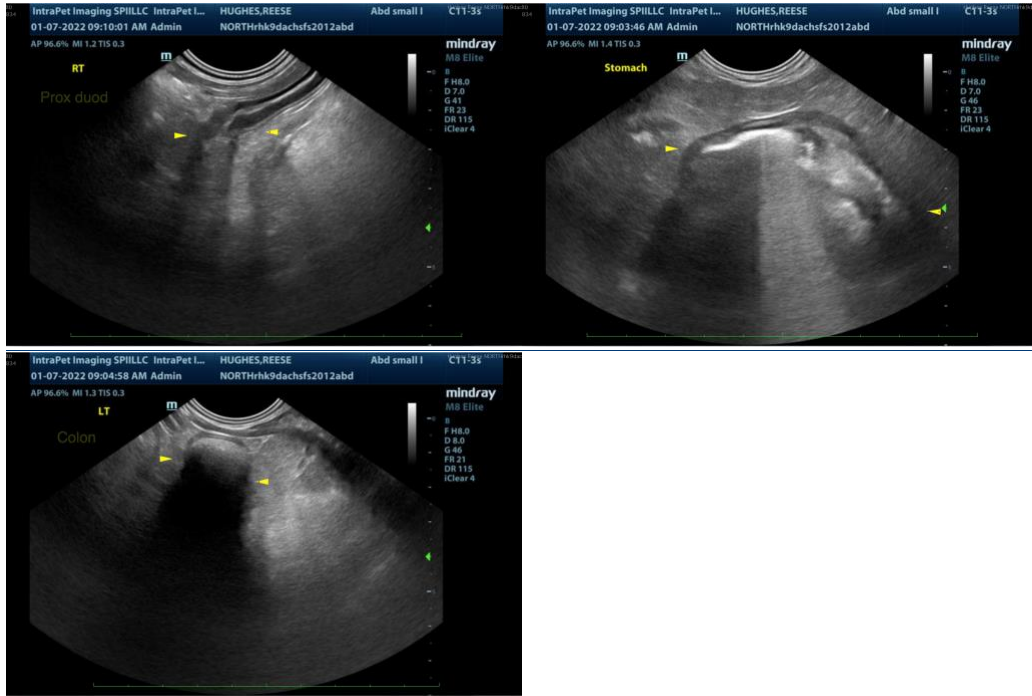
## **ULTRASONOGRAPHIC FINDINGS**

Unremarkable abdomen. An obvious cause for the patient's clinical signs is not identified in this study. There is no obvious evidence of an obstructive pattern. Possible differentials include primary gastrointestinal disease (i.e., infectious/parasitic, intestinal dysbiosis, inflammatory bowel disease, food allergy), low-grade pancreatitis, underlying metabolic issue from other.

## **INTERPRETATION OF THE FINDINGS & FURTHER RECOMMENDATIONS**

- Consider a more advanced GI workup, which could include the following:
  1. Fecal evaluation for ova and Giardia
  2. A resting cortisol level to screen for hypoadrenocorticism. If resting cortisol level is < 2.0 mcg/dL, an ACTH stimulation test is recommended.
  3. GI panel (send to Texas A&M).
  4. +/- endoscopic or surgical gastrointestinal surgical biopsies
- There is some suggestion of mild cardiomegaly on the radiographs submitted with the patient history. If a heart murmur is present, consider a full cardiac workup including an echocardiogram, ECG and blood pressure measurement.





The information and recommendations provided are based on the images presented by the referring veterinarian. No evaluation can be communicated regarding pathology that was not visible in the image/video clips provided.

Thank you for this referral. If the clinical or image interpretation does not parallel your findings or if I can be of any further assistance, please contact me.

**Andrea Nicastro, DVM, Diplomate DACVIM (Small Animal Internal Medicine)**  
info@SonoPath.com