



PATIENT

Bunny Sunango

SPECIES

Rabbit

BREED

Dwarf

SEX

Neutered male

AGE

1 year

WEIGHT

1147 g

INTERPRETED BY

Alicia Angosto
Guerrero, DMV,
PgDip, MSc.

IMAGING PERFORMED BY

Kerri Becker

HOSPITAL NAME

Companion AH
Parsippany

REFERRING VET

Dr. Wolf

INVOICE

75556

DATE

5/14/26

PRESENTING CLINICAL SIGNS

History: Looking for a bezoar or partial liver torsion

ULTRASONOGRAPHIC EXAMINATION OF THE ABDOMEN

Urinary System

The urinary bladder lumen is normally distended, and the wall of the urinary bladder appears thin and smooth. The cloudy appearance of the urine is consistent with normal physiologic calcium excretion in rabbits. The bladder neck, trigone region, and proximal urethra are unremarkable. There are no calculi and no evidence of inflammatory or neoplastic changes.

The left kidney is normal in shape and size: 2.05×1.37 cm, and the thickness of the cortex is 0.24 cm in the sagittal plane. The right kidney is normal in shape and size: 2.16×1.42 cm, and the thickness of the cortex is 0.22 cm in the sagittal plane. Both kidneys demonstrate cortical echogenicity similar to the hepatic parenchyma. The corticomedullary ratio and corticomedullary definition are preserved. The renal sinus appears hyperechoic, as expected in rabbits. There is no evidence of pyelectasia, nephrolithiasis, or hydronephrosis.

Adrenal Glands

Not confidently visualized.

Spleen

Not confidently visualized. In rabbits, the spleen is normally small and positioned along the greater curvature of the stomach, with the dorsal and medial portions often extending partially beneath the rib cage. In this case, the combination of the small splenic size and its normal anatomic positioning likely limited sonographic visualization.

Liver

The liver is subjectively normal in size, with sharp edges and a regular contour. The hepatic parenchyma is homogeneous and isoechoic compared to the falciform fat, with a normal echotexture. No ultrasonographic evidence of hepatic lobe torsion or overt hepatic lipidosis is identified despite the reported prolonged anorexia.

The gallbladder lumen is normally distended. The wall is thin, and the contents are predominantly anechoic. No dilation of the cystic duct or common bile duct is identified.

Gastrointestinal Tract

The stomach is moderately distended with heterogeneous ingesta and demonstrates moderately pronounced distal acoustic shadowing associated with the luminal contents. The shadowing does not



PATIENT

Bunny Sunango

SPECIES

Rabbit

BREED

Dwarf

SEX

Neutered male

AGE

1 year

WEIGHT

1147 g

INTERPRETED BY

Alicia Angosto
Guerrero, DMV,
PgDip, MSc.

IMAGING PERFORMED BY

Kerri Becker

HOSPITAL NAME

Companion AH
Parsippany

REFERRING VET

Dr. Wolf

INVOICE

75556

DATE

5/14/26

completely extend to the mucosal surface. No convincing ultrasonographic evidence of severe gastric impaction or complete obstructive gastric outflow disease is identified. The gastric body wall measures 0.72 mm and demonstrates preserved layering. The pyloric region could not be completely assessed.

The small intestine demonstrates normal wall thickness with preserved wall layering, is within published reference limits for rabbit small intestine/duodenum (approximately 0.19±0.04 cm). The small intestinal lumen is largely empty, without evidence of mechanical ileus, focal obstruction, tympanism, or segmental intestinal dilation. A few small hyperechoic aggregates/bezoar-like structures measuring approximately 4 mm are present; however, these do not appear obstructive.

The cecum demonstrates a normal very thin wall (0.31–0.40 mm) with normal luminal contents. No cecal impaction, fluid distension, or tympanism is identified. Published reference cecal wall thickness in rabbits is approximately 0.08±0.01 cm.

The appendix measures 1.99 mm in thickness, which is within or near the upper end of reported published reference ranges for rabbits (reported mean approximately 1.51 mm; reported range approximately 0.80–2.20 mm). The sacculus rotundus could not be confidently visualized.

The proximal colon is relatively empty but appears within normal limits. The distal colon demonstrates a normal wall with a small amount of formed fecal material present within the lumen. Published reference values for the ascending/flexural colon are approximately 0.14±0.04 cm and distal colon approximately 0.10±0.02 cm.

Pancreas

The visualized pancreatic region appears grossly unremarkable.

Free Abdomen

No sonographic evidence of abdominal effusion, peritonitis, or lymphadenomegaly is identified. The iliac trifurcation is normal.

PRIMARY FINDINGS

- Moderately distended stomach containing heterogeneous ingesta with moderately pronounced distal acoustic shadowing
- Small non-obstructive intragastric bezoar-like aggregates

INTERPRETATION OF THE FINDINGS & FURTHER RECOMMENDATIONS

The stomach is moderately distended with heterogeneous ingesta demonstrating moderately pronounced distal acoustic shadowing, compatible with partially dehydrated gastric contents, concentrated pellet material, delayed gastric emptying, and/or mild-to-moderate gastric hypomotility/stasis.

Importantly, there is currently no convincing ultrasonographic evidence of severe gastric impaction, complete proximal gastrointestinal obstruction, obstructive ileus, or diffuse gastrointestinal tympanism.



PATIENT

Bunny Sunango

The submitted abdominal radiographs demonstrate moderate gastric ingesta without severe gastric fluid distension or marked segmental intestinal dilation.

SPECIES

Rabbit

The small intestinal tract remains largely empty and nondilated, and the cecum maintains normal wall thickness and luminal appearance without evidence of cecal impaction or severe dysbiosis-related dilation. Preservation of cecal contents and the presence of small formed fecal material within the distal colon suggest at least partial ongoing gastrointestinal transit.

BREED

Dwarf

A few small intragastric bezoar-like aggregates are present; however, these are small and non-obstructive and are considered unlikely to represent the primary cause of the current clinical signs.

SEX

Neutered male

The pyloric region could not be completely assessed, and therefore an early, partial, or intermittent proximal obstructive process cannot be entirely excluded. However, the overall ultrasonographic and radiographic appearance is considered more supportive of functional gastrointestinal hypomotility/gastric stasis rather than a surgically obstructive gastrointestinal process.

AGE

1 year

No ultrasonographic evidence of hepatic lobe torsion is identified. Additionally, despite the reported prolonged anorexia, there is no convincing sonographic evidence of severe hepatic lipidosis at this time.

WEIGHT

1147 g

The reported history of complete anorexia for 6 days should be interpreted in conjunction with the current imaging findings, as the amount and appearance of gastric content would be somewhat unusual in a rabbit with truly complete absence of food intake over that entire period. Delayed gastric emptying and/or intermittent ongoing intake may therefore be contributing factors.

INTERPRETED BY

Alicia Angosto
Guerrero, DMV,
PgDip, MSc.

Recommendations

- Continued supportive management for gastrointestinal hypomotility/stasis is recommended as clinically indicated. Rabbits with functional gastrointestinal hypomotility often improve substantially with aggressive fluid therapy, appropriate analgesia, assisted nutritional support, and prokinetic therapy when clinically appropriate.
- CBC and serum biochemistry are recommended if not already performed to investigate potential underlying systemic causes of anorexia and gastrointestinal hypomotility.
- Careful assessment for underlying stress, pain, husbandry-related, or environmental factors is also recommended, as rabbits may develop significant gastrointestinal hypomotility secondary to relatively subtle systemic or stress-related triggers.
- Thorough oral and dental examination is recommended if not already performed, as occult dental disease remains a common underlying contributor to anorexia and gastrointestinal hypomotility in rabbits, even in relatively young individuals.
- Repeat abdominal imaging may be considered if clinical deterioration occurs or if response to medical management is poor.

IMAGING PERFORMED BY

Kerri Becker

HOSPITAL NAME

Companion AH
Parsippany

REFERRING VET

Dr. Wolf

INVOICE

75556

Final diagnostic and therapeutic decisions should be made by the attending veterinarian, who can best integrate these findings with the patient's clinical status.

DATE

5/14/26



PATIENT

Bunny Sunango

SPECIES

Rabbit

BREED

Dwarf

SEX

Neutered male

AGE

1 year

WEIGHT

1147 g

INTERPRETED BY

Alicia Angosto
Guerrero, DMV,
PgDip, MSc.

**IMAGING
PERFORMED BY**

Kerri Becker

HOSPITAL NAME

Companion AH
Parsippany

REFERRING VET

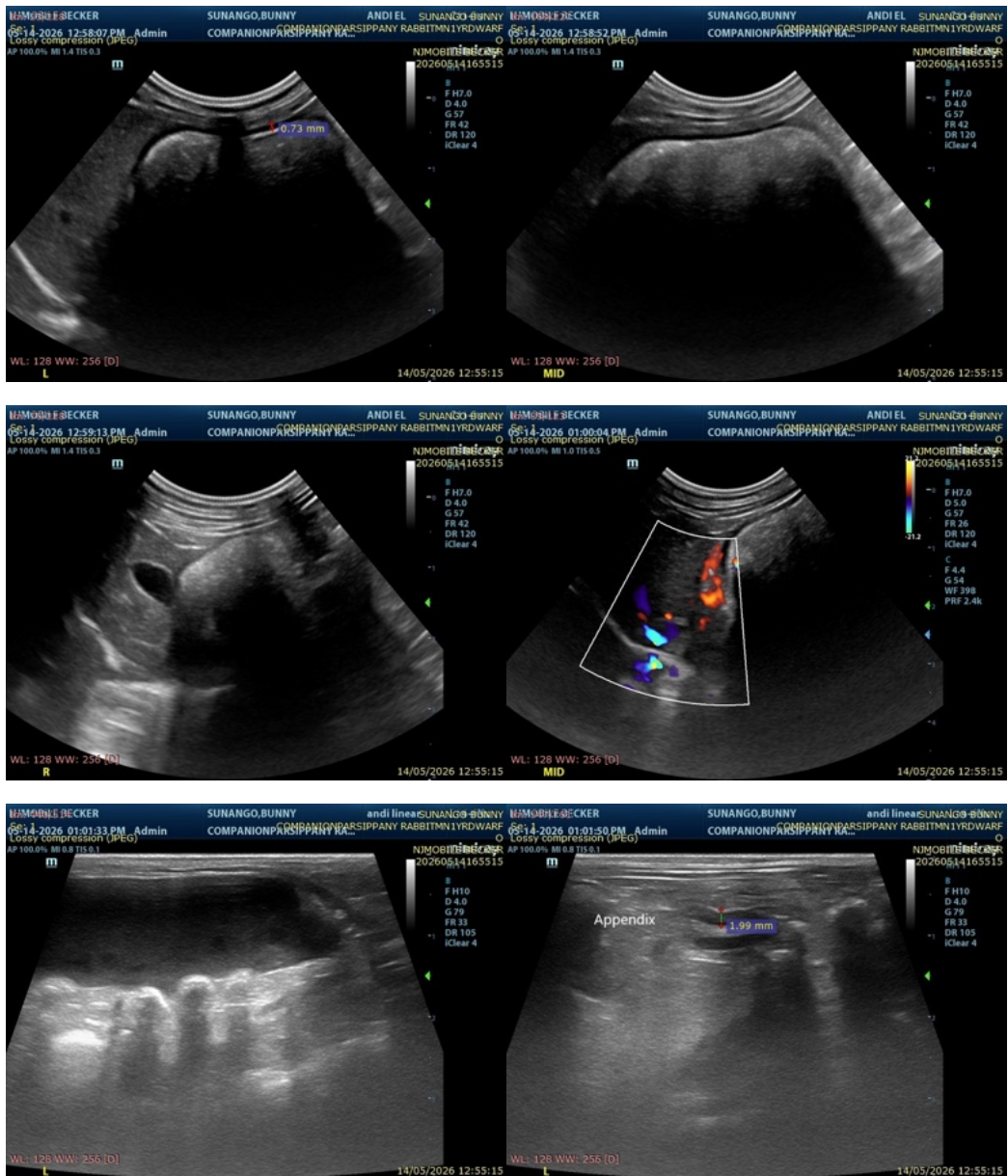
Dr. Wolf

INVOICE

75556

DATE

5/14/26





PATIENT

Bunny Sunango

SPECIES

Rabbit

BREED

Dwarf

SEX

Neutered male

AGE

1 year

WEIGHT

1147 g

INTERPRETED BY

Alicia Angosto
Guerrero, DMV,
PgDip, MSc.

**IMAGING
PERFORMED BY**

Kerri Becker

HOSPITAL NAME

Companion AH
Parsippany

REFERRING VET

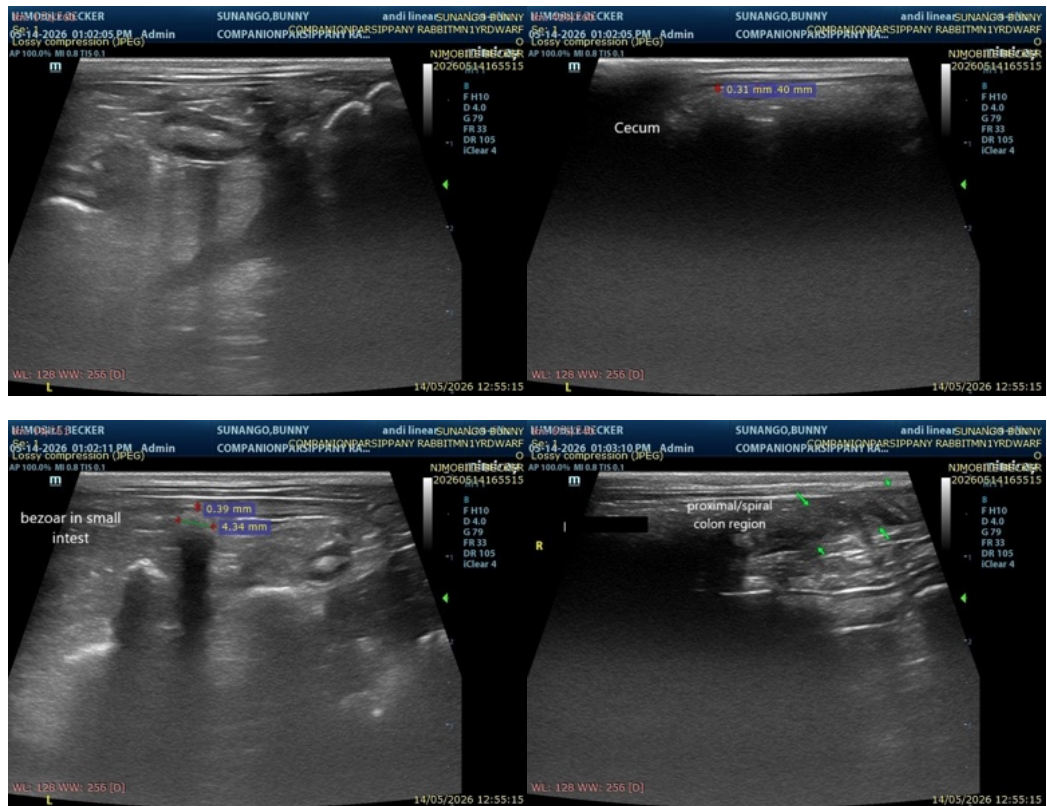
Dr. Wolf

INVOICE

75556

DATE

5/14/26



The information and recommendations provided are based on the images presented by the referring veterinarian/sonographer. No evaluation can be communicated regarding pathology that was not visible in the image/video clips provided.

Thank you for this referral. If the clinical or image interpretation does not parallel your findings or if I can be of any further assistance please contact me.

Alicia Angosto Guerrero, DMV, PgDip, MSc.

info@SonoPath.com