



PATIENT

Tux Varley

SPECIES

Feline

BREED

Domestic Shorthair

SEX

Neutered male

AGE

5 years

WEIGHT

7.9 lbs

INTERPRETED BY

Alicia Angosto
Guerrero, DMV,
PgDip, MSc.

IMAGING PERFORMED BY

Dr. Joan Kula

HOSPITAL NAME

Narrowsburg
Veterinary

REFERRING VET

Dr. Hess

INVOICE

78433

DATE

6/8/26

PRESENTING CLINICAL SIGNS

History: Chronic diarrhea, vomiting has become worse, partial response to prednisolone and B12 injection, will not eat prescription hypoallergenic diet, currently on pred 5mg EOD, will eat food, FIV/FELV positive

Abnormal PE/Chem/CBC/UA Results: Absolute Neutrophils 2059 2500 - 8500 /UL Absolute Lymphocytes 551 1200 - 8000 /UL RBC 5.3 5.92 - 9.93 1000000/UL

ULTRASONOGRAPHIC EXAMINATION OF THE ABDOMEN

Urinary System

The urinary bladder lumen is normally distended, and the urinary bladder wall appears thin and smooth. The urine is anechoic. Normal appearance of the trigone and proximal urethra is observed. There are no calculi, and no evidence of inflammatory or neoplastic changes.

The left kidney is normal in shape and size, measuring 3.62×2.38 cm, with a cortical thickness of 0.30 cm in the sagittal plane.

The right kidney is normal in shape and size, measuring 3.64×2.30 cm, with a cortical thickness of 0.32 cm in the sagittal plane.

Both kidneys demonstrate mildly increased cortical echogenicity relative to the liver parenchyma. The corticomedullary ratio is normal, and corticomedullary distinction is preserved. A mild medullary rim sign is present bilaterally. There is no evidence of pyelectasia, nephrolithiasis, or hydronephrosis.

Adrenal Glands

The adrenal glands were not confidently visualized.

Spleen

Splenic thickness is 0.68 cm. The parenchyma demonstrates normal echogenicity and fine homogeneous echotexture without focal parenchymal abnormalities. The splenic capsule is smooth and regular.

Within the left splenorenal region, there is a heterogeneous soft tissue mass measuring approximately 1.17×1.34 cm. Based on the submitted images, the lesion cannot be confidently assigned to the spleen and may represent either an exophytic splenic lesion or an enlarged regional lymph node. Color Doppler interrogation was not available for further characterization.

Liver

The liver is subjectively normal in size, with sharp edges and a regular contour. The liver parenchyma looks uniform and isoechoic compared to the falciform fat, with a normal echotexture. No hepatic lymphadenopathy is observed.



PATIENT

Tux Varley

SPECIES

Feline

BREED

Domestic Shorthair

SEX

Neutered male

AGE

5 years

WEIGHT

7.9 lbs

INTERPRETED BY

Alicia Angosto
Guerrero, DMV,
PgDip, MSc.

IMAGING PERFORMED BY

Dr. Joan Kula

HOSPITAL NAME

Narrowsburg
Veterinary

REFERRING VET

Dr. Hess

INVOICE

78433

DATE

6/8/26

The gallbladder lumen is moderately distended. The wall is thin and smooth. The contents are predominantly anechoic. The common bile duct measures 1.90–3.22 mm.

Gastrointestinal tract

The stomach is empty and folded, with a mural thickness of 1.40 mm and preserved wall layering. The pyloric wall measures 2.74 mm. The duodenal wall measures 1.63 mm. The jejunal wall measures 1.38 mm with preserved wall layering. The ileal wall measures 1.08 mm with preserved wall layering. The ileocolic junction was not confidently visualized. Mild fluid distension of several small intestinal loops is present. No evidence of gastrointestinal obstruction, foreign material, focal mural mass, loss of wall layering, or other significant structural intestinal abnormality is identified.

Pancreas

The pancreas measures approximately 6.71–7.70 mm in thickness. Pancreatic parenchyma is mildly hypoechoic relative to the surrounding mesenteric fat. The pancreatic duct measures approximately 0.74 mm in diameter. No discrete peripancreatic fat inflammation, peripancreatic fluid accumulation, or focal pancreatic mass is identified.

Free Abdomen

No abdominal effusion or peritonitis is identified.

The cranial mesenteric lymph nodes appear mildly reactive. The ileocolic lymph nodes were not confidently visualized.

PRIMARY FINDINGS

- Heterogeneous 1.17×1.34 cm soft tissue mass within the left splenorenal region of uncertain origin (splenic versus nodal).
- Mild enlargement/reactivity of the cranial mesenteric lymph nodes.
- Pancreatic hypoechogenicity with pancreatic duct prominence.

SECONDARY FINDINGS

- Mild fluid distension of several small intestinal loops.
- Subtle bilateral renal cortical hyperechogenicity with a mild medullary rim sign.

INTERPRETATION OF THE FINDINGS & FURTHER RECOMMENDATIONS

The principal abnormality identified is a 1.17×1.34 cm heterogeneous soft tissue mass within the left splenorenal region. Based on the submitted images, the lesion cannot be confidently assigned to the spleen and may instead represent an enlarged regional lymph node. Given the patient's FeLV/FIV-positive status, chronic gastrointestinal signs, and the appearance of this lesion, round cell neoplasia, particularly lymphoma, must be considered a significant differential diagnosis.



PATIENT

Tux Varley

SPECIES

Feline

BREED

Domestic Shorthair

SEX

Neutered male

AGE

5 years

WEIGHT

7.9 lbs

INTERPRETED BY

Alicia Angosto
Guerrero, DMV,
PgDip, MSc.

IMAGING PERFORMED BY

Dr. Joan Kula

HOSPITAL NAME

Narrowsburg
Veterinary

REFERRING VET

Dr. Hess

INVOICE

78433

DATE

6/8/26

The patient's concurrent hematologic abnormalities, including neutropenia, and mild anemia, may be attributable to the underlying FeLV/FIV infection status. However, when considered alongside the chronic gastrointestinal signs and the presence of the splenorenal mass, these findings further support consideration of underlying systemic disease, including round cell neoplasia such as lymphoma.

Mild cranial mesenteric lymph node reactivity is also present and may be associated with chronic gastrointestinal inflammation, pancreatopathy, or neoplastic disease.

The gastrointestinal tract is otherwise largely within normal ultrasonographic limits. No convincing sonographic evidence of infiltrative enteropathy, focal intestinal neoplasia, mechanical obstruction, or loss of intestinal wall layering is identified. However, normal intestinal ultrasonographic appearance does not exclude low-grade lymphoma or early inflammatory bowel disease, particularly in a patient receiving prednisolone therapy.

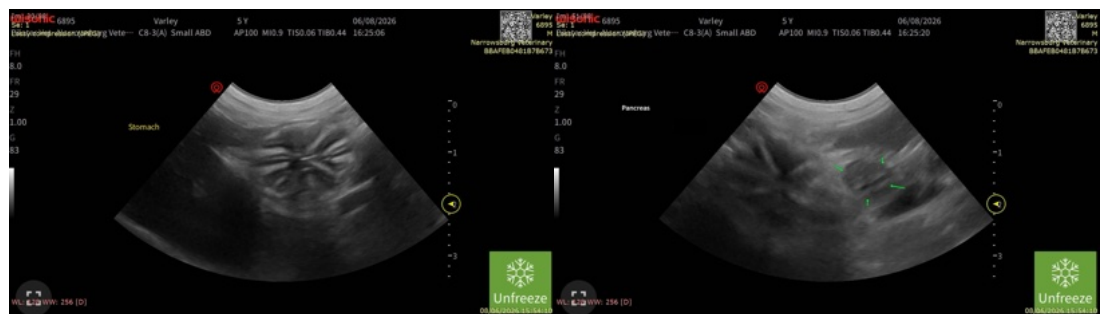Mild pancreatic hypoechogenicity and mild pancreatic duct prominence are present. These findings are nonspecific but may be compatible with mild chronic pancreatitis. No convincing sonographic evidence of clinically significant acute pancreatitis is identified.

Mild bilateral renal cortical hyperechogenicity and a mild medullary rim sign are present. These findings are nonspecific and may represent incidental change or mild chronic renal alteration.

Recommendations

- Ultrasound-guided fine-needle aspiration of the left splenorenal mass is strongly recommended, if technically feasible, for cytologic characterization.
- If cytology is nondiagnostic and clinical suspicion remains high, additional diagnostic investigation, including repeat ultrasonography, advanced imaging, or tissue biopsy, may be considered.
- Correlation with serum cobalamin, folate, feline pancreatic lipase immunoreactivity (fPLI), and any previous gastrointestinal histopathology is recommended if available.
- Further diagnostic investigation may be warranted depending on clinical progression and cytologic results.

Final diagnostic and therapeutic decisions should be made by the attending veterinarian, who can best integrate these findings with the patient's clinical status.





PATIENT

Tux Varley

SPECIES

Feline

BREED

Domestic Shorthair

SEX

Neutered male

AGE

5 years

WEIGHT

7.9 lbs

INTERPRETED BY

Alicia Angosto
Guerrero, DMV,
PgDip, MSc.

IMAGING PERFORMED BY

Dr. Joan Kula

HOSPITAL NAME

Narrowsburg
Veterinary

REFERRING VET

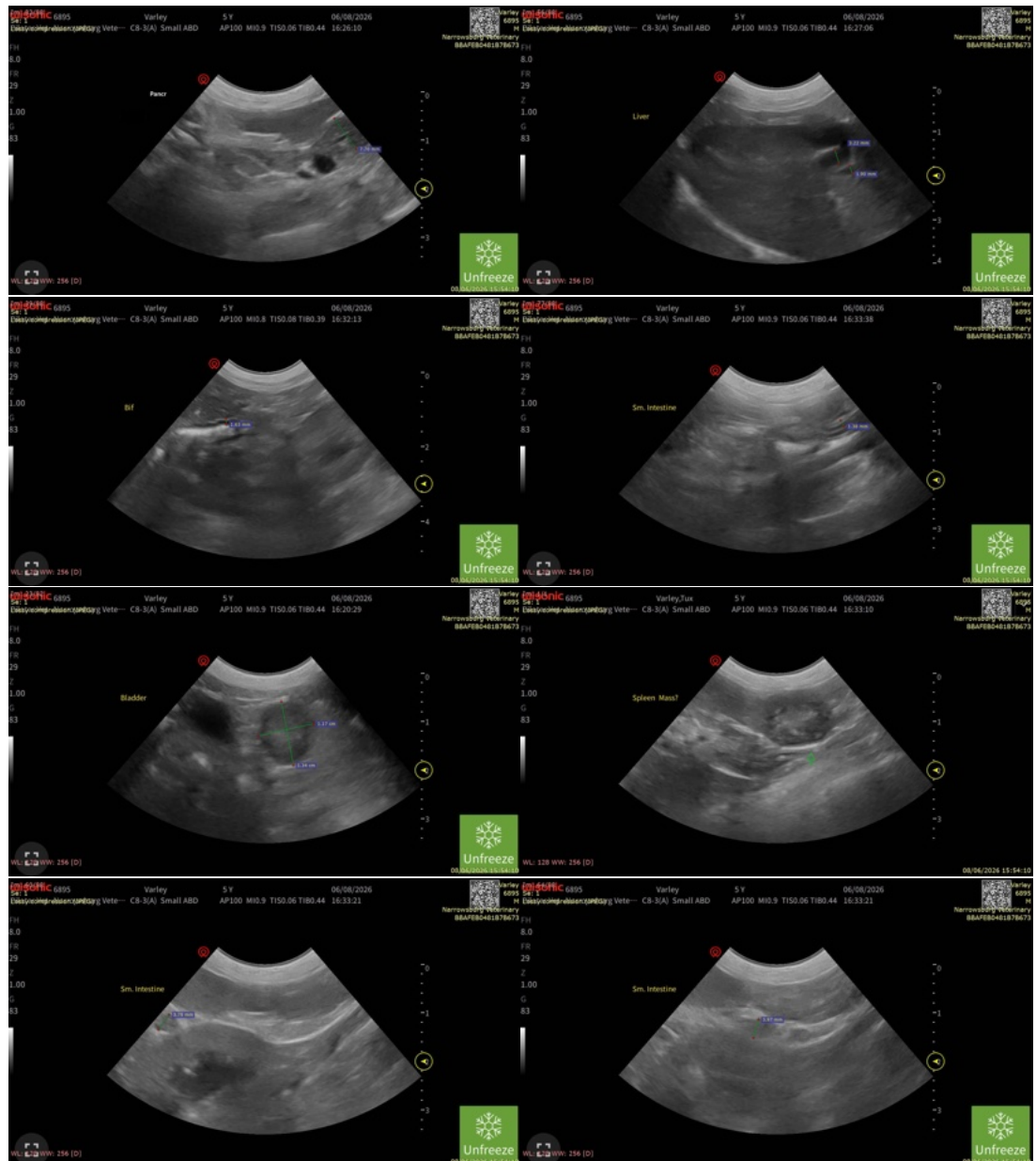
Dr. Hess

INVOICE

78433

DATE

6/8/26



The information and recommendations provided are based on the images presented by the referring veterinarian/sonographer. No evaluation can be communicated regarding pathology that was not visible in the image/video clips provided.

Thank you for this referral. If the clinical or image interpretation does not parallel your findings or if I can be of any further assistance please contact me.

Alicia Angosto Guerrero, DMV, PgDip, MSc.

info@SonoPath.com