



## PATIENT

Bethie Robinson

## SPECIES

Feline

## BREED

Domestic Shorthair

## SEX

Spayed female

## AGE

14 years

## WEIGHT

7.12 lbs

## INTERPRETED BY

Alicia Angosto  
Guerrero, DMV,  
PgDip, MSc.

## IMAGING PERFORMED BY

Robert Murphie

## HOSPITAL NAME

VCA Anderson's  
Corner AH

## REFERRING VET

Dr. Murphie

## INVOICE

78791

## DATE

6/17/26

## PRESENTING CLINICAL SIGNS

History: Was around 11.5 pounds last year, progressing weight loss, bloodwork unremarkable, eating and drinking well to increased. Prednisolone trial for possible IBD/infiltrative dz had limited effect, continued to lose some weight. I can palpate a suspect GI mass. Patient stable.

Abnormal PE/Chem/CBC/UA Results: Bloodwork last month fairly unremarkable, but neutrophils 14,508. Thyroid normal. Radiograph and interpretation fairly unremarkable.

## ULTRASONOGRAPHIC EXAMINATION OF THE ABDOMEN

### Urinary System

The urinary bladder is normally distended, and the wall of the urinary bladder appears thin and smooth. The urine is anechoic. The trigone and proximal urethra have a normal ultrasonographic appearance. No calculi are identified, and there is no sonographic evidence of inflammatory or neoplastic disease.

The left kidney is normal in shape and size, measuring 3.78×1.75 cm, with a cortical thickness of 0.29 cm in the sagittal plane.

The right kidney is normal in shape and size, measuring 3.62×2.01 cm, with a cortical thickness of 0.30 cm in the sagittal plane.

Both kidneys demonstrate normal cortical echogenicity. Corticomedullary distinction and corticomedullary ratio are preserved. There is no evidence of pyelectasia, nephrolithiasis, or hydronephrosis. Color Doppler demonstrates a normal vascular pattern.

### Adrenal Glands

Both adrenal glands show normal shape and echogenicity. Dorsoventral diameters measured in the sagittal plane: The left adrenal gland measures 0.43 cm at the cranial pole and 0.42 cm at the caudal pole. Several focus of mineralization are present. The right adrenal gland measures 0.32 cm at the cranial pole and 0.33 cm at the caudal pole.

### Spleen

Splenic thickness is 0.87 cm. The parenchyma demonstrates normal echogenicity and fine homogeneous echotexture without focal parenchymal abnormalities. The splenic capsule is smooth and regular.

### Liver

The liver is subjectively normal in size, with sharp edges and a regular contour. The liver parenchyma looks uniform and isoechoic compared to the falciform fat, with a normal echotexture. No hepatic lymphadenopathy is observed.

The gallbladder is normally distended. The wall is thin and smooth. The contents are predominantly anechoic with a small amount of biliary sludge. The common bile duct measures 1.67–2.46 mm.



## PATIENT

Bethie Robinson

## SPECIES

Feline

## BREED

Domestic Shorthair

## SEX

Spayed female

## AGE

14 years

## WEIGHT

7.12 lbs

## INTERPRETED BY

Alicia Angosto  
Guerrero, DMV,  
PgDip, MSc.

## IMAGING PERFORMED BY

Robert Murphie

## HOSPITAL NAME

VCA Anderson's  
Corner AH

## REFERRING VET

Dr. Murphie

## INVOICE

78791

## DATE

6/17/26

## *Gastrointestinal tract*

The stomach is empty and folded. Gastric wall thickness measures 1.32 mm, and normal wall layering is preserved.

The pylorus measures 3.64 mm and maintains normal wall layering.

The duodenum measures 2.17 mm in thickness and maintains normal wall layering.

The jejunum measures 2.67 mm in thickness. Mucosal thickness measures 1.55 mm, submucosal thickness 0.74 mm, and muscularis propria thickness 0.38 mm. Wall layering is preserved.

The ileum measures 1.95 mm in thickness. Mucosal thickness measures 0.54 mm, submucosal thickness 0.65 mm, and muscularis propria thickness 0.34 mm. Wall layering is preserved. The ileocecal junction could not be identified.

A focal segment of small intestine, suspected to represent distal small intestine/ileum, demonstrates severe circumferential mural thickening measuring up to 1.07 cm, with complete loss of normal wall layering and formation of a mass-like lesion measuring approximately 4.17×2.34 cm. The lesion contains multifocal mineralized foci and probable areas of mucosal ulceration. Moderate internal vascularity is present. Mild surrounding omental reactivity is also identified.

The colon measures 0.85–1.03 mm in thickness and contains formed fecal material within the descending colon.

## *Pancreas*

The pancreas measures approximately 7.85 mm in thickness. Pancreatic parenchyma is isoechoic relative to the surrounding fat. No peripancreatic fluid accumulation, regional fat hyperechogenicity, or other ultrasonographic evidence of active pancreatitis is identified.

## *Free Abdomen*

No sonographic evidence of abdominal effusion, peritonitis, or lymphadenomegaly is identified. The iliac trifurcation is normal.

## PRIMARY FINDINGS

- Large infiltrative small intestinal mass (approximately 4.17×2.34 cm) with complete loss of mural layering. Internal mineralization and probable ulceration within the mass.
- Mild regional omental reaction.

## SECONDARY FINDINGS

- Small amount of biliary sludge.
- Incidental mineralization within the left adrenal gland.



## PATIENT

Bethie Robinson

## SPECIES

Feline

## BREED

Domestic Shorthair

## SEX

Spayed female

## AGE

14 years

## WEIGHT

7.12 lbs

## INTERPRETED BY

Alicia Angosto  
Guerrero, DMV,  
PgDip, MSc.

## IMAGING PERFORMED BY

Robert Murphie

## HOSPITAL NAME

VCA Anderson's  
Corner AH

## REFERRING VET

Dr. Murphie

## INVOICE

78791

## DATE

6/17/26

## INTERPRETATION OF THE FINDINGS & FURTHER RECOMMENDATIONS

A large infiltrative small intestinal mass is identified, most likely arising from the distal small intestine, with marked mural thickening, complete loss of normal wall layering, internal vascularity, probable ulceration, and associated regional omental reaction. These findings are highly concerning for an aggressive intestinal neoplasm.

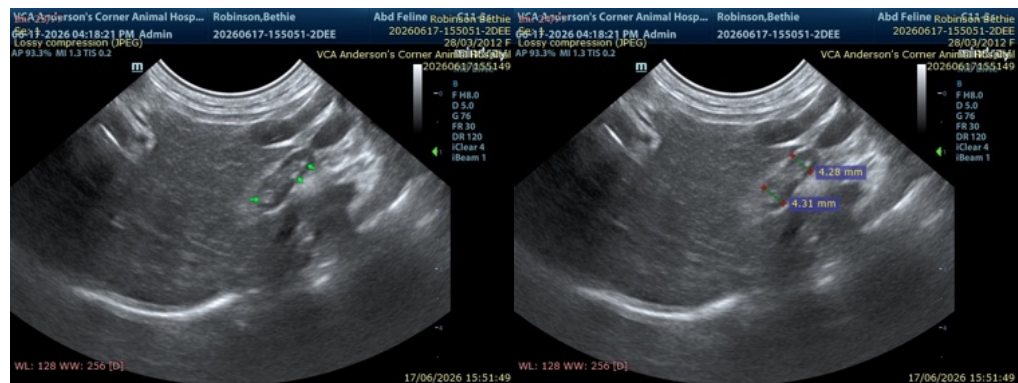
The primary differential diagnosis is intestinal adenocarcinoma or intestinal lymphoma (high-grade lymphoma). Other neoplastic processes, including leiomyosarcoma, gastrointestinal stromal tumor (GIST), mast cell tumor, or other mesenchymal neoplasms, are considered less likely but cannot be excluded ultrasonographically.

The presence of mineralization and suspected ulceration within the lesion may further support adenocarcinoma or another aggressive intestinal neoplasm, although these features are not entirely specific.

No convincing ultrasonographic evidence of metastatic abdominal lymphadenopathy, abdominal effusion, or overt metastatic disease is identified within the abdomen at the time of examination.

### Recommendations

- Definitive diagnosis would require tissue sampling, ideally through surgical excision and histopathology if clinically appropriate.
- Thoracic imaging may be considered for staging purposes if further diagnostic investigation or treatment is being pursued.
- Given the patient's age, clinical status, and owner goals, final diagnostic and therapeutic decisions should be made by the attending veterinarian, who can best integrate these findings with the patient's clinical status.





**PATIENT**

Bethie Robinson

**SPECIES**

Feline

**BREED**

Domestic Shorthair

**SEX**

Spayed female

**AGE**

14 years

**WEIGHT**

7.12 lbs

**INTERPRETED BY**

Alicia Angosto  
Guerrero, DMV,  
PgDip, MSc.

**IMAGING  
PERFORMED BY**

Robert Murphie

**HOSPITAL NAME**

VCA Anderson's  
Corner AH

**REFERRING VET**

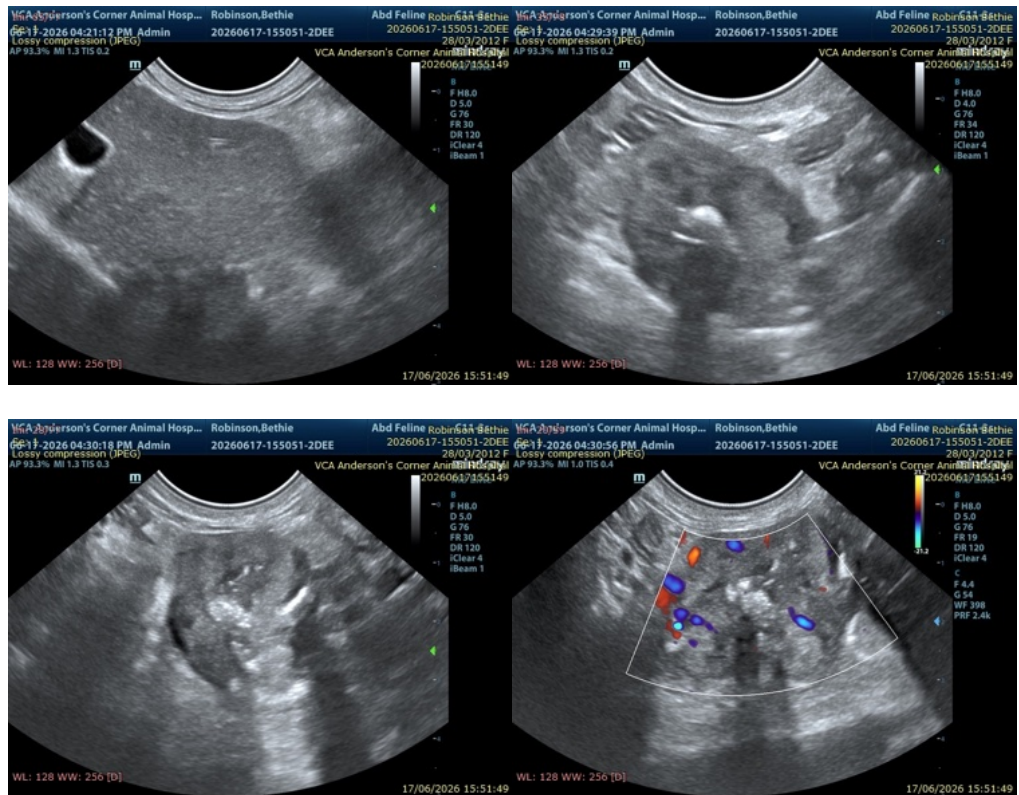
Dr. Murphie

**INVOICE**

78791

**DATE**

6/17/26



The information and recommendations provided are based on the images presented by the referring veterinarian/sonographer. No evaluation can be communicated regarding pathology that was not visible in the image/video clips provided.

Thank you for this referral. If the clinical or image interpretation does not parallel your findings or if I can be of any further assistance please contact me.

**Alicia Angosto Guerrero, DMV, PgDip, MSc.**

[info@SonoPath.com](mailto:info@SonoPath.com)