



## PATIENT

Batman Rhoads

## SPECIES

Feline

## BREED

DSH

## SEX

MN

## AGE

8 years

## WEIGHT

8.26 kg

## INTERPRETED BY

Alicia Angosto  
Guerrero, DMV,  
PgDip, MSc.

## IMAGING PERFORMED BY

Dr. Patrick Hennigan

## HOSPITAL NAME

Mattydale Animal  
Hospital

## REFERRING VET

Dr. Patrick Hennigan

## INVOICE

11911

## DATE

5/8/2026

## PRESENTING CLINICAL SIGNS

Presented for weight loss April 29th. Owner reports still eating canned food and drinking normally. No known v/d. PE revealed a 10-pound weight loss since December 2025. Slight tartar on caudal teeth but no obvious oral lesions or gingivitis. Mild elevation of ALT and ALP. Lost additional 11 ounces in last 9 days. Still BCS 5/5.

Abnormal PE/Chem/CBC/UA Results: CBC: decr Neuts (2312), decr Lymphs (1154) Chem: inc ALT (158), inc ALP (281) TT4: 1.1.

## ULTRASONOGRAPHIC EXAMINATION OF THE ABDOMEN

### Urinary System

The bladder lumen is normally distended, and the wall of the urinary bladder appears thin and smooth. The urine is predominantly anechoic with scant suspended echoes. Normal appearance of the bladder neck and proximal urethra. There are no calculi and no evidence of inflammatory or neoplastic changes.

The left kidney is normal in shape and size: 4.34×2.29 cm, and the thickness of the cortex is 0.36 cm in the sagittal plane.

The right kidney is normal in shape and size: 3.96×2.47 cm, and the thickness of the cortex is 0.40 cm in the sagittal plane.

Both kidneys: The renal cortices are mildly hyperechoic. The corticomedullary ratio is normal and corticomedullary definition is preserved. There is no evidence of pyelectasia, nephrolithiasis, or hydronephrosis. Doppler color evaluation shows a normal vascular pattern.

### Adrenal Glands

Dorsoventral diameters measured in the sagittal plane: the left adrenal gland measures 0.35 cm at the cranial pole and 0.35 cm at the caudal pole, which is within normal limits for a cat. The right adrenal gland is not confidently visualized.

### Spleen

Splenic thickness is 0.89 cm. The parenchyma demonstrates normal echogenicity and fine homogeneous echotexture without focal parenchymal abnormalities. The splenic capsule is smooth and regular.

### Liver

The liver is subjectively normal in size, with sharp edges and a regular contour. The hepatic parenchyma appears mildly hyperechoic relative to the falciform fat, with otherwise normal echotexture. No hepatic lymphadenopathy is observed.

The gallbladder lumen is normally distended. The wall is thin and the contents contain a moderate amount of biliary sludge. The common bile duct measures 2.81 mm in diameter, which is mildly dilated for a cat.

### Gastrointestinal Tract



## PATIENT

Batman Rhoads

## SPECIES

Feline

## BREED

DSH

## SEX

MN

## AGE

8 years

## WEIGHT

8.26 kg

## INTERPRETED BY

Alicia Angosto  
Guerrero, DMV,  
PgDip, MSc.

## IMAGING PERFORMED BY

Dr. Patrick Hennigan

## HOSPITAL NAME

Mattydale Animal  
Hospital

## REFERRING VET

Dr. Patrick Hennigan

## INVOICE

11911

## DATE

5/8/2026

The stomach is empty and folded, with gastric mural thickness measuring 1.16 mm and preserved wall layering.

The pylorus measures 3.01 mm in wall thickness. The duodenum measures 2.20 mm in wall thickness.

The jejunum measures 1.82–1.90 mm in total wall thickness, with mucosal, submucosal, and muscularis propria thicknesses of 0.88 mm, 0.63 mm, and 0.38 mm, respectively. Wall layering is preserved. The muscularis-to-mucosa ratio is approximately 0.43, which is mildly increased for a cat.

The ileum measures 2.09 mm in total wall thickness, with mucosal, submucosal, and muscularis propria thicknesses of 0.66 mm, 0.84 mm, and 0.37 mm, respectively. Wall layering is preserved.

The ileocecal junction was not confidently visualized.

No evidence of gastrointestinal obstruction, focal mural mass lesion, inflammatory change, ileus, or foreign material is identified.

The colon measures 0.91 mm in wall thickness and is minimally distended.

### **Pancreas**

The pancreas measures 6.83 mm in thickness. Pancreatic parenchyma is isoechoic relative to the adjacent omental fat. The pancreatic duct measures 0.77 mm in diameter, which is mildly prominent for a cat. No hyperechoic peripancreatic fat or free fluid is identified.

### **Free Abdomen**

No sonographic evidence of abdominal effusion, peritonitis, or lymphadenomegaly is identified. The iliac trifurcation is normal.

### **PRIMARY FINDINGS**

- Hepatic hyperechogenicity.
- Moderate biliary sludge.
- Mildly increased jejunal muscularis-to-mucosa ratio.

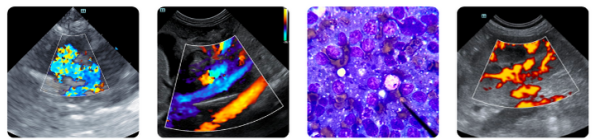
### **SECONDARY FINDINGS**

- Subtle diffuse renal cortical hyperechogenicity.

### **INTERPRETATION OF THE FINDINGS & FURTHER RECOMMENDATIONS**

The most clinically significant ultrasonographic abnormality is mild diffuse hepatic hyperechogenicity associated with moderate biliary sludge. These findings may reflect developing hepatic lipidosis. The common bile duct measures 2.81 mm in diameter. Reported upper reference limits for the feline common bile duct are generally approximately 3 mm or less, particularly in the absence of hyperbilirubinemia or obstructive disease. Therefore, this measurement is considered within the upper limits of normal to minimally prominent, without convincing ultrasonographic evidence of clinically significant extrahepatic biliary obstruction.

The pancreatic duct measures 0.77 mm in diameter. Mild prominence of the pancreatic duct may occur in older cats and may also be seen with chronic pancreatic remodeling; however, no additional ultrasonographic evidence of clinically significant pancreatitis is identified, including normal pancreatic



**PATIENT**

Batman Rhoads

**SPECIES**

Feline

**BREED**

DSH

**SEX**

MN

**AGE**

8 years

**WEIGHT**

8.26 kg

**INTERPRETED BY**

Alicia Angosto  
Guerrero, DMV,  
PgDip, MSc.

**IMAGING PERFORMED BY**

Dr. Patrick Hennigan

**HOSPITAL NAME**

Mattydale Animal  
Hospital

**REFERRING VET**

Dr. Patrick Hennigan

**INVOICE**

11911

**DATE**

5/8/2026

parenchyma, absence of peripancreatic hyperechoic fat, free fluid, focal pancreatic mass effect, or marked pancreatic enlargement.

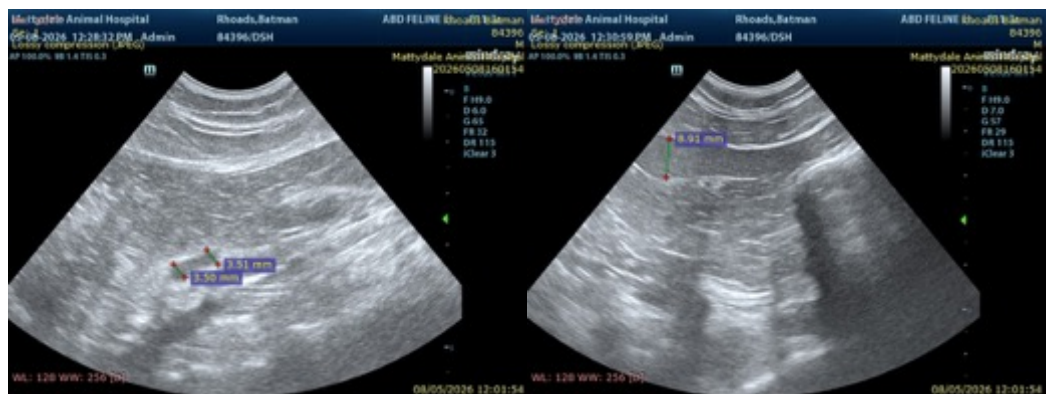The jejunal muscularis propria measures 0.38 mm and the mucosa measures 0.88 mm, resulting in a muscularis-to-mucosa ratio of approximately 0.43. Although this is mildly above traditionally cited normal ratios in cats (generally <0.4), the absolute intestinal wall thickness remains normal, and mural layering is preserved. There are no associated abnormalities such as intestinal hypomotility, mesenteric inflammatory change, abdominal lymphadenopathy, focal mural thickening, or obstructive pattern. Therefore, there are no findings to support clinically significant inflammatory bowel disease or alimentary lymphoma based on ultrasound alone.

No ultrasonographic evidence of aggressive neoplasia, severe infiltrative gastrointestinal disease, metastatic disease, or advanced organ dysfunction is identified at this time.

**Recommendations**

- Correlation with current caloric intake and ongoing body weight monitoring is strongly recommended, as the ultrasonographic hepatic changes may reflect developing hepatic lipidosis despite reported continued appetite.
- Serum cobalamin and folate assessment may be considered given the history of marked weight loss and chronic gastrointestinal concerns.
- Repeat serum biochemistry, including liver enzymes and bilirubin, is recommended to monitor progression or resolution of the hepatobiliary changes.
- Empirical hepatic support therapy (for example SAME/silybin-based hepatoprotectants) may be considered.
- If weight loss continues or liver enzyme elevations progress despite supportive management, additional investigation for underlying causes of secondary hepatic lipidosis may be warranted, including repeat abdominal ultrasound and consideration of gastrointestinal investigation/biopsy if clinically indicated.

Final diagnostic and therapeutic decisions should be made by the attending veterinarian, who can best integrate these findings with the patient's clinical status.





## PATIENT

Batman Rhoads

## SPECIES

Feline

## BREED

DSH

## SEX

MN

## AGE

8 years

## WEIGHT

8.26 kg

## INTERPRETED BY

Alicia Angosto  
Guerrero, DMV,  
PgDip, MSc.

## IMAGING PERFORMED BY

Dr. Patrick Hennigan

## HOSPITAL NAME

Mattydale Animal  
Hospital

## REFERRING VET

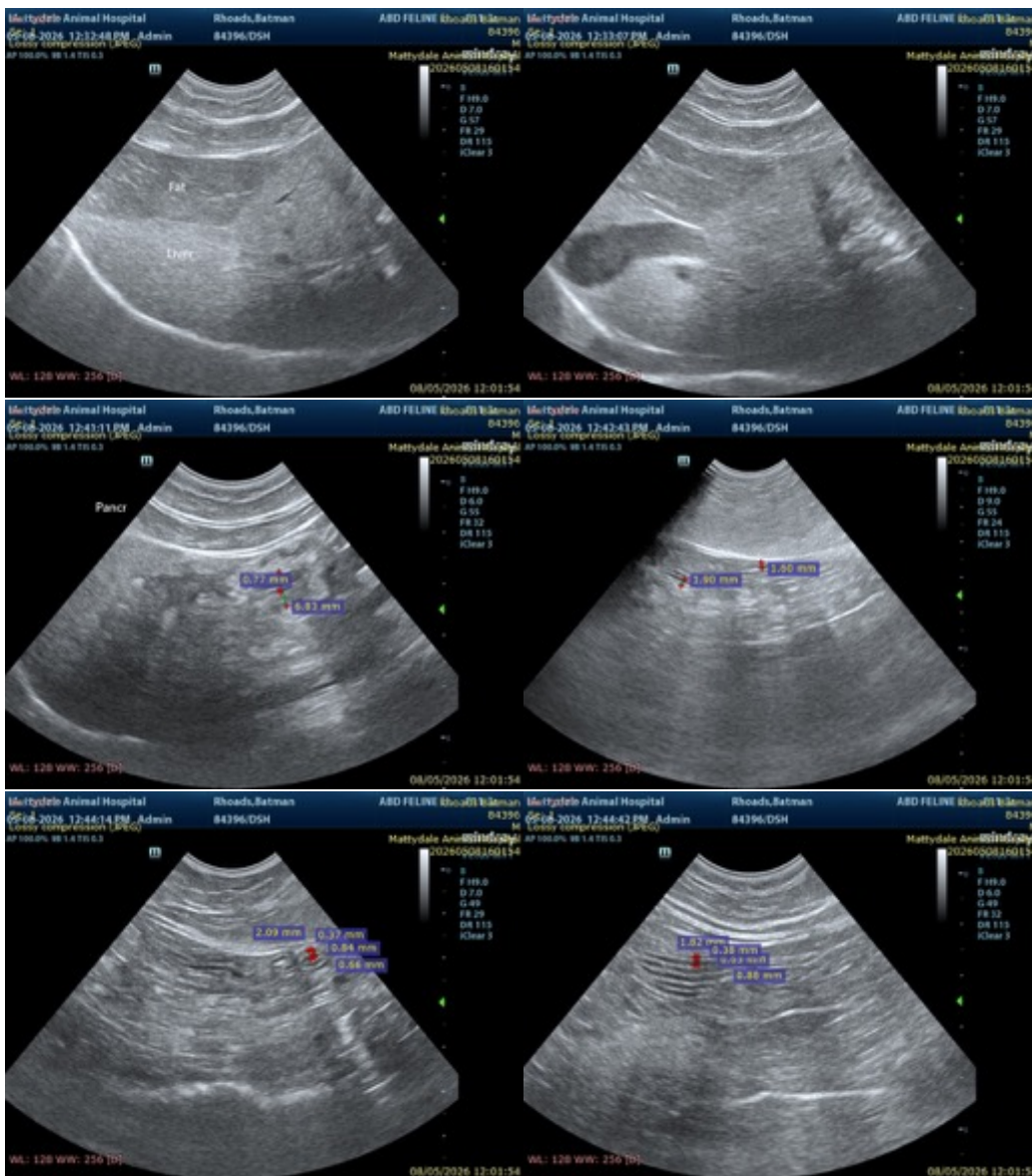
Dr. Patrick Hennigan

## INVOICE

11911

## DATE

5/8/2026



The information and recommendations provided are based on the images presented by the referring veterinarian/sonographer. No evaluation can be communicated regarding pathology that was not visible in the image/video clips provided.

Thank you for this referral. If the clinical or image interpretation does not parallel your findings or if I can be of any further assistance please contact me.

Alicia Angosto Guerrero, DMV, PgDip, MSc.

[info@SonoPath.com](mailto:info@SonoPath.com)