



<b>PATIENT</b>	<b>PRESENTING CLINICAL SIGNS</b>
Meatball Geonnettii	P has had intermittent loose stool and some inappropriate urination at home. Precautionary u/s for possible IBD vs other
<b>SPECIES</b>	Abnormal PE/Chem/CBC/UA Results: WNL
Feline	<b>ULTRASONOGRAPHIC EXAMINATION OF THE ABDOMEN</b>
<b>BREED</b>	<b>Urinary System</b>
DSH	The bladder lumen is normally distended, and the wall of the urinary bladder appears thin and smooth. The urine is anechoic. Normal appearance of the bladder neck and proximal urethra. There are no calculi and no evidence of inflammatory or neoplastic changes.
<b>SEX</b>	
Neutered Male	The left kidney is normal in shape and size: 3.96×2.55 cm, and the thickness of the cortex is 0.38 cm in the sagittal plane.
<b>AGE</b>	
4 Years	The right kidney is normal in shape and size: 3.79×2.03 cm, and the thickness of the cortex is 0.36 cm in the sagittal plane.
<b>WEIGHT</b>	Both kidneys: The renal cortices are isoechoic compared to the liver parenchyma. The corticomedullary ratio is normal and corticomedullary definition is preserved. Mild medullary rim sign is present bilaterally. There is no evidence of pyelectasia, nephrolithiasis, or hydronephrosis. Doppler color evaluation shows a normal vascular pattern.
<b>INTERPRETED BY</b>	<b>Adrenal Glands</b>
Alicia Angosto Guerrero, DMV, PgDip, MSc.	Dorsoventral diameters measured in the sagittal plane: The left adrenal gland measures 0.30 cm at the cranial pole and 0.29 cm at the caudal pole. The right adrenal gland is not confidently visualized.
<b>IMAGING PERFORMED BY</b>	<b>Spleen</b>
Dr. Jones	Splenic thickness is 0.66 cm. The parenchyma demonstrates normal echogenicity and fine homogeneous echotexture without focal parenchymal abnormalities. The splenic capsule is smooth and regular.
<b>HOSPITAL NAME</b>	<b>Liver</b>
Northwind Animal Hospital	The liver is subjectively normal in size, with sharp edges and a regular contour. The liver parenchyma looks uniform and isoechoic compared to the falciform fat, with a normal echotexture. No hepatic lymphadenopathy is observed.
<b>REFERRING VET</b>	
Dr. Jones	The gallbladder lumen is normally distended. The wall is thin and the contents are primarily anechoic with a small amount of biliary sludge. No evident dilation of the cystic duct or common bile duct is observed.
<b>INVOICE</b>	<b>Gastrointestinal Tract</b>
15929	
<b>DATE</b>	
05/07/26	The stomach is markedly distended with ingesta. Gastric mural thickness measures 1.04 mm, with preserved wall layering.



<b>PATIENT</b>	The jejunum measures 2.86 mm in total wall thickness, with mucosal, submucosal, and muscularis propria thicknesses of 1.68 mm, 0.56 mm, and 0.39 mm, respectively. Wall layering is preserved. The muscularis-to-mucosa ratio is approximately 0.23, which is within normal limits for a cat.
Meatball Geonnettii	
<b>SPECIES</b>	The ileum measures 1.45 mm in total wall thickness, with mucosal, submucosal, and muscularis propria thicknesses of 0.53 mm, 0.53 mm, and 0.39 mm, respectively. Wall layering is preserved.
Feline	
<b>BREED</b>	The ileocecal junction measures 2.80 mm in total wall thickness, with mucosal thickness measuring 1.04 mm and muscularis propria thickness measuring 0.94 mm. Wall layering is preserved. The muscularis-to-mucosa ratio at the ileocecal junction is mildly increased.
DSH	
<b>SEX</b>	No evidence of gastrointestinal obstruction, focal mural mass lesion, mechanical ileus, or foreign material is identified.
Neutered Male	
<b>AGE</b>	The colon measures 0.86 mm in wall thickness and contains a small amount of formed fecal material within the descending segment.
4 Years	
<b>WEIGHT</b>	<b>Pancreas</b>
11.2 lbs	The pancreas measures 5.97 mm in thickness. Pancreatic parenchyma is isoechoic relative to the adjacent omental fat. The pancreatic duct measures 0.74 mm in diameter, which is mildly prominent for a cat. No hyperechoic peripancreatic fat or free fluid is identified.
<b>INTERPRETED BY</b>	<b>Free Abdomen</b>
Alicia Angosto Guerrero, DMV, PgDip, MSc.	No abdominal effusion or diffuse peritonitis is observed. The cranial mesenteric lymph node measures 4.23 mm in thickness, which is within normal limits for a cat. The ileocecal lymph nodes are not confidently visualized, although the surrounding region appears unremarkable. The iliac trifurcation lymph nodes are within normal limits.
<b>IMAGING PERFORMED BY</b>	<b>PRIMARY FINDINGS</b>
Dr. Jones	<ul style="list-style-type: none"> <li>Mildly increased muscularis-to-mucosa ratio at the ileocecal junction with preserved wall layering.</li> </ul>
<b>HOSPITAL NAME</b>	<b>SECONDARY FINDINGS</b>
Northwind Animal Hospital	<ul style="list-style-type: none"> <li>Bilateral medullary rim sign.</li> <li>Small amount of biliary sludge.</li> </ul>
<b>REFERRING VET</b>	<b>INTERPRETATION OF THE FINDINGS &amp; FURTHER RECOMMENDATIONS</b>
Dr. Jones	No sonographic evidence of clinically significant infiltrative, obstructive, or severe inflammatory gastrointestinal disease is identified at this time. Mild increased muscularis prominence at the ileocecal junction is present; however, wall layering remains preserved, the change is focal and mild, and there are no associated ultrasonographic abnormalities such as diffuse muscularis thickening, intestinal hypomotility, mesenteric inflammatory change, or abdominal lymphadenopathy. In isolation, this finding is nonspecific and may represent mild/reactive change or physiologic variation rather than clinically significant enteropathy.
<b>INVOICE</b>	
15929	
<b>DATE</b>	
05/07/26	



## PATIENT

Meatball Geonnettii

The remaining evaluated intestinal segments are within normal ultrasonographic limits, including a normal jejunal muscularis-to-mucosa ratio.

## SPECIES

Feline

The mild bilateral medullary rim sign is a nonspecific finding that may be incidental in cats and is not associated with additional evidence of clinically significant renal disease in this examination.

## BREED

DSH

No sonographic abnormalities of the urinary tract are identified to explain the reported inappropriate urination.

## SEX

Neutered Male

## Recommendations

- Conservative clinical monitoring and dietary management.
- Consideration could be given to fecal testing, serum cobalamin/folate assessment, and gastrointestinal diet trial as clinically indicated.
- Repeat abdominal ultrasound may be considered if clinical signs worsen or if additional signs such as weight loss, vomiting, hyporexia, or progressive diarrhea develop.

## AGE

4 Years

Final diagnostic and therapeutic decisions should be made by the attending veterinarian, who can best integrate these findings with the patient's clinical status.

## WEIGHT

11.2 lbs

## INTERPRETED BY

Alicia Angosto  
Guerrero, DMV,  
PgDip, MSc.

## IMAGING PERFORMED BY

Dr. Jones

## HOSPITAL NAME

Northwind Animal  
Hospital

## REFERRING VET

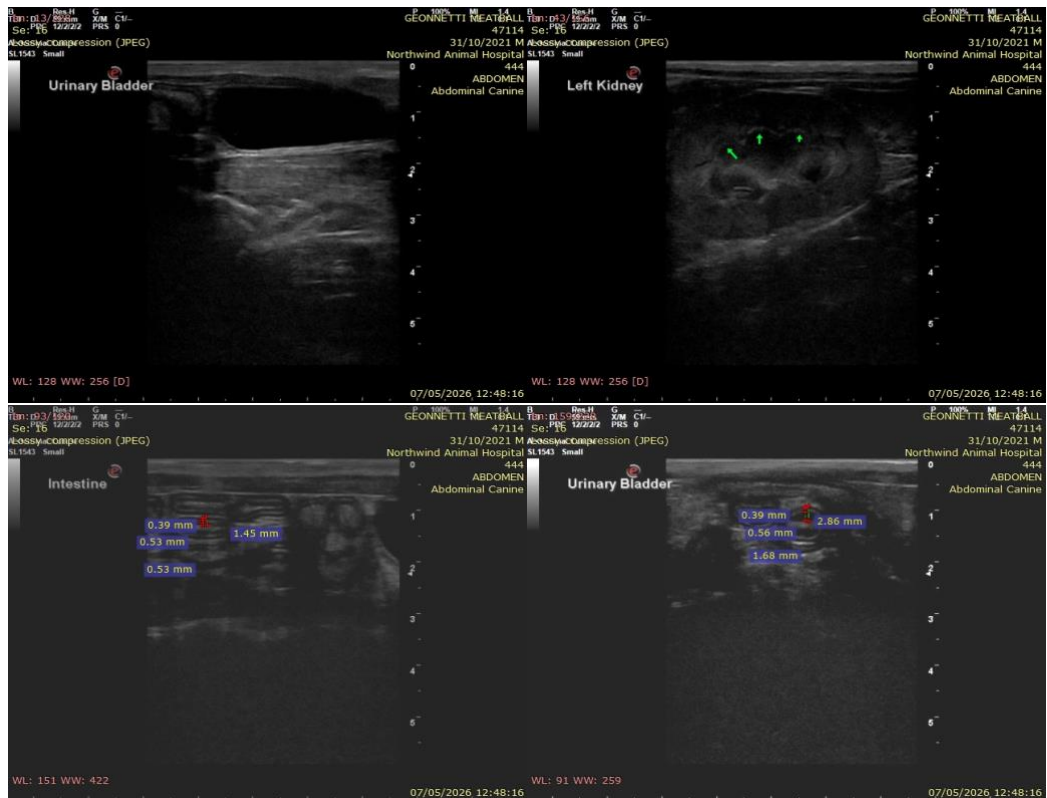
Dr. Jones

## INVOICE

15929

## DATE

05/07/26





**PATIENT**

Meatball Geonnettii

**SPECIES**

Feline

**BREED**

DSH

**SEX**

Neutered Male

**AGE**

4 Years

**WEIGHT**

11.2 lbs

**INTERPRETED BY**

Alicia Angosto  
Guerrero, DMV,  
PgDip, MSc.

**IMAGING  
PERFORMED BY**

Dr. Jones

**HOSPITAL NAME**

Northwind Animal  
Hospital

**REFERRING VET**

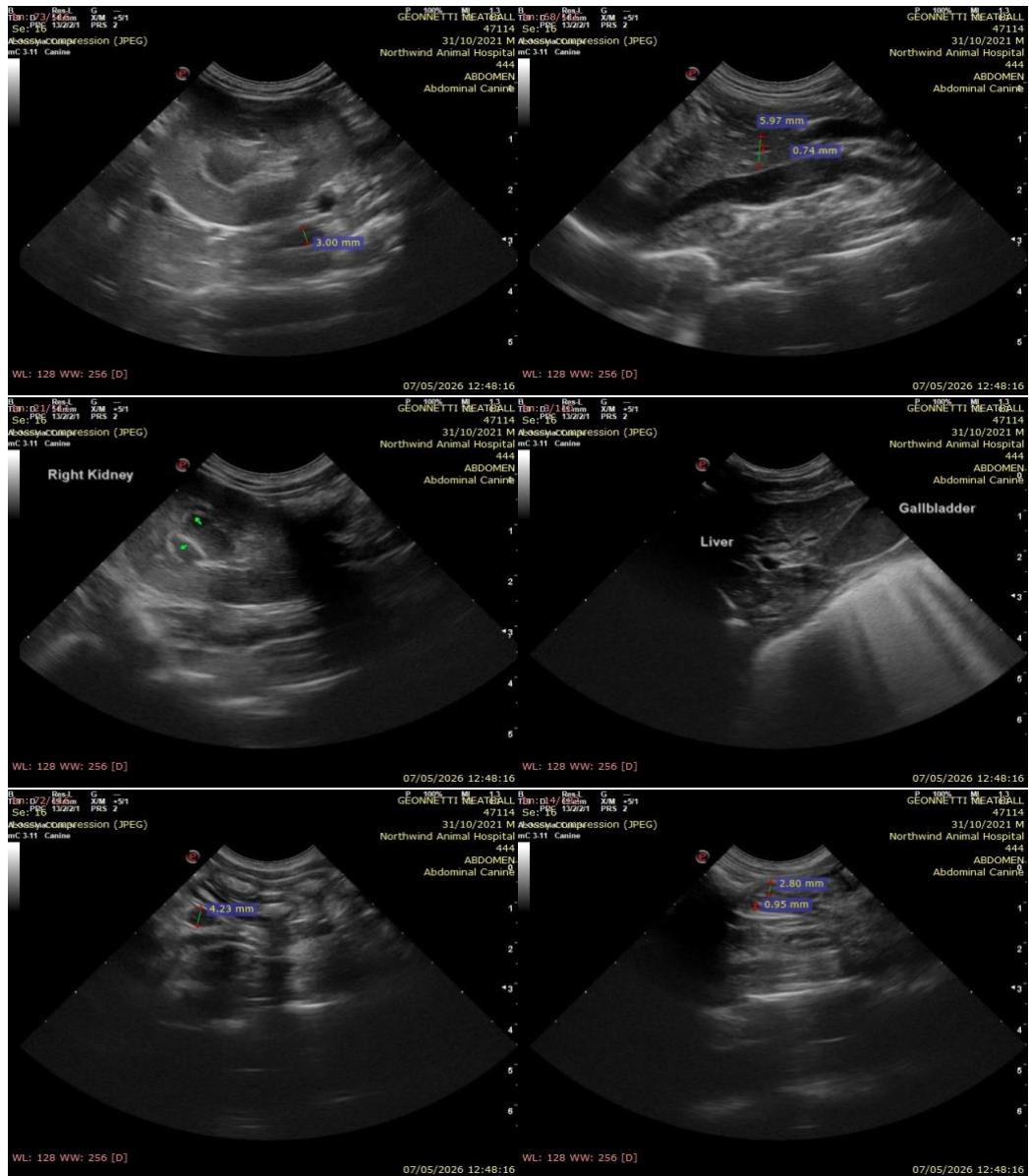
Dr. Jones

**INVOICE**

15929

**DATE**

05/07/26



The information and recommendations provided are based on the images presented by the referring veterinarian/sonographer. No evaluation can be communicated regarding pathology that was not visible in the image/video clips provided.

Thank you for this referral. If the clinical or image interpretation does not parallel your findings or if I can be of any further assistance please contact me.

Alicia Angosto Guerrero, DMV, PgDip, MSc.

[info@SonoPath.com](mailto:info@SonoPath.com)