



PATIENT

Figaro Martins

SPECIES

Feline

BREED

Domestic Shorthair

SEX

Neutered male

AGE

6 years

WEIGHT

7.8 lb

INTERPRETED BY

Alicia Angosto
Guerrero, DMV,
PgDip, MSc.

IMAGING PERFORMED BY

Christina Wagner

HOSPITAL NAME

Angeles Clinic for
Animals

REFERRING VET

Dr. Wagner

INVOICE

75245

DATE

5/6/26

PRESENTING CLINICAL SIGNS

History: Pet presented 4/24/26 for evaluation of seeming thin, reported PU/PD. Convenia was administered when UA at the time had WBC and cocci along with azotemia. Abnormal PE/Chem/CBC/UA Results: PE - 2/6 left parasternal murmur, BCS 4/9 CBC -HT 25.4%, non-regenerative, normocytic, normochromic Chem --Glc 69 --SDMA 20, Creat 3.2, BUN 79 --Phos 9.5, Ca 9.0 --K 3.4 UA - USG 1.009, 15-20 WBC, moderate cocci, occ fine granular casts Cardiopet proBNP 37

ULTRASONOGRAPHIC EXAMINATION OF THE ABDOMEN

Urinary System

The urinary bladder lumen is moderately distended. The urinary bladder wall is thin and smooth. The urine is predominantly anechoic with a small amount of suspended echogenic debris. The bladder neck and proximal urethra are unremarkable. No cystoliths or sonographic evidence of inflammatory or neoplastic urinary bladder disease are identified.

The left kidney is normal in shape and size, measuring 4.08×2.69 cm. Cortical thickness measures 0.69 cm in the sagittal plane. Mild left renal pyelectasia measuring approximately 4.96 mm is identified.

The right kidney is normal in shape and size, measuring 4.22×2.55 cm. Cortical thickness measures 0.71 cm in the sagittal plane. Mild right renal pyelectasia measuring approximately 1.50 mm is identified.

Both kidneys demonstrate decreased corticomedullary definition. The renal cortices are slightly hyperechoic relative to the hepatic parenchyma. No nephrolithiasis is identified. Color Doppler evaluation demonstrates a subjectively normal vascular pattern.

Adrenal Glands

Not visualized.

Spleen

Splenic thickness is 0.73 cm. The parenchyma demonstrates normal echogenicity and fine homogeneous echotexture without focal parenchymal abnormalities. The splenic capsule is smooth and regular.

Liver

The liver is subjectively normal in size, with sharp edges and a regular contour. The liver parenchyma looks uniform and isoechoic compared to the falciform fat, with a normal echotexture. No hepatic lymphadenopathy is observed.

The gallbladder lumen is normally distended. The wall is thin and the contents are primarily anechoic. No evident dilation of the cystic duct or common bile duct is observed.



PATIENT

Figaro Martins

SPECIES

Feline

BREED

Domestic Shorthair

SEX

Neutered male

AGE

6 years

WEIGHT

7.8 lb

INTERPRETED BY

Alicia Angosto
Guerrero, DMV,
PgDip, MSc.

IMAGING PERFORMED BY

Christina Wagner

HOSPITAL NAME

Angeles Clinic for
Animals

REFERRING VET

Dr. Wagner

INVOICE

75245

DATE

5/6/26

Gastrointestinal System

The stomach is empty and folded. Gastric wall thickness measures 1.46 mm with preserved mural layering. The pyloric wall measures 4.90 mm. Duodenal wall thickness measures 2.27 mm. Jejunal wall thickness measures 2.10–2.39 mm with preserved mural layering. The ileocecal junction is not confidently visualized. No evidence of focal gastrointestinal inflammation, obstructive ileus, or foreign material is identified. Colonic wall thickness measures 1.35 mm. The colon is largely empty.

Pancreas

The evaluated pancreatic regions do not show evidence of overt inflammation or neoplastic disease.

Free Abdomen

No sonographic evidence of abdominal effusion, peritonitis, or lymphadenomegaly is identified. The iliac trifurcation is normal.

PRIMARY FINDINGS

- Bilateral mildly increased renal cortical echogenicity.
- Bilateral pyelectasia, more pronounced on the left (4.96 mm).
- Mildly decreased bilateral corticomedullary definition.

SECONDARY FINDINGS

- Mild suspended urinary sediment.

INTERPRETATION OF THE FINDINGS & FURTHER RECOMMENDATIONS

Both kidneys demonstrate mildly increased cortical echogenicity relative to the hepatic parenchyma with decreased corticomedullary definition. Mild bilateral pyelectasia is present, greater on the left. No nephrolithiasis is identified. Color Doppler evaluation demonstrates a subjectively normal vascular pattern. In the context of azotemia, isosthenuria, pyuria, bacteriuria, and granular casts, these findings concern renal disease with possible ascending infectious/inflammatory involvement, including pyelonephritis. However, the ultrasonographic abnormalities remain relatively nonspecific, and it should be recognized that pyelonephritis in cats may demonstrate subtle or even minimal sonographic changes.

The current examination does not identify evidence of ureteral obstruction, nephrolithiasis, hydronephrosis, or infiltrative renal mass lesions.

The mild urinary sediment is nonspecific and compatible with the reported inflammatory/infectious urinary findings.

No additional clinically significant abdominal abnormalities are identified sonographically.

Recommendations

- Correlation with urine culture and antimicrobial susceptibility testing is strongly recommended



PATIENT

Figaro Martins

SPECIES

Feline

BREED

Domestic Shorthair

SEX

Neutered male

AGE

6 years

WEIGHT

7.8 lb

INTERPRETED BY

Alicia Angosto
Guerrero, DMV,
PgDip, MSc.

IMAGING PERFORMED BY

Christina Wagner

HOSPITAL NAME

Angeles Clinic for
Animals

REFERRING VET

Dr. Wagner

INVOICE

75245

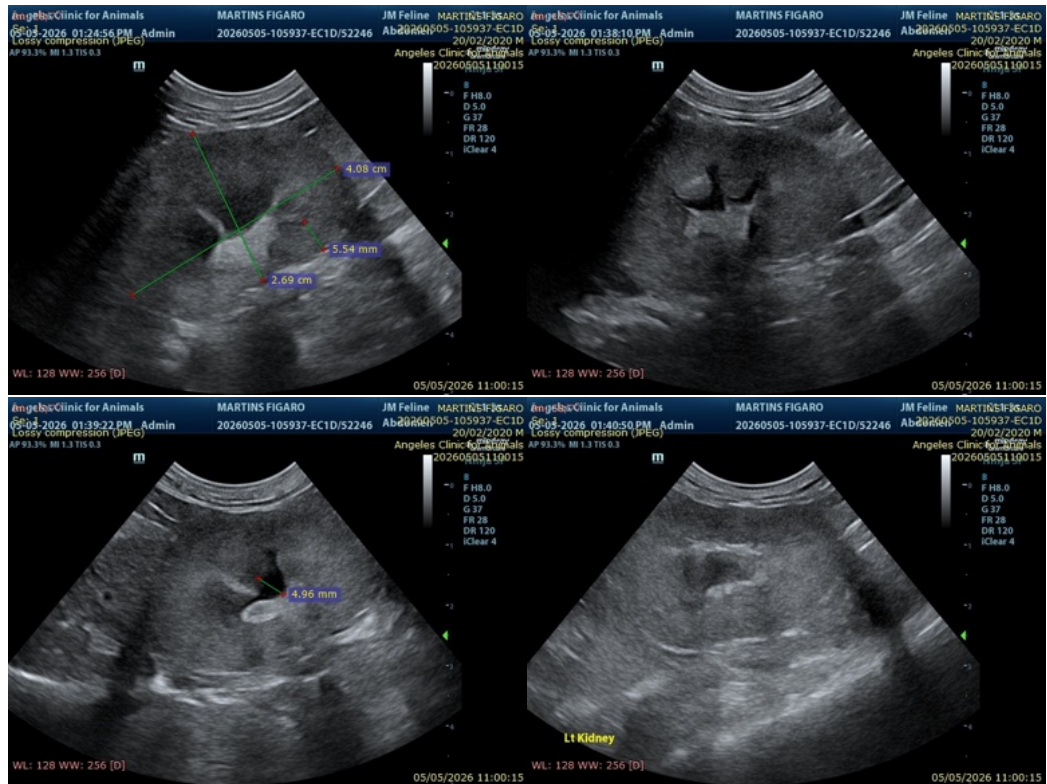
DATE

5/6/26

if not already performed.

- Serial monitoring of renal parameters, phosphorus, potassium, urine specific gravity, and hematocrit is advised given the degree of azotemia and evidence of chronic renal dysfunction.
- Follow-up renal ultrasound may be considered after treatment to reassess the renal pelvic dilation and renal architecture.
- Careful monitoring of hydration status, blood pressure, appetite, and body weight is recommended during management of the renal disease.

Final diagnostic and therapeutic decisions should be made by the attending veterinarian, who can best integrate these findings with the patient's clinical status.





PATIENT

Figaro Martins

SPECIES

Feline

BREED

Domestic Shorthair

SEX

Neutered male

AGE

6 years

WEIGHT

7.8 lb

INTERPRETED BY

Alicia Angosto
Guerrero, DMV,
PgDip, MSc.

**IMAGING
PERFORMED BY**

Christina Wagner

HOSPITAL NAME

Angeles Clinic for
Animals

REFERRING VET

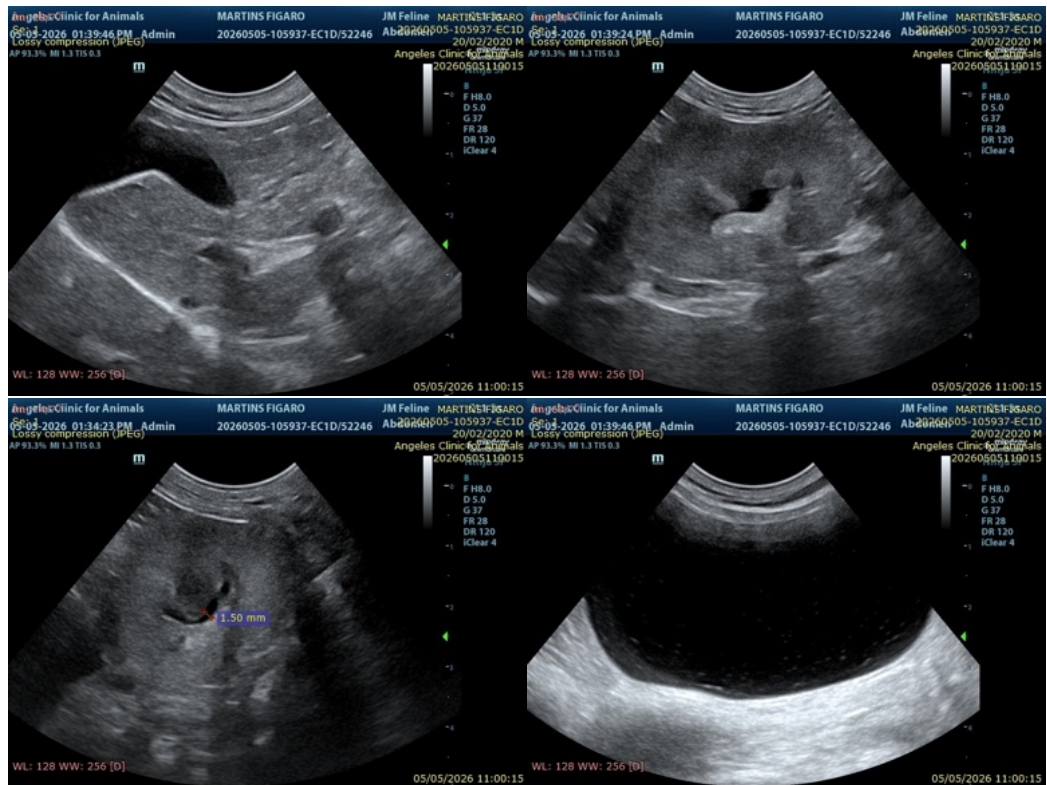
Dr. Wagner

INVOICE

75245

DATE

5/6/26



The information and recommendations provided are based on the images presented by the referring veterinarian/sonographer. No evaluation can be communicated regarding pathology that was not visible in the image/video clips provided.

Thank you for this referral. If the clinical or image interpretation does not parallel your findings or if I can be of any further assistance please contact me.

Alicia Angosto Guerrero, DMV, PgDip, MSc.

info@SonoPath.com