



PATIENT

Luca Stadler

SPECIES

Feline

BREED

Burmese

SEX

Neutered male

AGE

11 years

WEIGHT

11.9 lbs

INTERPRETED BY

Alicia Angosto
Guerrero, DMV,
PgDip, MSc.

IMAGING PERFORMED BY

Layna Irwin

HOSPITAL NAME

Boise Cat Clinic

REFERRING VET

Layna Irwin, DVM

INVOICE

75221

DATE

5/5/26

PRESENTING CLINICAL SIGNS

History: Elective ultrasound pursued under GA for COHAT procedure. No current concerns per client or physical exam.

- Hx of asthma (managed with oral prednisolone)
- Hx of IBD (managed with oral prednisolone & maropitant)
- Hx of hypertension (managed with amlodipine)

Abnormal PE/Chem/CBC/UA Results: PE: Equivocal heart murmur (cardiopet: 24) Chem - creat high (2.1) (hx), SDMA wnl (12), BUN wnl (31), Alb high (4.3) (hx), Spec fPL - elevated (7.9) (hx/stable T4 - greystone total T4 (3.5), free t4 wnl (19.3) UA - usg wnl (1.037) (hx), pH high (8.5), proteinuria (1+), clean/quiet sediment

ULTRASONOGRAPHIC EXAMINATION OF THE ABDOMEN

Urinary System

The urinary bladder lumen is normally distended. The urinary bladder wall is thin and smooth. The urine is predominantly anechoic with scant suspended echogenic debris. The bladder neck and proximal urethra are unremarkable. No cystoliths or sonographic evidence of inflammatory or neoplastic urinary bladder disease are identified.

The left kidney is normal in shape and size, measuring 3.58×2.06 cm. Cortical thickness measures 0.35 cm in the sagittal plane. The right kidney is normal in shape and size, measuring 3.79×2.39 cm. Cortical thickness measures 0.38 cm in the sagittal plane. Both kidneys demonstrate mildly increased cortical echogenicity relative to the hepatic parenchyma. Corticomedullary ratio and corticomedullary definition are preserved. No pyelectasia, hydronephrosis, or nephrolithiasis is identified. Color Doppler evaluation demonstrates a subjectively normal vascular pattern.

Adrenal Glands

Both adrenal glands show normal shape and echogenicity. Dorsoventral diameters measured in the sagittal plane: The left adrenal gland measures 0.24 cm at the cranial pole and 0.25 cm at the caudal pole. The right adrenal gland measures 0.20 cm at the cranial pole and 0.23 cm at the caudal pole.

Spleen

Splenic thickness is 0.94 cm. The parenchyma demonstrates normal echogenicity and fine homogeneous echotexture without focal parenchymal abnormalities. The splenic capsule is smooth and regular.

Liver

The liver is subjectively normal in size, with sharp edges and a regular contour. The liver parenchyma looks uniform and isoechoic compared to the falciform fat, with a normal echotexture. No hepatic lymphadenopathy is observed.



PATIENT

Luca Stadler

SPECIES

Feline

BREED

Burmese

SEX

Neutered male

AGE

11 years

WEIGHT

11.9 lbs

INTERPRETED BY

Alicia Angosto
Guerrero, DMV,
PgDip, MSc.

IMAGING PERFORMED BY

Layna Irwin

HOSPITAL NAME

Boise Cat Clinic

REFERRING VET

Layna Irwin, DVM

INVOICE

75221

DATE

5/5/26

The gallbladder lumen is normally distended. The wall is thin and the contents are primarily anechoic. No evident dilation of the cystic duct or common bile duct is observed.

Gastrointestinal

The stomach is empty and folded, containing a minimal amount of fluid. Gastric wall thickness measures 1.67 mm with preserved mural layering. The pyloric wall measures 2.99 mm. Duodenal wall thickness measures 1.51 mm. Jejunal wall thickness measures 2.25 mm, with the following layer measurements: Mucosa: 1.15 mm Submucosa: 0.62 mm. Muscularis propria: 0.45 mm Ileal wall thickness measures 1.92 mm, with the following layer measurements: Mucosa: 0.77 mm. Submucosa: 0.74 mm. Muscularis propria: 0.49 mm The ileocecal junction measures 2.64 mm in thickness, with muscularis thickness measuring 0.62 mm. Intestinal wall layering is preserved throughout all evaluated segments. No focal intestinal masses, obstructive ileus, foreign material, or regional inflammatory changes are identified. Colonic wall thickness measures 0.92 mm, with formed fecal material present within the descending colon.

Pancreas

The evaluated pancreatic regions do not show evidence of overt inflammation or neoplastic disease.

Free Abdomen

No sonographic evidence of abdominal effusion, peritonitis, or lymphadenomegaly is identified. The iliac trifurcation is normal.

PRIMARY FINDINGS

- Mild relative prominence of the ileal and ileocecal muscularis layer with preserved wall layering.

SECONDARY FINDINGS

- Mild diffuse increase in renal cortical echogenicity bilaterally.

INTERPRETATION OF THE FINDINGS & FURTHER RECOMMENDATIONS

Mild relative prominence of the ileal and ileocecal muscularis layer is identified with preserved mural layering and without associated mesenteric inflammatory change or lymphadenopathy.

The jejunal muscularis-to-mucosa ratio is approximately 0.39, remaining within expected limits, whereas the ileal muscularis-to-mucosa ratio is mildly increased at approximately 0.64. The ileocecal junction appears normal.



PATIENT

Luca Stadler

SPECIES

Feline

BREED

Burmese

SEX

Neutered male

AGE

11 years

WEIGHT

11.9 lbs

INTERPRETED BY

Alicia Angosto
Guerrero, DMV,
PgDip, MSc.

IMAGING PERFORMED BY

Layna Irwin

HOSPITAL NAME

Boise Cat Clinic

REFERRING VET

Layna Irwin, DVM

INVOICE

75221

DATE

5/5/26

In cats, mild muscularis layer prominence may be identified in both chronic inflammatory enteropathy and low-grade alimentary lymphoma, with recognized ultrasonographic overlap between these entities. However in this patient, the absence of marked wall thickening, loss of mural stratification, mass effect, mesenteric inflammatory change, or lymphadenopathy, together with the clinically stable history under corticosteroid therapy, favors mild chronic enteropathic/treatment-controlled change rather than active progressive infiltrative intestinal disease.

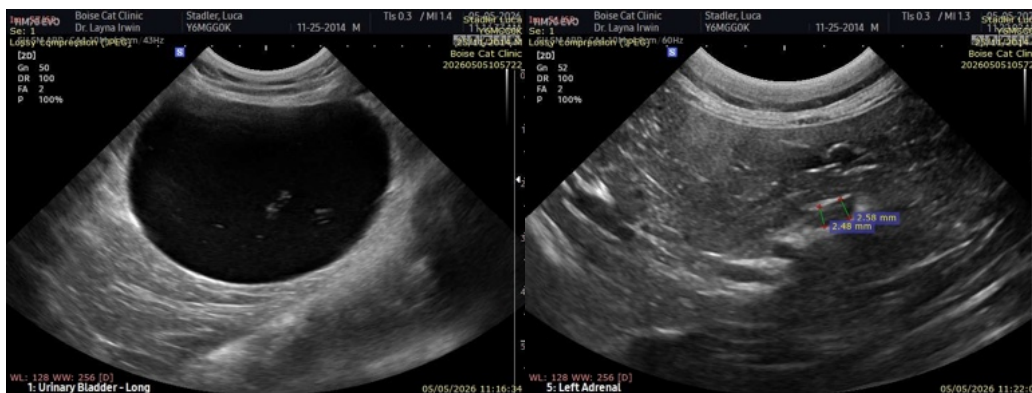Subtle bilateral renal cortical hyperechogenicity is present, compatible with mild chronic renal change. Despite the mildly increased creatinine concentration, renal architecture remains well preserved, with maintained corticomedullary distinction and no evidence of obstructive nephropathy.

No convincing ultrasonographic evidence of active pancreatitis is identified despite the chronically elevated Spec fPL concentration. However, it should be recognized that chronic feline pancreatitis may demonstrate minimal or absent ultrasonographic abnormalities.

Recommendations

- Continued clinical monitoring and current medical management appear reasonable given the overall stable ultrasonographic appearance.
- Serial monitoring of renal parameters, blood pressure, and urine protein status is recommended.
- Given the history of chronic enteropathy and mild ileal muscularis prominence, serum cobalamin assessment could be considered if not recently performed.
- Additional gastrointestinal sampling does not appear strongly indicated based on the current ultrasonographic appearance alone unless clinical signs progress or become refractory to therapy.
- Continued monitoring of pancreatic biomarkers and clinical signs may be considered as clinically indicated, recognizing that chronic feline pancreatitis may be poorly characterized sonographically.

Final diagnostic and therapeutic decisions should be made by the attending veterinarian, who can best integrate these findings with the patient's clinical status.





PATIENT

Luca Stadler

SPECIES

Feline

BREED

Burmese

SEX

Neutered male

AGE

11 years

WEIGHT

11.9 lbs

INTERPRETED BY

Alicia Angosto
Guerrero, DMV,
PgDip, MSc.

**IMAGING
PERFORMED BY**

Layna Irwin

HOSPITAL NAME

Boise Cat Clinic

REFERRING VET

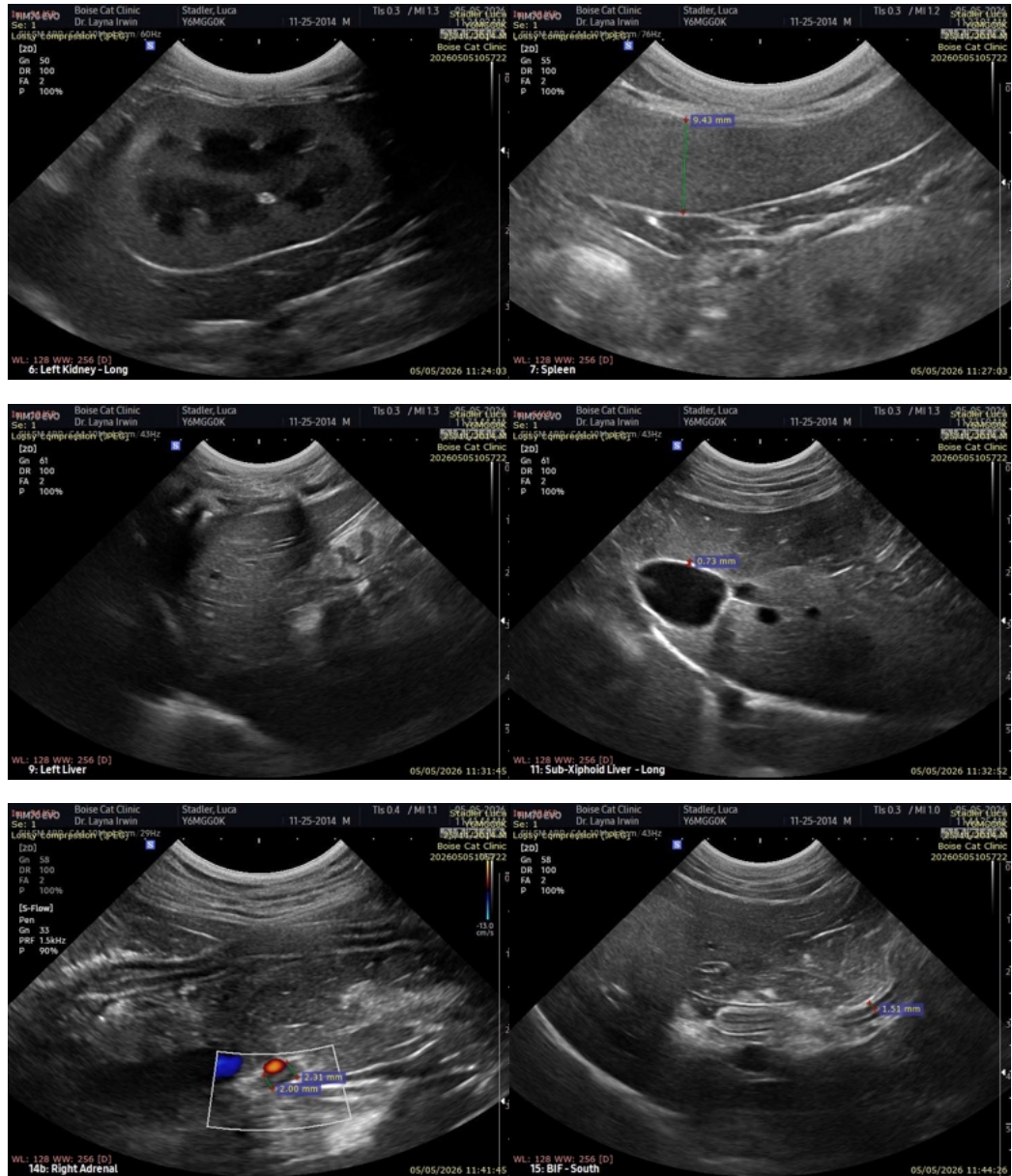
Layna Irwin, DVM

INVOICE

75221

DATE

5/5/26





PATIENT

Luca Stadler

SPECIES

Feline

BREED

Burmese

SEX

Neutered male

AGE

11 years

WEIGHT

11.9 lbs

INTERPRETED BY

Alicia Angosto
Guerrero, DMV,
PgDip, MSc.

IMAGING PERFORMED BY

Layna Irwin

HOSPITAL NAME

Boise Cat Clinic

REFERRING VET

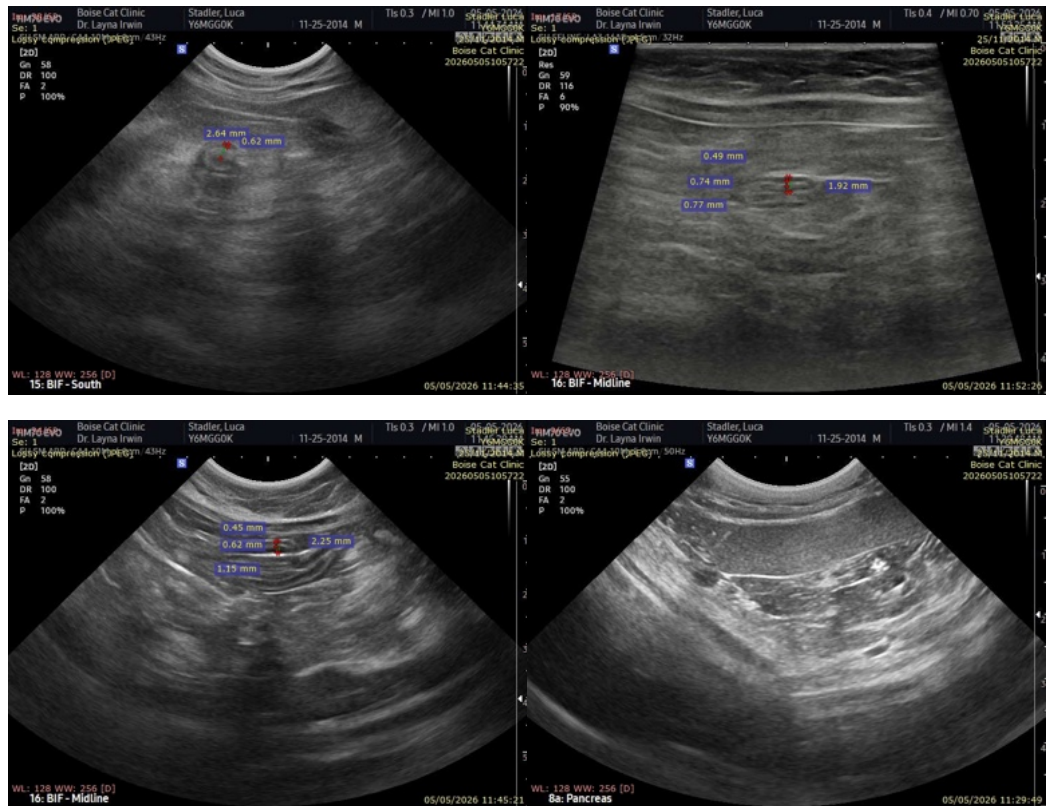
Layna Irwin, DVM

INVOICE

75221

DATE

5/5/26



The information and recommendations provided are based on the images presented by the referring veterinarian/sonographer. No evaluation can be communicated regarding pathology that was not visible in the image/video clips provided.

Thank you for this referral. If the clinical or image interpretation does not parallel your findings or if I can be of any further assistance please contact me.

Alicia Angosto Guerrero, DMV, PgDip, MSc.

info@SonoPath.com