



## PATIENT

Gracie Goodwin

## SPECIES

Canine

## BREED

Dachshund

## SEX

Spayed female

## AGE

9 years

## WEIGHT

12.7 lbs

## INTERPRETED BY

Alicia Angosto  
Guerrero, DMV,  
PgDip, MSc.

## IMAGING PERFORMED BY

Amanda Hartman DVM

## HOSPITAL NAME

White Hall Animal  
Clinic

## REFERRING VET

Dr. Hartman

## INVOICE

78030

## DATE

5/27/26

## PRESENTING CLINICAL SIGNS

History: Persistent increase to ALT after Dental procedure done 4/8/26, also EKG abnormality-Left Axis Deviation, \* Cardiac size within normal limits (VHS approximately 10.1); no radiographic evidence of cardiomegaly

\* No pleural effusion or pulmonary vascular congestion definitively identified

\* No radiographic evidence of thoracic neoplasia

Abnormal PE/Chem/CBC/UA Results: 4/8/26- ALT 271

## ULTRASONOGRAPHIC EXAMINATION OF THE ABDOMEN

### Urinary System

The bladder lumen is normally distended, and the wall of the urinary bladder appears thin and smooth. The urine is anechoic. Normal appearance of the bladder neck and proximal urethra. There are no calculi and no ultrasonographic evidence of inflammatory or neoplastic change.

The left kidney is normal in shape and size, measuring 3.45×1.91 cm, with cortical thickness measuring 0.32 cm in the sagittal plane. The renal cortex is isoechoic relative to the hepatic parenchyma. The corticomedullary ratio and corticomedullary definition are preserved. No evidence of pyelectasia, nephrolithiasis, or hydronephrosis is identified. Color Doppler demonstrates a subjectively normal vascular pattern.

The right kidney is normal in shape and size, measuring 3.94×2.01 cm, with cortical thickness measuring 0.35 cm in the sagittal plane. The renal cortex is isoechoic relative to the hepatic parenchyma. The corticomedullary ratio and corticomedullary definition are preserved. No evidence of pyelectasia, nephrolithiasis, or hydronephrosis is identified. Color Doppler demonstrates a subjectively normal vascular pattern.

### Adrenal Glands

The left adrenal gland is mildly enlarged, measuring approximately 0.54 cm at the cranial pole and 0.63 cm at the caudal pole. The right adrenal gland is not confidently visualized. A partial measurement of approximately 0.42 cm was obtained; however, this measurement is considered unreliable/incomplete.

### Spleen

Splenic thickness measures approximately 1.61 cm. The splenic parenchyma demonstrates overall homogeneous echotexture with several small well-defined hyperechoic myelolipoma-like nodules measuring less than 1 cm in diameter. The splenic capsule is smooth and regular.

### Liver

The liver is subjectively mildly enlarged, with rounded margins and mildly heterogeneous/patchy parenchymal echotexture. Multiple well-defined homogeneous hypoechoic hepatic nodules are identified, the majority measuring approximately 1 cm or less in diameter, although one lesion measures



## PATIENT

Gracie Goodwin

## SPECIES

Canine

## BREED

Dachshund

## SEX

Spayed female

## AGE

9 years

## WEIGHT

12.7 lbs

## INTERPRETED BY

Alicia Angosto  
Guerrero, DMV,  
PgDip, MSc.

## IMAGING PERFORMED BY

Amanda Hartman DVM

## HOSPITAL NAME

White Hall Animal  
Clinic

## REFERRING VET

Dr. Hartman

## INVOICE

78030

## DATE

5/27/26

up to approximately 2 cm. The nodules demonstrate a relatively uniform appearance and are favored to represent benign nodular hyperplastic/regenerative change. No hepatic lymphadenopathy is identified.

The gallbladder is moderately distended. The wall remains thin and smooth and the contents are predominantly anechoic. No cystic duct or common bile duct dilation is identified.

### ***Gastrointestinal tract***

The stomach is empty and folded, with wall thickness measuring approximately 2.30 mm and preserved wall layering. The pylorus measures approximately 4.67 mm in wall thickness. The duodenum measures approximately 2.93 mm in wall thickness. The jejunum measures approximately 2.64-2.71 mm in wall thickness with preserved mural layering. No intestinal inflammatory change, obstructive pattern, ileus, or foreign material is identified. The colon measures approximately 0.98-1.24 mm in wall thickness and contains formed fecal material within the descending colon.

### ***Pancreas***

The evaluated pancreatic regions do not show evidence of overt inflammation or neoplastic disease.

### ***Free Abdomen***

No sonographic evidence of abdominal effusion, peritonitis, or lymphadenomegaly is identified. The iliac trifurcation is normal.

### **PRIMARY FINDINGS**

- Mild hepatomegaly with multifocal well-defined hypoechoic hepatic nodules, favored to represent nodular hyperplastic/regenerative change

### **SECONDARY FINDINGS**

- Small splenic myelolipoma-like nodules.
- Subtle caudal pole enlargement of the left adrenal gland.

### **INTERPRETATION OF THE FINDINGS & FURTHER RECOMMENDATIONS**

This examination demonstrates mild hepatomegaly with multifocal well-defined homogeneous hypoechoic hepatic nodules, most compatible with multifocal nodular hyperplastic/regenerative hepatic change. Although definitive characterization of hepatic nodules ultimately requires cytology/histopathology, the overall ultrasonographic appearance is relatively benign and no overt aggressive hepatic features are identified at this time.

The mild patchy hepatic echotexture and multifocal nodular hepatic remodeling may reflect chronic vacuolar/reactive hepatopathy, chronic hepatocellular remodeling, or age-related nodular hyperplastic change. Correlation with serial liver enzyme trends and medication history is recommended.



## PATIENT

Gracie Goodwin

## SPECIES

Canine

## BREED

Dachshund

## SEX

Spayed female

## AGE

9 years

## WEIGHT

12.7 lbs

## INTERPRETED BY

Alicia Angosto  
Guerrero, DMV,  
PgDip, MSc.

## IMAGING PERFORMED BY

Amanda Hartman DVM

## HOSPITAL NAME

White Hall Animal  
Clinic

## REFERRING VET

Dr. Hartman

## INVOICE

78030

## DATE

5/27/26

The left adrenal gland demonstrates mild caudal pole enlargement, measuring approximately 0.63 cm in dorsoventral thickness. Reported upper reference limits for the caudal pole in dogs of this size are generally considered to be approximately 0.54-0.62 cm, placing this measurement at mildly above the expected upper limit. The right adrenal gland is not confidently visualized; therefore, complete bilateral adrenal comparison is not possible on the current examination.

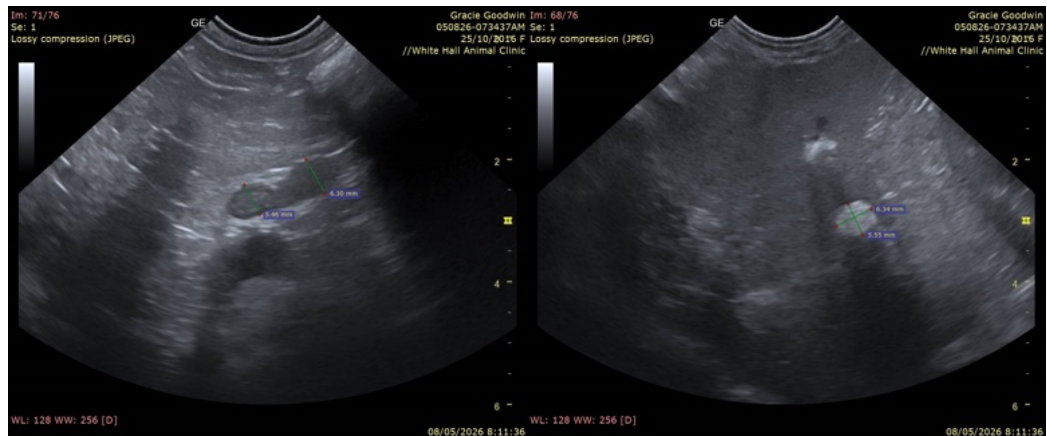
This finding may represent incidental adrenal hyperplasia or early adrenal change; however, correlation with endocrine testing for hyperadrenocorticism should be based on the overall clinical picture and laboratory findings rather than ultrasound appearance alone.

Small incidental splenic myelolipoma-like nodules are also present.

### Recommendations

- Continued monitoring of ALT and serial serum biochemistry is recommended.
- Follow-up abdominal ultrasound in approximately 3-6 months may be considered to assess stability of the multifocal hepatic nodules and adrenal enlargement.
- Correlation with endocrine testing for hyperadrenocorticism may be considered if clinically warranted.
- Ultrasound-guided hepatic cytology could be considered if liver enzymes continue to rise, nodules enlarge over time, or additional clinical concerns develop.

Final diagnostic and therapeutic decisions should be made by the attending veterinarian, who can best integrate these findings with the patient's clinical status.





## PATIENT

Gracie Goodwin

## SPECIES

Canine

## BREED

Dachshund

## SEX

Spayed female

## AGE

9 years

## WEIGHT

12.7 lbs

## INTERPRETED BY

Alicia Angosto  
Guerrero, DMV,  
PgDip, MSc.

## IMAGING PERFORMED BY

Amanda Hartman DVM

## HOSPITAL NAME

White Hall Animal  
Clinic

## REFERRING VET

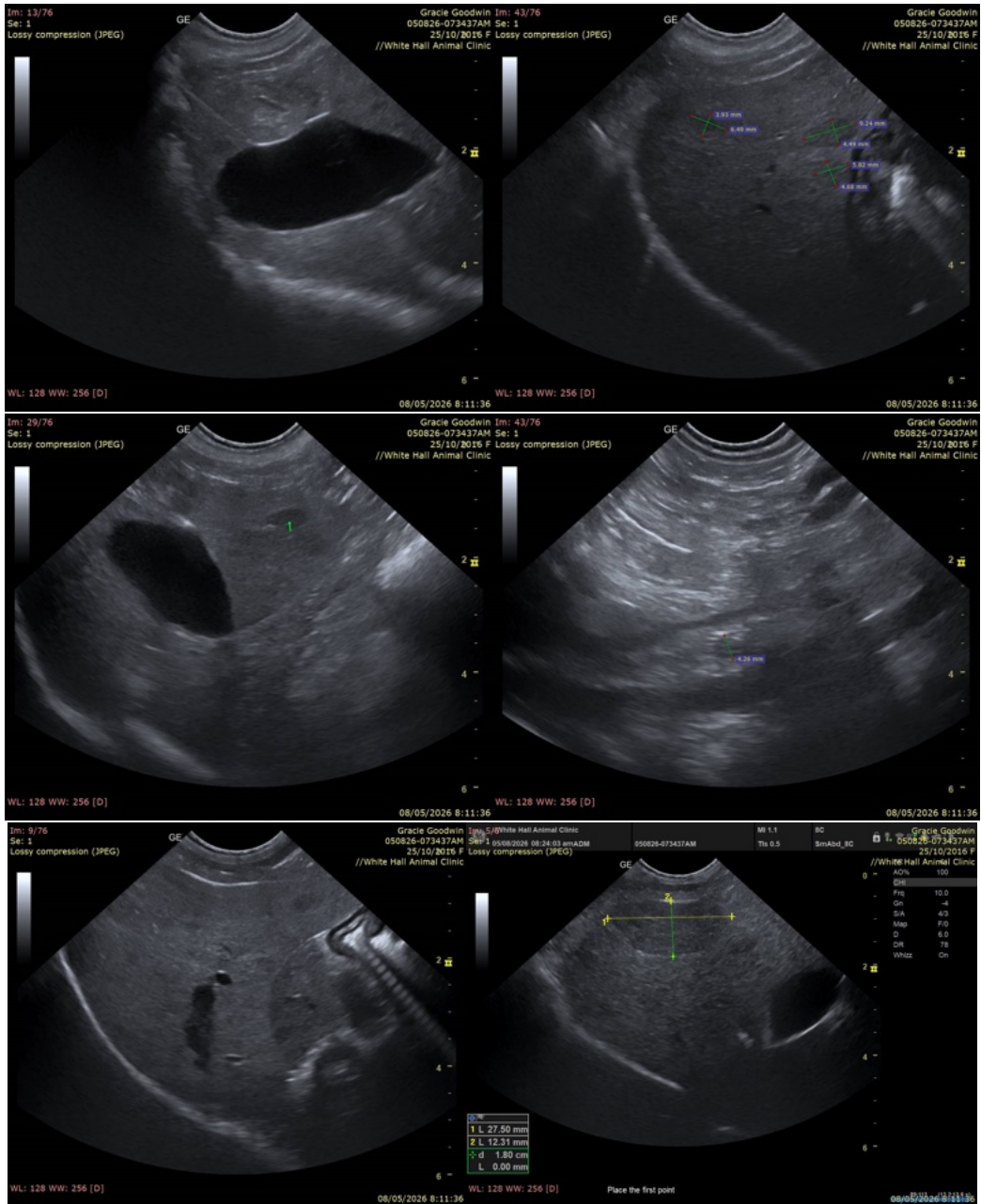
Dr. Hartman

## INVOICE

78030

## DATE

5/27/26



The information and recommendations provided are based on the images presented by the referring veterinarian/sonographer. No evaluation can be communicated regarding pathology that was not visible in the image/video clips provided.

Thank you for this referral. If the clinical or image interpretation does not parallel your findings or if I can be of any further assistance please contact me.

Alicia Angosto Guerrero, DMV, PgDip, MSc.

[info@SonoPath.com](mailto:info@SonoPath.com)