

**PATIENT**

Wego De Los Santos

SPECIES

Canine

BREED

Retriever Cross

SEX

Neutered male

AGE

11 years

WEIGHT

69.8 lbs

INTERPRETED BY

Alicia Angosto
Guerrero, DMV,
PgDip, MSc.

**IMAGING
PERFORMED BY**

Amanda Favis

HOSPITAL NAME

Ruidoso AC

REFERRING VET

Dr. Favis

INVOICE

77987

DATE

5/26/26

PRESENTING CLINICAL SIGNS

History: Weight loss, decreased appetite, daily vomiting.
Abnormal PE/Chem/CBC/UA Results: Anemia that resolved

ULTRASONOGRAPHIC EXAMINATION OF THE ABDOMEN**Urinary System**

No diagnostic images or videos of the urinary bladder were provided for evaluation. Therefore, the urinary bladder could not be adequately assessed sonographically on the current study.

The left kidney is normal in shape and size, measuring 6.91×3.54 cm, with a cortical thickness of 0.61 cm in the sagittal plane. The renal cortex is isoechoic relative to the hepatic parenchyma. The corticomedullary ratio and corticomedullary definition are preserved. No evidence of pyelectasia, nephrolithiasis, ureteral dilation, or hydronephrosis is identified.

The right kidney is normal in shape and size, measuring 6.77×3.87 cm, with a cortical thickness of 0.60 cm in the sagittal plane. The renal cortex is isoechoic relative to the hepatic parenchyma. The corticomedullary ratio and corticomedullary definition are preserved. No evidence of pyelectasia, nephrolithiasis, ureteral dilation, or hydronephrosis is identified.

Adrenal Glands

Both adrenal glands show normal shape and echogenicity. Dorsoventral diameters measured in the sagittal plane: The left adrenal gland measures 0.68 cm at the cranial pole and 0.57 cm at the caudal pole. The right adrenal gland measures 0.56 cm at the cranial pole and 0.58 cm at the caudal pole.

Spleen

Splenic thickness measures 1.90 cm. The splenic parenchyma demonstrates overall normal echogenicity and a fine homogeneous echotexture. Two focal splenic nodules are identified. One small hypoechoic nodule measures approximately 0.5×0.8 cm. A second splenic nodule measures approximately 1.56×1.58 cm and appears more heterogeneously hypoechoic. The splenic capsule is smooth and regular.

Liver

The liver is subjectively normal in size, with sharp edges and a regular contour. The liver parenchyma looks uniform and isoechoic compared to the falciform fat, with a normal echotexture. No hepatic lymphadenopathy is observed.

The gallbladder lumen is normally distended. The wall is thin and the contents are primarily anechoic with a small amount of biliary sludge. No evident dilation of the cystic duct or common bile duct is observed.



PATIENT

Wego De Los Santos

SPECIES

Canine

BREED

Retriever Cross

SEX

Neutered male

AGE

11 years

WEIGHT

69.8 lbs

INTERPRETED BY

Alicia Angosto
Guerrero, DMV,
PgDip, MSc.

IMAGING PERFORMED BY

Amanda Favis

HOSPITAL NAME

Ruidoso AC

REFERRING VET

Dr. Favis

INVOICE

77987

DATE

5/26/26

Gastrointestinal tract

The stomach is empty and folded, with mild intraluminal gas artifact. Gastric wall thickness measures approximately 2.91 mm, with preserved wall layering throughout the majority of the visualized stomach.

However, a focal region of marked gastric mural thickening measuring approximately 1.53 cm with loss of normal wall layering is identified within a portion of the stomach that could only be visualized on a limited number of submitted splenic video clips. Based on the regional anatomy and imaging orientation, this lesion is suspected to involve the gastric fundus, although complete confirmation is limited by incomplete visualization of the region and lack of dedicated targeted imaging.

The pyloric wall measures approximately 7 mm. The duodenal wall measures 3.12 mm. The jejunal wall measures 3.58 mm, with preserved wall layering. The ileocecolic junction is not confidently visualized.

The colon measures approximately 1.34 mm in wall thickness and is largely empty/collapsed.

Pancreas

The evaluated pancreatic regions do not show evidence of overt inflammation or neoplastic disease.

Free Abdomen

An enlarged left gastric lymph node is identified, measuring approximately 0.87×1.36 cm, rounded and hypoechoic in appearance. No sonographic evidence of abdominal effusion or peritonitis is identified. The iliac trifurcation region appears normal.

PRIMARY FINDINGS

- Marked focal gastric mural thickening with loss of wall layering, suspected to involve the gastric fundus.
- Enlarged rounded hypoechoic left gastric lymph node.
- Two splenic nodules, including one larger heterogeneous hypoechoic splenic nodule.

SECONDARY FINDINGS

- Mild biliary sludge.

INTERPRETATION OF THE FINDINGS & FURTHER RECOMMENDATIONS

The dominant abnormality on the current examination is a focal region of marked gastric mural thickening with loss of normal wall layering, suspected to involve the gastric fundus. Although visualization of this region is somewhat limited and the lesion was only identified on a limited number of submitted clips, the ultrasonographic appearance is considered highly abnormal.

Differential considerations include severe focal granulomatous/inflammatory disease, gastric neoplasia (including carcinoma, lymphoma, leiomyosarcoma, or other infiltrative neoplastic processes), or less



PATIENT

Wego De Los Santos

SPECIES

Canine

BREED

Retriever Cross

SEX

Neutered male

AGE

11 years

WEIGHT

69.8 lbs

likely a severe focal ulcerative disease. The associated enlarged rounded hypoechoic left gastric lymph node further increases concern for clinically significant gastric pathology with reactive nodal involvement or possible locoregional metastatic.

The two splenic nodules are nonspecific. The smaller nodule may represent benign nodular hyperplasia or extramedullary hematopoietic change; however, the larger heterogeneous hypoechoic splenic nodule is more indeterminate. Splenic metastatic disease or concurrent nodular pathology cannot be excluded, particularly in the context of the suspected gastric lesion.

No sonographic evidence of abdominal effusion, overt perforation, or diffuse carcinomatosis is identified at this time.

Recommendations

- Upper gastrointestinal endoscopy with biopsies is recommended if clinically feasible.
- Ultrasound-guided cytology of the largest splenic nodule.
- Correlation with CBC, serum biochemistry, iron studies, and fecal occult blood testing may be clinically valuable given the history of anemia and chronic gastrointestinal signs.
- Thoracic imaging may be considered for staging if gastric neoplasia is confirmed or strongly suspected.

Final diagnostic and therapeutic decisions should be made by the attending veterinarian, who can best integrate these findings with the patient's clinical status.

INTERPRETED BY

Alicia Angosto
Guerrero, DMV,
PgDip, MSc.

IMAGING PERFORMED BY

Amanda Favis

HOSPITAL NAME

Ruidoso AC

REFERRING VET

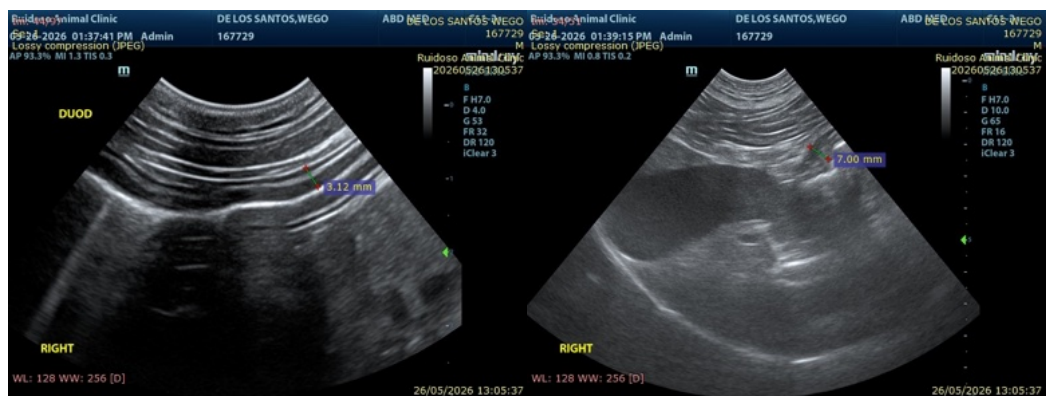
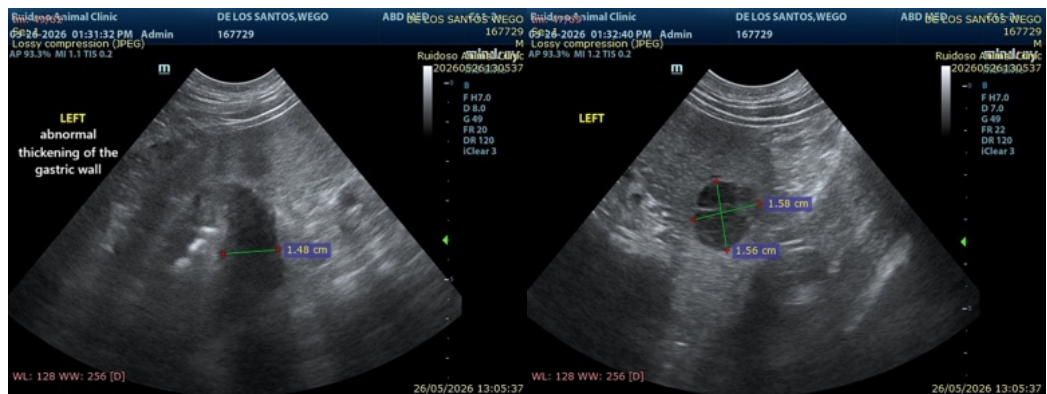
Dr. Favis

INVOICE

77987

DATE

5/26/26





PATIENT

Wego De Los Santos

SPECIES

Canine

BREED

Retriever Cross

SEX

Neutered male

AGE

11 years

WEIGHT

69.8 lbs

INTERPRETED BY

Alicia Angosto Guerrero, DMV, PgDip, MSc.

IMAGING PERFORMED BY

Amanda Favis

HOSPITAL NAME

Ruidoso AC

REFERRING VET

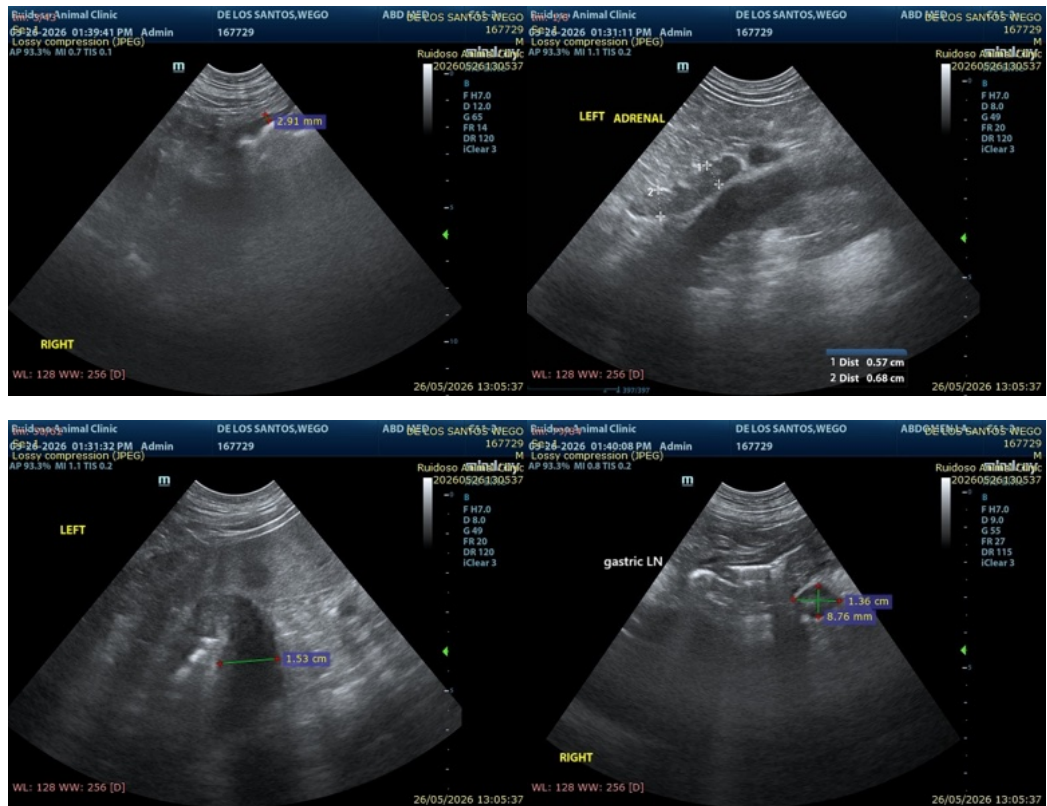
Dr. Favis

INVOICE

77987

DATE

5/26/26



The information and recommendations provided are based on the images presented by the referring veterinarian/sonographer. No evaluation can be communicated regarding pathology that was not visible in the image/video clips provided.

Thank you for this referral. If the clinical or image interpretation does not parallel your findings or if I can be of any further assistance please contact me.

Alicia Angosto Guerrero, DMV, PgDip, MSc.

info@SonoPath.com