



PATIENT

Minnie Jackson

SPECIES

Feline

BREED

DSH

SEX

Spayed Female

AGE

12 Years

WEIGHT

9

INTERPRETED BY

Alicia Angosto
Guerrero, DMV,
PgDip, MSc.

IMAGING PERFORMED BY

Dr. Brittany Levy

HOSPITAL NAME

Court Street
Veterinary Hospital

REFERRING VET

Dr. Brittany Levy

INVOICE

16459

DATE

05/22/26

PRESENTING CLINICAL SIGNS

Minnie underwent ultrasound scan to investigate concerns of chronic diarrhea, with novel minor hematochezia, intermittent irregular vomiting and chronic weight loss of several months' duration.

Abnormal PE/Chem/CBC/UA Results: 5/19/26 Diarrhea PCR & IDEXX GI Panel PENDING. 1/23/26 CBC grossly WNL (mild monocytosis) 1/23/26 Chem PHOS low 2.8, K+ low 3.4, TT4 WNL ... AXR r/o GIFB concern at that time.

ULTRASONOGRAPHIC EXAMINATION OF THE ABDOMEN

Urinary System

The bladder lumen is normally distended, and the wall of the urinary bladder appears thin and smooth. The urine is anechoic. Normal appearance of the bladder neck and proximal urethra. There are no calculi, and no evidence of inflammatory or neoplastic changes.

The left kidney is normal in shape and size, measuring 3.05×1.83 cm, with cortical thickness measuring 0.35 cm in the sagittal plane. The right kidney is normal in shape and size, measuring 3.17×2.14 cm, with cortical thickness measuring 0.35 cm in the sagittal plane. In both kidneys, the renal cortex is isoechoic compared to the liver parenchyma. The corticomedullary ratio and corticomedullary definition are preserved. No pyelectasia, nephrolithiasis, or hydronephrosis is identified.

Adrenal Glands

Both adrenal glands demonstrate normal shape and echogenicity. Dorsoventral diameters measured in the sagittal plane remain within normal feline limits. The left adrenal gland measures 0.25 cm. The right adrenal gland measures 0.23 cm at the cranial pole and 0.22 cm at the caudal pole.

Spleen

Splenic thickness is 0.91 cm. The parenchyma demonstrates normal echogenicity and fine homogeneous echotexture without focal parenchymal abnormalities. The splenic capsule is smooth and regular.

Liver

The liver is subjectively normal in size, with sharp edges and a regular contour. The liver parenchyma looks uniform and isoechoic compared to the falciform fat, with a normal echotexture. No hepatic lymphadenopathy is observed.

The gallbladder is moderately distended. The wall is thin and smooth, and the contents are predominantly anechoic. The common bile duct measures approximately 4.23 mm proximally, tapering to 2.90 mm and 1.42 mm distally. Mild extrahepatic biliary ductal prominence is therefore present, without convincing ultrasonographic evidence of complete biliary obstruction.

Gastrointestinal tract

The stomach is empty and folded, with wall thickness measuring 1.71 mm and preserved wall layering.

The pylorus measures 3.15 mm. The jejunum measures 3.39 mm in total thickness, with mucosa measuring 1.53 mm, submucosa 0.97 mm, and muscularis propria 1.16 mm. The ileum measures 2.16 mm, with mucosa measuring 0.87 mm, submucosa 0.84 mm, and muscularis propria 0.38 mm. The



PATIENT

Minnie Jackson

SPECIES

Feline

BREED

DSH

SEX

Spayed Female

AGE

12 Years

WEIGHT

9

INTERPRETED BY

Alicia Angosto
Guerrero, DMV,
PgDip, MSc.

IMAGING PERFORMED BY

Dr. Brittany Levy

HOSPITAL NAME

Court Street
Veterinary Hospital

REFERRING VET

Dr. Brittany Levy

INVOICE

16459

DATE

05/22/26

ileocecal junction measures approximately 3.59 mm, with mucosa measuring 1.17 mm and muscularis propria 1.47 mm. Intestinal wall layering remains preserved throughout all evaluated segments.

Marked muscularis propria thickening is present involving the jejunum and ileocecal junction, resulting in clearly increased muscularis-to-mucosa ratios. No focal obstructive lesion, plication, or foreign material is identified ultrasonographically. The colon measures approximately 0.56 cm and contains semiformal soft fecal material.

Pancreas

The evaluated pancreatic regions do not show evidence of overt inflammation or neoplastic disease.

Free Abdomen

No abdominal effusion or sonographic evidence of peritonitis is identified. Cranial mesenteric lymph nodes measure approximately 5.67–6.60 mm in thickness, maintain overall normal shape, and are mildly hypoechoic. Ileocecal lymph nodes are not confidently visualized, although the surrounding mesentery appears unremarkable. No overt abdominal lymphadenomegaly is identified. The region of the iliac trifurcation appears normal.

PRIMARY FINDINGS

- Marked muscularis propria thickening involving the jejunum and ileocecal junction.
- Mild extrahepatic biliary ductal prominence.
- Prominent cranial mesenteric lymph nodes.

INTERPRETATION OF THE FINDINGS & FURTHER RECOMMENDATIONS

Marked muscularis propria thickening involving the jejunum and ileocecal junction is present with preserved wall layering and without focal mass effect or obstructive pattern. In a geriatric cat with chronic weight loss, chronic diarrhea, intermittent vomiting, and recent hematochezia, the ultrasonographic appearance raises substantial concern for chronic infiltrative gastrointestinal disease. The primary differential considerations include chronic inflammatory enteropathy and low-grade alimentary lymphoma, with the degree of muscularis thickening and ileocecal involvement considered more pronounced than typically expected from mild nonspecific enteropathy alone.

The mildly prominent cranial mesenteric lymph nodes may represent reactive lymphoid change associated with chronic intestinal inflammation, although early infiltrative involvement cannot be completely excluded ultrasonographically.

Mild extrahepatic biliary ductal prominence is present without convincing evidence of complete biliary obstruction. This finding may reflect chronic low-grade pancreatobiliary-enteric inflammatory interaction/remodeling and should be interpreted in conjunction with pending GI panel results and clinicopathologic data.

Recommendations

- Correlation with the pending GI panel, including cobalamin status, is recommended.
- Given the degree of muscularis thickening and chronicity of clinical signs, intestinal biopsy should be considered if clinically appropriate, particularly if empiric therapy fails to achieve adequate long-term control.



PATIENT

Minnie Jackson

SPECIES

Feline

BREED

DSH

SEX

Spayed Female

AGE

12 Years

WEIGHT

9

INTERPRETED BY

Alicia Angosto
Guerrero, DMV,
PgDip, MSc.

IMAGING PERFORMED BY

Dr. Brittany Levy

HOSPITAL NAME

Court Street
Veterinary Hospital

REFERRING VET

Dr. Brittany Levy

INVOICE

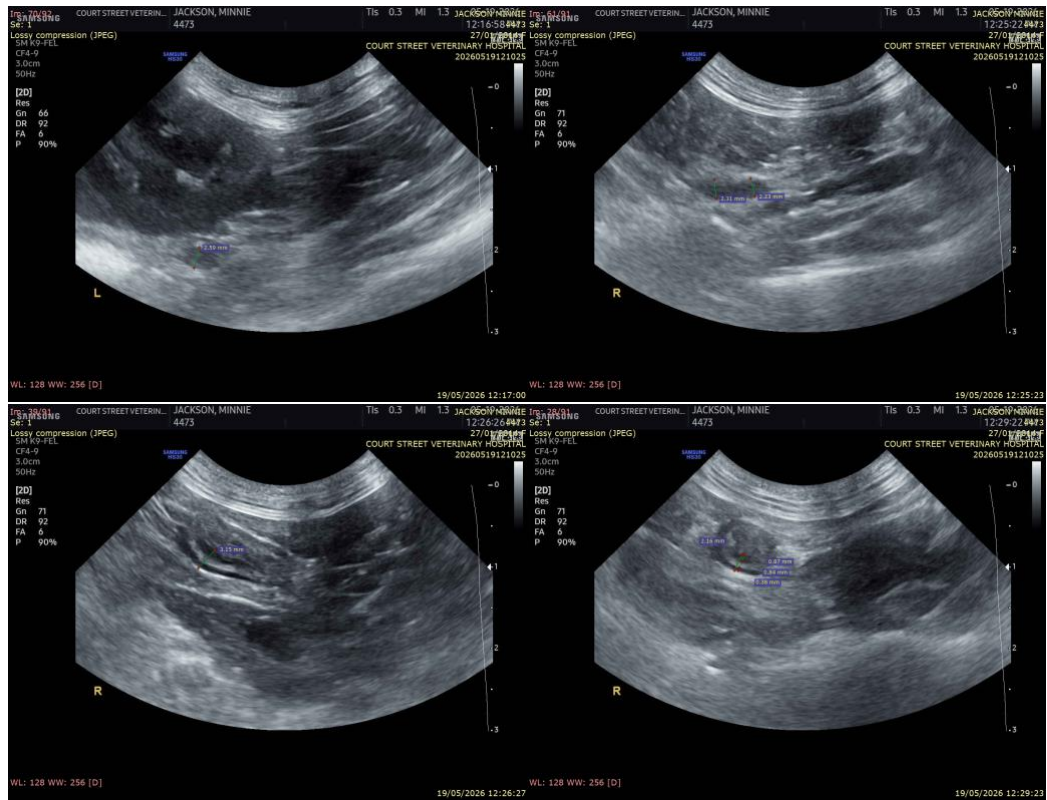
16459

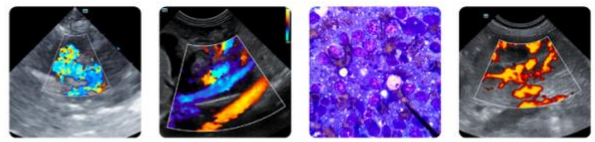
DATE

05/22/26

- Correlation with therapeutic response to dietary modification, cobalamin supplementation, probiotics, and/or empiric anti-inflammatory gastrointestinal therapy may also be clinically useful.
- Serial monitoring of body weight, gastrointestinal signs, and intestinal ultrasonographic appearance is recommended.

Final diagnostic and therapeutic decisions should be made by the attending veterinarian, who can best integrate these findings with the patient's clinical status.





PATIENT

Minnie Jackson

SPECIES

Feline

BREED

DSH

SEX

Spayed Female

AGE

12 Years

WEIGHT

9

INTERPRETED BY

Alicia Angosto
Guerrero, DMV,
PgDip, MSc.

**IMAGING
PERFORMED BY**

Dr. Brittany Levy

HOSPITAL NAME

Court Street
Veterinary Hospital

REFERRING VET

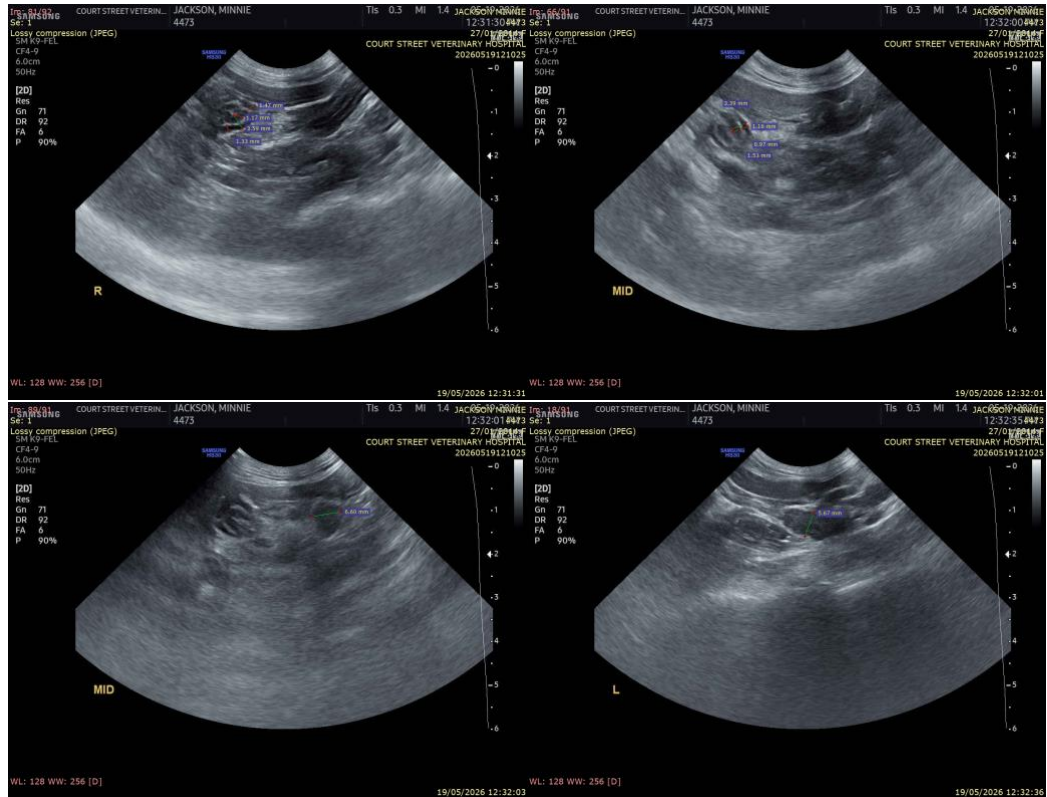
Dr. Brittany Levy

INVOICE

16459

DATE

05/22/26



The information and recommendations provided are based on the images presented by the referring veterinarian/sonographer. No evaluation can be communicated regarding pathology that was not visible in the image/video clips provided.

Thank you for this referral. If the clinical or image interpretation does not parallel your findings or if I can be of any further assistance please contact me.

Alicia Angosto Guerrero, DMV, PgDip, MSc.

info@SonoPath.com