



PATIENT

Mac Armstrong

SPECIES

Feline

BREED

DMH

SEX

Neutered Male

AGE

16 Years

WEIGHT

8.98

INTERPRETED BY

Alicia Angosto
Guerrero, DMV,
PgDip, MSc.

IMAGING PERFORMED BY

Dr. Cassidy Stone

HOSPITAL NAME

Petroglyph Animal
Hospital

REFERRING VET

Dr. Cassidy Stone

INVOICE

75460

DATE

5/22/26

PRESENTING CLINICAL SIGNS

Vomiting on and off several times a day starting at the end of 2025. O has noted weight loss over this time. Abnormal PE/Chem/CBC/UA Results: Bloodwork WNL

ULTRASONOGRAPHIC EXAMINATION OF THE ABDOMEN

Urinary System

The urinary bladder is normally distended, and the urinary bladder wall appears thin and smooth. The urine is anechoic. Normal appearance of the bladder neck and proximal urethra. No calculi or sonographic evidence of inflammatory or neoplastic mural changes are identified.

The left kidney is normal in shape and size, measuring 3.12×2.03 cm, with a cortical thickness of 0.31 cm in the sagittal plane. The renal cortex is isoechoic relative to the hepatic parenchyma. The corticomedullary ratio is normal, and corticomedullary definition is preserved. No evidence of pyelectasia, nephrolithiasis, ureteral dilation, or hydronephrosis is identified. Color Doppler interrogation demonstrates a normal vascular pattern.

The right kidney is normal in shape and size, measuring 3.85×2.04 cm, with a cortical thickness of 0.38 cm in the sagittal plane. The renal cortex is isoechoic relative to the hepatic parenchyma. The corticomedullary ratio is normal, and corticomedullary definition is preserved. No evidence of pyelectasia, nephrolithiasis, ureteral dilation, or hydronephrosis is identified. Color Doppler interrogation demonstrates a normal vascular pattern.

Adrenal Glands

Both adrenal glands show normal shape and echogenicity. Dorsoventral diameters measured in the sagittal plane: The left adrenal gland measures 0.25 cm at the cranial pole and 0.22 cm at the caudal pole. The right adrenal gland measures 0.23 cm at the cranial pole and 0.23 cm at the caudal pole.

Spleen

Splenic thickness is 0.67cm. The parenchyma demonstrates normal echogenicity and fine homogeneous echotexture without focal parenchymal abnormalities. The splenic capsule is smooth and regular.

Liver

The liver is subjectively normal in size, with sharp margins and a regular contour. The hepatic parenchyma is homogeneous and isoechoic relative to the surrounding falciform fat, with a normal echotexture. A cystic lesion measuring up to 1.57×1.28 cm is identified within the caudate process of the caudate liver lobe. No hepatic lymphadenopathy is identified.

Gallbladder and Biliary Tract

The gallbladder is normally distended. The gallbladder wall is thin, and the luminal contents are predominantly anechoic, with a small amount of biliary sludge. The common bile duct measures 2.68 mm proximally and tapers to 1.84 mm distally.

Gastrointestinal tract

The stomach contains ingesta. Gastric wall thickness measures 1.66 mm, with preserved wall layering. The pyloric wall measures 3.47 mm.



PATIENT

Mac Armstrong

SPECIES

Feline

BREED

DMH

SEX

Neutered Male

AGE

16 Years

WEIGHT

8.98

INTERPRETED BY

Alicia Angosto
Guerrero, DMV,
PgDip, MSc.

IMAGING PERFORMED BY

Dr. Cassidy Stone

HOSPITAL NAME

Petroglyph Animal
Hospital

REFERRING VET

Dr. Cassidy Stone

INVOICE

75460

DATE

5/22/26

The duodenum measures 2.25 mm in wall thickness and is mildly fluid-distended with luminal ingesta passage observed. The jejunal wall measures 1.29 mm, with mucosa measuring 0.51 mm, submucosa 0.41 mm, and muscularis propria 0.20 mm. The ileal wall layering is preserved; mucosa measures 0.37 mm, submucosa 0.58 mm, and muscularis propria 0.16 mm. The ileocecolic junction measures 3.70 mm, with mucosa measuring 1.39 mm and muscularis propria 1.87 mm.

Multiple segments of small intestine demonstrate a postprandial/food-responsive luminal pattern with mildly increased peristalsis and diffuse luminal ingesta passage. These findings are compatible with an incompletely fasted state, delayed gastric emptying, or ongoing active digestion at the time of examination. Assessment of mural layering and accurate intestinal wall measurements is mildly limited by the luminal contents and intestinal motility.

No sonographic evidence of mechanical ileus, gastrointestinal foreign material, focal obstructive lesion, or loss of intestinal wall layering is identified.

The colon measures 0.77 mm in wall thickness and contains formed fecal material.

Pancreas

The pancreas measures approximately 5.20–6.30 mm in thickness. The pancreatic parenchyma is mildly hypoechoic relative to the adjacent mesenteric fat. The pancreatic duct measures 0.94–1.18 mm in diameter. No surrounding mesenteric fat hyperechogenicity or other convincing sonographic evidence of active peripancreatic inflammation is identified.

Free Abdomen

A trace amount of abdominal effusion is present. The cranial mesenteric lymph nodes measure 3.81–4.67 mm and the ileocecolic lymph node measures 2.02 mm. All visualized abdominal lymph nodes maintain normal shape and echogenicity. The iliac trifurcation region appears normal.

PRIMARY FINDINGS

- Cystic hepatic lesion within the caudate process of the caudate liver lobe.
- Muscularis thickening at the ileocecolic junction.
- Mild pancreatic hypoechoic with pancreatic ductal prominence.
- Trace abdominal effusion.

INTERPRETATION OF THE FINDINGS & FURTHER RECOMMENDATIONS

The most clinically significant finding on the current examination is the muscularis thickening at the ileocecolic junction, where the muscularis propria exceeds the mucosal thickness. In an older cat with chronic intermittent vomiting and weight loss, this finding raises concern for early chronic inflammatory enteropathy versus low-grade alimentary lymphoma, particularly given the predilection of feline small-cell lymphoma to involve the muscularis layer while preserving mural layering architecture. The remainder of the small intestinal tract is comparatively unremarkable, and no discrete obstructive lesion or severe diffuse intestinal abnormality is identified.

Interpretation of the gastrointestinal tract is mildly limited by the apparent postprandial state and active luminal ingesta passage throughout the small intestine. The diffuse food-responsive luminal pattern and increased peristalsis may simply reflect insufficient fasting prior to examination; however, delayed gastric emptying or functional gastrointestinal dysmotility cannot be entirely excluded in the



PATIENT

context of the chronic vomiting history.

Mac Armstrong

SPECIES

Feline

BREED

DMH

SEX

Neutered Male

AGE

16 Years

WEIGHT

8.98

INTERPRETED BY

Alicia Angosto
Guerrero, DMV,
PgDip, MSc.

IMAGING PERFORMED BY

Dr. Cassidy Stone

HOSPITAL NAME

Petroglyph Animal
Hospital

REFERRING VET

Dr. Cassidy Stone

INVOICE

75460

DATE

5/22/26

The pancreas demonstrates mild diffuse hypoechogenicity with mild pancreatic ductal prominence, without convincing peripancreatic inflammatory change. In geriatric cats, these findings may reflect chronic pancreatic remodeling/chronic pancreatopathy rather than active pancreatitis, although chronic low-grade pancreatic inflammation remains possible. Importantly, feline pancreatic disease may be clinically significant despite relatively subtle ultrasonographic changes and minimal surrounding fat reaction.

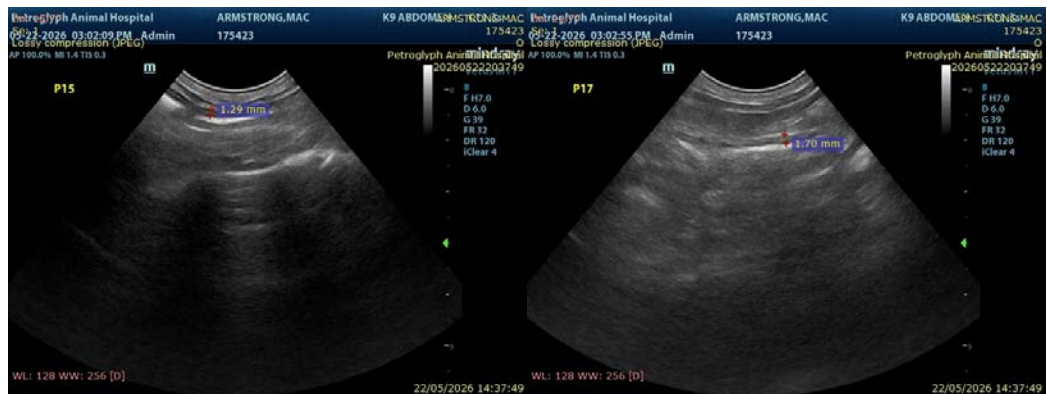The trace abdominal effusion is nonspecific and may be incidental/reactive. No sonographic evidence of septic peritonitis, abdominal carcinomatosis, marked lymphadenopathy, or obstructive biliary disease is identified.

The cystic hepatic lesion within the caudate process most likely represents a benign hepatic cystic change or chronic incidental cystic lesion. No overtly aggressive hepatic features are identified ultrasonographically.

Recommendations

- Correlation with GI panel testing, including cobalamin/folate assessment and feline pancreatic lipase immunoreactivity (Spec fPL), is recommended.
- Strict fasting prior to any repeat abdominal ultrasound would improve characterization of the gastrointestinal tract and gastric emptying pattern if clinical signs persist.
- Empiric management for chronic feline enteropathy may be clinically reasonable, including dietary modification, antiemetic therapy, gastrointestinal support, probiotics, and cobalamin supplementation as indicated.

Final diagnostic and therapeutic decisions should be made by the attending veterinarian, who can best integrate these findings with the patient's clinical status.





PATIENT

Mac Armstrong

SPECIES

Feline

BREED

DMH

SEX

Neutered Male

AGE

16 Years

WEIGHT

8.98

INTERPRETED BY

Alicia Angosto
Guerrero, DMV,
PgDip, MSc.

**IMAGING
PERFORMED BY**

Dr. Cassidy Stone

HOSPITAL NAME

Petroglyph Animal
Hospital

REFERRING VET

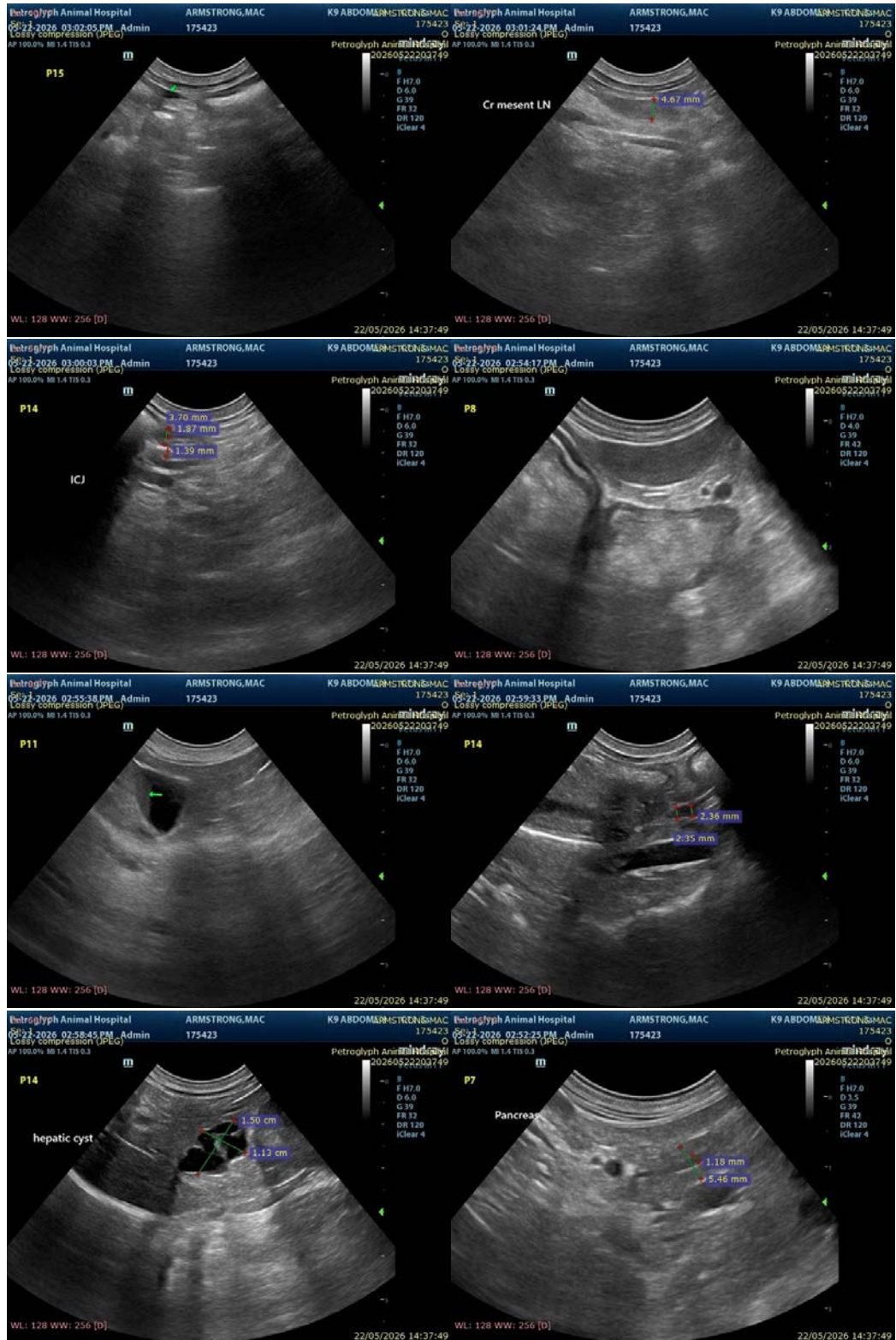
Dr. Cassidy Stone


INVOICE

75460

DATE

5/22/26





PATIENT

Mac Armstrong

SPECIES

Feline

BREED

DMH

SEX

Neutered Male

AGE

16 Years

WEIGHT

8.98

INTERPRETED BY

Alicia Angosto Guerrero, DMV,
PgDip, MSc.

IMAGING PERFORMED BY

Dr. Cassidy Stone

HOSPITAL NAME

Petroglyph Animal Hospital

REFERRING VET

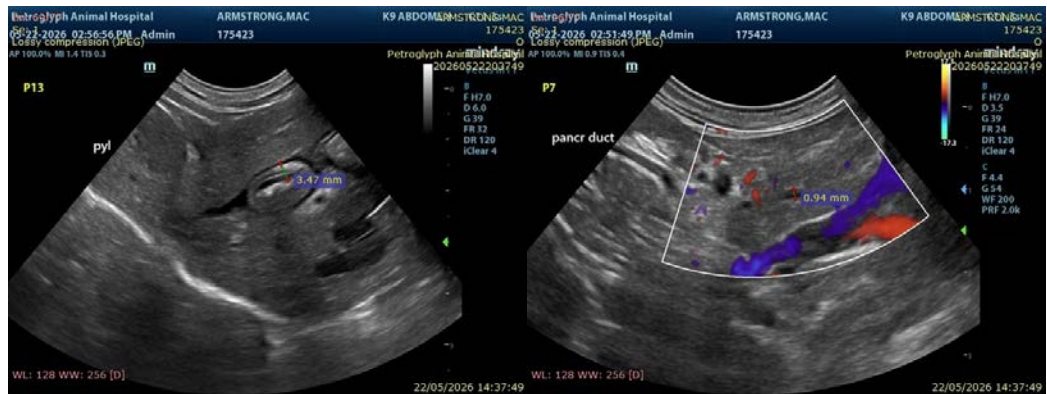
Dr. Cassidy Stone

INVOICE

75460

DATE

5/22/26



The information and recommendations provided are based on the images presented by the referring veterinarian/sonographer. No evaluation can be communicated regarding pathology that was not visible in the image/video clips provided.

Thank you for this referral. If the clinical or image interpretation does not parallel your findings or if I can be of any further assistance please contact me.

Alicia Angosto Guerrero, DMV, PgDip, MSc.

info@SonoPath.com