



## PATIENT

Calla Callahan

## SPECIES

Canine

## BREED

Golden

## SEX

Spayed female

## AGE

7 years

## WEIGHT

74 lbs

## INTERPRETED BY

Alicia Angosto  
Guerrero, DMV,  
PgDip, MSc.

## IMAGING PERFORMED BY

Alison Cornwall

## HOSPITAL NAME

Onion River AH

## REFERRING VET

Dr. Flynn

## INVOICE

75592

## DATE

5/15/26

## PRESENTING CLINICAL SIGNS

History: Bilirubin elevated on routine labs.  
Total bili 0.4 Unconj bili 0.3, Conj bili 0.1 Cholesterol 402

## ULTRASONOGRAPHIC EXAMINATION OF THE ABDOMEN

### *Urinary System*

The urinary bladder lumen is normally distended, and the wall of the urinary bladder appears thin and smooth. The urine is anechoic. The bladder neck and proximal urethra appear normal. There are no calculi and no evidence of inflammatory or neoplastic changes.

The left kidney is normal in shape and size: 6.77×3.05 cm, and the thickness of the cortex is 0.55 cm in the sagittal plane. The right kidney is normal in shape and size: 6.87×3.40 cm, and the thickness of the cortex is 0.58 cm in the sagittal plane. Both kidneys demonstrate cortical echogenicity similar to the hepatic parenchyma. The corticomedullary ratio and corticomedullary definition are preserved. There is no evidence of pyelectasia, nephrolithiasis, or hydronephrosis. Color Doppler demonstrates a normal vascular pattern.

### *Adrenal Glands*

Not confidently visualized.

### *Spleen*

Splenic thickness measures approximately 2.55–2.64 cm. The splenic parenchyma demonstrates normal echogenicity with mildly heterogeneous/mottled echotexture. The splenic capsule is smooth and regular.

### *Liver*

The liver is subjectively normal in size, with sharp edges and a regular contour. The liver parenchyma looks uniform and isoechoic compared to the falciform fat, with a normal echotexture. No hepatic lymphadenopathy is observed.

The gallbladder lumen is normally distended. The wall is thin and the contents are primarily anechoic. No evident dilation of the cystic duct or common bile duct is observed.

### *Gastrointestinal*

The stomach is empty and folded, containing a small amount of luminal fluid. Gastric mural thickness measures approximately 2.44 mm with preserved wall layering. The duodenum measures 2.41 mm. The jejunum measures 2.36 mm. Wall layering is preserved throughout the evaluated gastrointestinal tract. No ultrasonographic evidence of gastrointestinal inflammation, mechanical ileus, foreign material, or



## PATIENT

Calla Callahan

## SPECIES

Canine

## BREED

Golden

## SEX

Spayed female

## AGE

7 years

## WEIGHT

74 lbs

## INTERPRETED BY

Alicia Angosto  
Guerrero, DMV,  
PgDip, MSc.

## IMAGING PERFORMED BY

Alison Cornwall

## HOSPITAL NAME

Onion River AH

## REFERRING VET

Dr. Flynn

## INVOICE

75592

## DATE

5/15/26

obstructive disease is identified. The colon measures approximately 1.03 mm in thickness and contains formed fecal material within the descending segment.

### ***Pancreas***

The evaluated pancreatic regions do not show evidence of overt inflammation or neoplastic disease.

### ***Free Abdomen***

No sonographic evidence of abdominal effusion, peritonitis, or lymphadenomegaly is identified. The iliac trifurcation is normal.

## **PRIMARY FINDINGS**

- Mild nonspecific splenic mottling/heterogeneity
- Mild gastric fluid content

## **INTERPRETATION OF THE FINDINGS & FURTHER RECOMMENDATIONS**

No clinically significant hepatobiliary abnormality is identified ultrasonographically. Specifically, there is no evidence of gallbladder mucocele formation, extrahepatic biliary obstruction, clinically significant cholestatic disease, focal hepatic lesion, or overt diffuse hepatopathy on the current examination. The reported minimal bilirubin elevation and hypercholesterolemia therefore may reflect early/subclinical metabolic, endocrine, or hepatocellular dysfunction not yet associated with overt ultrasonographic abnormalities. Mild vacuolar hepatopathy, early endocrinopathy (including hyperadrenocorticism or hypothyroidism), or mild functional cholestatic change remain possible differential considerations despite the relatively unremarkable hepatobiliary appearance.

Mild splenic mottling is present and is considered a common nonspecific finding in dogs, often associated with benign reactive change, sedation-related splenic alteration, mild congestion, or nodular hyperplasia. No focal splenic mass lesion is identified.

No ultrasonographic evidence of pancreatitis, gastrointestinal disease, abdominal neoplasia, or obstructive urinary disease is identified on the current examination.

### Recommendations

- Correlation with the complete biochemical profile, including ALP, ALT, GGT, triglycerides, thyroid testing, and endocrine screening if clinically indicated, is recommended.
- Serial monitoring of bilirubin, cholesterol, and liver enzymes is advised.

Final diagnostic and therapeutic decisions should be made by the attending veterinarian, who can best integrate these findings with the patient's clinical status.



## PATIENT

Calla Callahan

## SPECIES

Canine

## BREED

Golden

## SEX

Spayed female

## AGE

7 years

## WEIGHT

74 lbs

## INTERPRETED BY

Alicia Angosto  
Guerrero, DMV,  
PgDip, MSc.

## IMAGING PERFORMED BY

Alison Cornwall

## HOSPITAL NAME

Onion River AH

## REFERRING VET

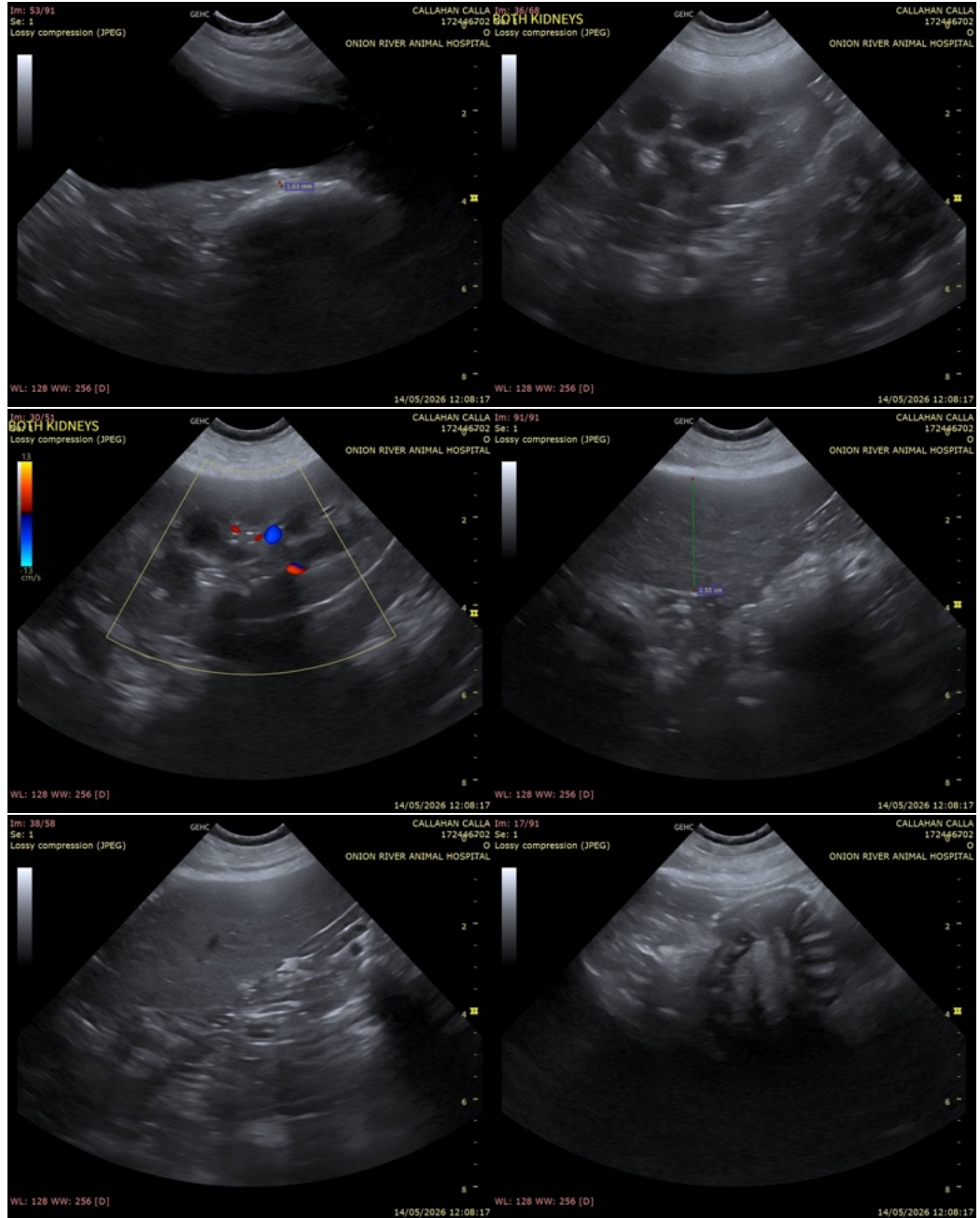
Dr. Flynn

## INVOICE

75592

## DATE

5/15/26





## PATIENT

Calla Callahan

## SPECIES

Canine

## BREED

Golden

## SEX

Spayed female

## AGE

7 years

## WEIGHT

74 lbs

## INTERPRETED BY

Alicia Angosto  
Guerrero, DMV,  
PgDip, MSc.

## IMAGING PERFORMED BY

Alison Cornwall

## HOSPITAL NAME

Onion River AH

## REFERRING VET

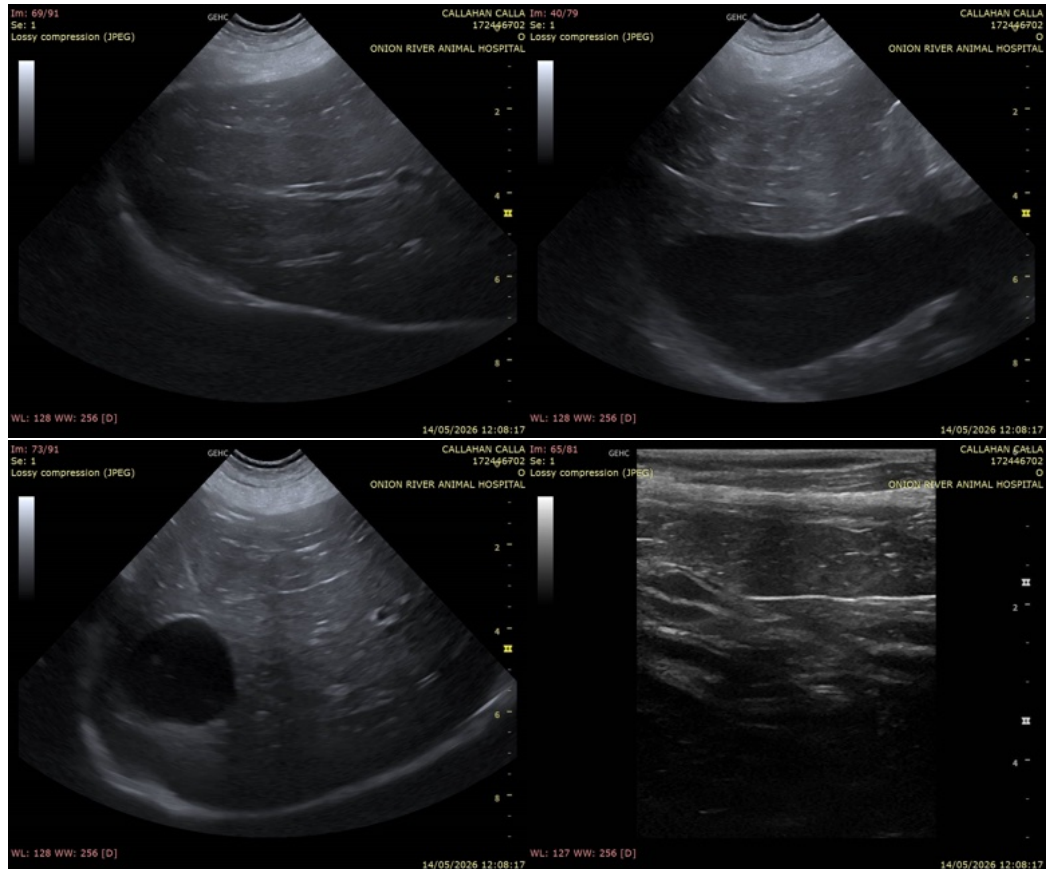
Dr. Flynn

## INVOICE

75592

## DATE

5/15/26



The information and recommendations provided are based on the images presented by the referring veterinarian/sonographer. No evaluation can be communicated regarding pathology that was not visible in the image/video clips provided.

Thank you for this referral. If the clinical or image interpretation does not parallel your findings or if I can be of any further assistance please contact me.

Alicia Angosto Guerrero, DMV, PgDip, MSc.

[info@SonoPath.com](mailto:info@SonoPath.com)