



PATIENT

Pippin Suddard

SPECIES

Canine

BREED

Japanese Spitz

SEX

Spayed female

AGE

4 years

WEIGHT

7.5 kg

INTERPRETED BY

Alicia Angosto
Guerrero, DMV,
PgDip, MSc.

IMAGING PERFORMED BY

Dr. Louise Corbeil

HOSPITAL NAME

Cochrane AC

REFERRING VET

Dr. Louise Corbeil

INVOICE

75378

DATE

5/12/26

PRESENTING CLINICAL SIGNS

History: 1 week history vomiting and hyporexia
05-07-2026 (see diagnostics below) - treated with SQ fluids - 20ml/kg -> 150mL SQ LRS, Emavert 0.75mL SQ, Convenia 0.75mL SQ. Symptoms relapsed. Hasn't eaten since yesterday morning, vomited multiple times throughout last night
Abnormal PE/Chem/CBC/UA Results: 05-07-2026 CBC - Leukocytosis (WBC 25.19, Neut 23.25); Chem - Hypokalemia (2.9 or 2.7 on fresh sample); Unable to get a urine sample - bladder is empty on u/s
Radiographs: Stomach appears small; colon appears gaseous, no apparent FB

ULTRASONOGRAPHIC EXAMINATION OF THE ABDOMEN

Urinary System

The urinary bladder lumen is normally distended, and the wall of the urinary bladder appears thin and smooth. The urine is anechoic. Normal appearance of the bladder neck and proximal urethra. No calculi are identified, and there is no ultrasonographic evidence of inflammatory or neoplastic change.

The left kidney is normal in shape and size, measuring 3.84×2.06 cm, with a cortical thickness of 0.35 cm in the sagittal plane. The renal cortex is isoechoic relative to the hepatic parenchyma. The corticomedullary ratio and corticomedullary definition are preserved. Mild medullary rim sign is present. No evidence of pyelectasia, nephrolithiasis, or hydronephrosis is identified. Color Doppler demonstrates a normal vascular pattern.

The right kidney is normal in shape and size, measuring 4.21×1.86 cm, with a cortical thickness of 0.31 cm in the sagittal plane. The renal cortex is isoechoic relative to the hepatic parenchyma. The corticomedullary ratio and corticomedullary definition are preserved. No evidence of pyelectasia, nephrolithiasis, or hydronephrosis is identified. Color Doppler demonstrates a normal vascular pattern.

Adrenal Glands

Both adrenal glands demonstrate normal shape and echogenicity. Dorsoventral diameters measured in the sagittal plane are as follows: the left adrenal gland measures 0.28 cm at the cranial pole and 0.35 cm at the caudal pole. The right adrenal gland measures 0.39 cm at the cranial pole and 0.34 cm at the caudal pole.

Spleen

Splenic thickness is 1.05 cm. The parenchyma demonstrates normal echogenicity and fine homogeneous echotexture without focal parenchymal abnormalities. The splenic capsule is smooth and regular.

Liver

The liver is subjectively normal in size, with sharp edges and a regular contour. The liver parenchyma looks uniform and isoechoic compared to the falciform fat, with a normal echotexture. No hepatic lymphadenopathy is observed.



PATIENT

Pippin Suddard

SPECIES

Canine

BREED

Japanese Spitz

SEX

Spayed female

AGE

4 years

WEIGHT

7.5 kg

INTERPRETED BY

Alicia Angosto
Guerrero, DMV,
PgDip, MSc.

IMAGING PERFORMED BY

Dr. Louise Corbeil

HOSPITAL NAME

Cochrane AC

REFERRING VET

Dr. Louise Corbeil

INVOICE

75378

DATE

5/12/26

The gallbladder lumen is normally distended. The wall is thin and the contents are primarily anechoic with a very small amount of biliary sludge. No evident dilation of the cystic duct or common bile duct is observed.

Gastrointestinal Tract

The stomach is mildly to moderately fluid-distended. Gastric mural thickness at the fundus measures approximately 2.39 mm. Mild diffuse prominence/thickening of the gastric folds is identified while preserving normal wall layering. No discrete ulcerative lesion, free abdominal fluid, or localized peritonitis is identified. The pylorus measures approximately 4.34-4.55 mm. The duodenum measures 3.78 mm in thickness. The jejunum measures approximately 2.45-3.36 mm in thickness, with preserved wall layering. The mucosa measures 1.80 mm, the submucosa 0.43 mm, and the muscularis propria 0.30 mm. The ileum measures approximately 1.79-2.22 mm in thickness with preserved wall layering. The ileocecal region, particularly at the level of the cecum, demonstrates more marked mural thickening measuring approximately 5.19-6.34 mm, without a discrete mass lesion or associated regional lymphadenopathy. Several small intestinal segments demonstrate mild fluid distension. No ultrasonographic evidence of obstructive foreign material or a mechanical obstructive pattern is identified. The colon measures approximately 1.16-3.29 mm in thickness and is largely empty and collapsed distally, with abundant intraluminal gas.

Pancreas

The pancreas measures approximately 6.95-7.24 mm in thickness. The pancreatic parenchyma is isoechoic relative to the adjacent omental fat. No ultrasonographic evidence of active peripancreatic inflammation is identified.

Free Abdomen

No sonographic evidence of abdominal effusion, peritonitis, or lymphadenomegaly is identified. The iliac trifurcation is normal.

PRIMARY FINDINGS

- Fluid gastric distension with diffuse gastric fold prominence
- Mild multifocal fluid distension of small intestinal loops
- Moderate focal thickening of the ileocecal/cecal region without discrete mass lesion or regional lymphadenopathy

SECONDARY FINDINGS

- Mild left renal medullary rim sign.



PATIENT

Pippin Suddard

SPECIES

Canine

BREED

Japanese Spitz

SEX

Spayed female

AGE

4 years

WEIGHT

7.5 kg

INTERPRETED BY

Alicia Angosto
Guerrero, DMV,
PgDip, MSc.

IMAGING PERFORMED BY

Dr. Louise Corbeil

HOSPITAL NAME

Cochrane AC

REFERRING VET

Dr. Louise Corbeil

INVOICE

75378

DATE

5/12/26

INTERPRETATION OF THE FINDINGS & FURTHER RECOMMENDATIONS

The gastric fold prominence and mild fluid distension are nonspecific but support inflammatory gastric disease/gastritis.

More pronounced mural thickening centered on the ileocecal/cecal region supports focal inflammatory enterocolic disease. Differential considerations include focal typhlitis/cecocolic inflammation, infectious enterocolitis, or other focal inflammatory gastrointestinal disease.

No regional lymphadenopathy, focal mass lesion, transmural loss of layering, perforation, or significant mesenteric inflammatory change is identified, making aggressive infiltrative neoplasia less likely based on the current examination.

With the material provided, there is currently no convincing ultrasonographic evidence of a surgical obstructive gastrointestinal pattern or obstructive foreign body.

Although pancreatitis was raised as a clinical concern, the current ultrasonographic findings do not strongly support clinically significant pancreatitis. Additionally, normal amylase/lipase activities further reduce the likelihood of clinically significant acute pancreatitis.

The marked neutrophilic leukocytosis is most likely reactive/inflammatory in origin and may reasonably correlate with the gastrointestinal abnormalities identified on the current examination, particularly the gastric and ileocecal inflammatory changes. Differential considerations include acute inflammatory enterocolitis, bacterial enteritis, dysbiosis/clostridial enteropathy, focal typhlitis/cecocolic inflammation, parasitic gastrointestinal disease despite previous negative fecal testing, dietary indiscretion, or focal inflammatory enteropathy. Less commonly, infectious enteropathies such as *Campylobacter* or *Salmonella* infection could produce a similar clinical and ultrasonographic pattern.

Recommendations

- Supportive care.
- Fecal PCR/parasitology testing should be considered if not already performed, particularly given the focal ileocecal/cecal inflammatory changes and marked inflammatory leukogram.
- Empirical antiparasitic therapy may also be clinically reasonable despite previous negative fecal testing.
- Additional gastrointestinal infectious disease testing (including consideration of bacterial enteropathies such as *Clostridial* dysbiosis, *Campylobacter*, or *Salmonella* when clinically appropriate) may be considered depending on clinical progression and exposure history.
- Repeat CBC monitoring is recommended to assess progression or resolution of the marked leukocytosis.

Final diagnostic and therapeutic decisions should be made by the attending veterinarian, who can best integrate these findings with the patient's clinical status.



PATIENT

Pippin Suddard

SPECIES

Canine

BREED

Japanese Spitz

SEX

Spayed female

AGE

4 years

WEIGHT

7.5 kg

INTERPRETED BY

Alicia Angosto
Guerrero, DMV,
PgDip, MSc.

IMAGING PERFORMED BY

Dr. Louise Corbeil

HOSPITAL NAME

Cochrane AC

REFERRING VET

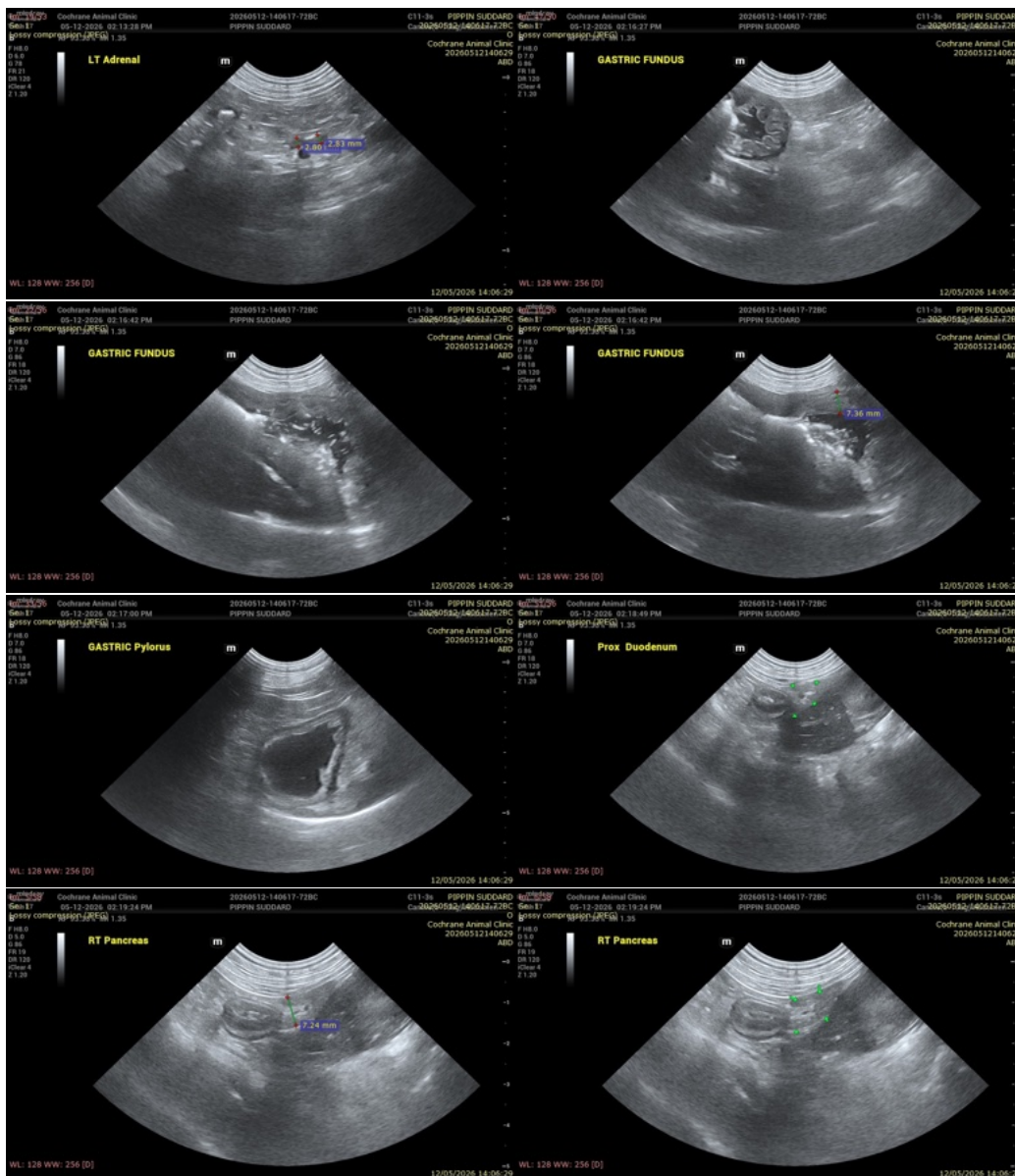
Dr. Louise Corbeil

INVOICE

75378

DATE

5/12/26





PATIENT

Pippin Suddard

SPECIES

Canine

BREED

Japanese Spitz

SEX

Spayed female

AGE

4 years

WEIGHT

7.5 kg

INTERPRETED BY

Alicia Angosto
Guerrero, DMV,
PgDip, MSc.

IMAGING PERFORMED BY

Dr. Louise Corbeil

HOSPITAL NAME

Cochrane AC

REFERRING VET

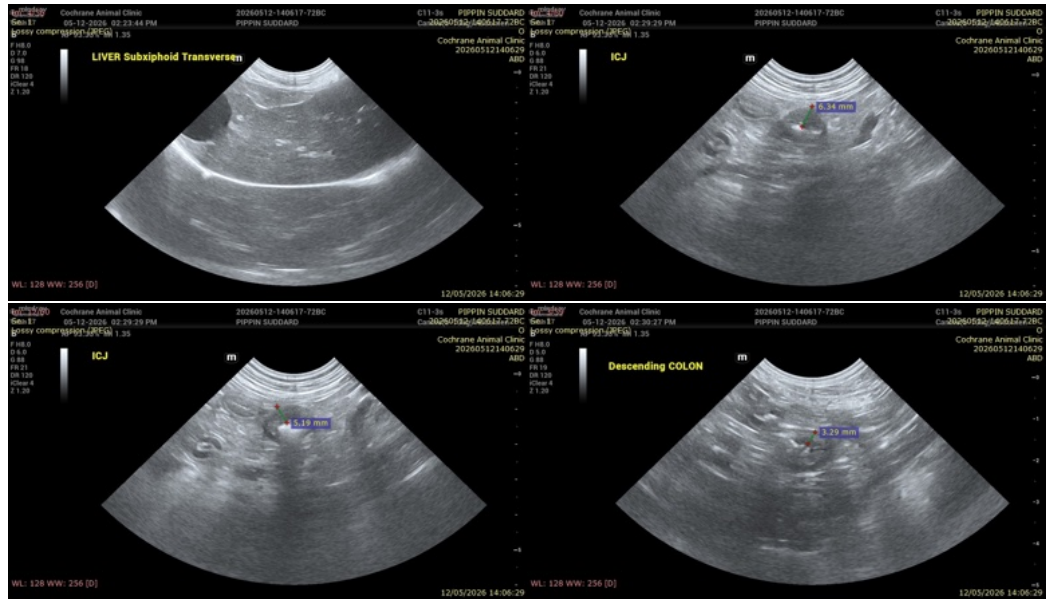
Dr. Louise Corbeil

INVOICE

75378

DATE

5/12/26



The information and recommendations provided are based on the images presented by the referring veterinarian/sonographer. No evaluation can be communicated regarding pathology that was not visible in the image/video clips provided.

Thank you for this referral. If the clinical or image interpretation does not parallel your findings or if I can be of any further assistance please contact me.

Alicia Angosto Guerrero, DMV, PgDip, MSc.

info@SonoPath.com