



PATIENT

Minx Bartlett

SPECIES

Feline

BREED

Domestic Shorthair

SEX

Spayed female

AGE

16 years

WEIGHT

8.8 lbs

INTERPRETED BY

Alicia Angosto
Guerrero, DMV,
PgDip, MSc.

IMAGING PERFORMED BY

Dr. Kathy Cronin

HOSPITAL NAME

Ark Animal Homecare

REFERRING VET

Dr. Cronin

INVOICE

74316

DATE

4/8/26

PRESENTING CLINICAL SIGNS

History of decreased appetite for a few weeks, but eating a little better now. Chronic vomiting about once a week. Weight loss (~1 lb)

CBC/chem/T4/UA 3/25/26 - CBC/T4 wnl, SDMA 17 (0-14), creatinine 3.6 (0.9-2.3), BUN 40 (16-37).
USG 1.014

ULTRASONOGRAPHIC EXAMINATION OF THE ABDOMEN

Urinary System

The urinary bladder is moderately distended, with a thin and smooth wall. The urine is predominantly anechoic with scant suspended echoes. The bladder neck and proximal urethra have a normal appearance. No calculi are identified, and there is no ultrasonographic evidence of inflammatory or neoplastic disease.

The left kidney is normal in shape and size (2.78×2.06 cm), with a cortical thickness of 0.31 cm in the sagittal plane. The cortex is isoechoic compared to the liver parenchyma. The corticomedullary ratio is within normal limits, and corticomedullary definition is preserved. There is no evidence of pyelectasia, nephrolithiasis, or hydronephrosis.

The right kidney is normal in size (2.66×2.09 cm), with a cortical thickness of 0.31 cm. The cortex is isoechoic compared to the liver parenchyma. At the caudal pole, there is a focal hyperechoic cortical lesion associated with mild contour irregularity (cortical indentation). The corticomedullary ratio is otherwise normal and corticomedullary definition is preserved. There is no evidence of pyelectasia, nephrolithiasis, or hydronephrosis.

Adrenal Glands

Both adrenal glands show normal shape and echogenicity. Dorsoventral diameters measured in the sagittal plane: The left adrenal gland measures 0.27 cm at the cranial pole and 0.28 cm at the caudal pole. The right adrenal gland measures 0.28 cm at the cranial pole and 0.29 cm at the caudal pole.

Spleen

Splenic thickness is 0.65 cm. The parenchyma demonstrates normal echogenicity and fine homogeneous echotexture without focal parenchymal abnormalities. The splenic capsule is smooth and regular.

Liver

The liver is subjectively normal in size, with sharp edges and a regular contour. The liver parenchyma looks uniform and isoechoic compared to the falciform fat, with a normal echotexture. No hepatic lymphadenopathy is observed.

The gallbladder lumen is normally distended. The wall is thin and the contents are primarily anechoic. No evident dilation of the cystic duct or common bile duct is observed.



PATIENT

Minx Bartlett

SPECIES

Feline

BREED

Domestic Shorthair

SEX

Spayed female

AGE

16 years

WEIGHT

8.8 lbs

INTERPRETED BY

Alicia Angosto
Guerrero, DMV,
PgDip, MSc.

IMAGING PERFORMED BY

Dr. Kathy Cronin

HOSPITAL NAME

Ark Animal Homecare

REFERRING VET

Dr. Cronin

INVOICE

74316

DATE

4/8/26

Gastrointestinal

The stomach contains ingesta, with a wall thickness of 1.63–2.17 mm and preserved layering. The pylorus is not visualized. The duodenum measures 1.68 mm. The jejunum measures 1.95 mm in total thickness, with mucosa 1.02 mm, submucosa 0.56 mm, and muscularis propria 0.38 mm. The ileum measures 1.95 mm in total thickness, with mucosa 0.71 mm, submucosa 0.65 mm, and muscularis propria 0.47 mm. Wall layering is preserved throughout. The ileocecal junction is not visualized. No ultrasonographic evidence of ileus, obstruction, or inflammatory enteropathy is identified. The colon wall is 0.70 mm and contains formed feces in the descending segment.

Pancreas

The pancreas measures approximately 4.29 mm in thickness. The parenchyma is isoechoic relative to the adjacent omental fat. The pancreatic duct measures 1.11 mm. No peripancreatic fat changes are identified.

Free Abdomen

No abdominal effusion, peritonitis, or lymphadenomegaly is identified. The iliac trifurcation appears unremarkable.

PRIMARY FINDINGS

- Focal hyperechoic cortical lesion in the right kidney with contour indentation.

SECONDARY FINDINGS

- Mild prominence of the pancreatic duct.

INTERPRETATION OF THE FINDINGS & FURTHER RECOMMENDATIONS

The primary finding in this study is a focal hyperechoic cortical lesion in the right kidney associated with mild contour indentation, most consistent with chronic cortical scarring, likely secondary to prior ischemic or inflammatory insult (infarct or chronic interstitial change). This is a chronic and incidental-type finding, but may contribute to the patient's overall renal disease burden.

The documented azotemia and isosthenuria, are consistent with chronic kidney disease. Notably, ultrasonographic changes in feline CKD can be mild or even minimal, and the absence of marked structural abnormalities does not exclude clinically significant renal dysfunction.

The gastrointestinal tract is within normal limits, with no ultrasonographic evidence of inflammatory or infiltrative disease. Therefore, the reported clinical signs (decreased appetite, vomiting, and weight loss) may be partially or primarily attributable to uremia associated with CKD, although concurrent mild gastrointestinal disease cannot be entirely excluded.



PATIENT

Minx Bartlett

SPECIES

Feline

BREED

Domestic Shorthair

SEX

Spayed female

AGE

16 years

WEIGHT

8.8 lbs

INTERPRETED BY

Alicia Angosto
Guerrero, DMV,
PgDip, MSc.

IMAGING PERFORMED BY

Dr. Kathy Cronin

HOSPITAL NAME

Ark Animal Homecare

REFERRING VET

Dr. Cronin

INVOICE

74316

DATE

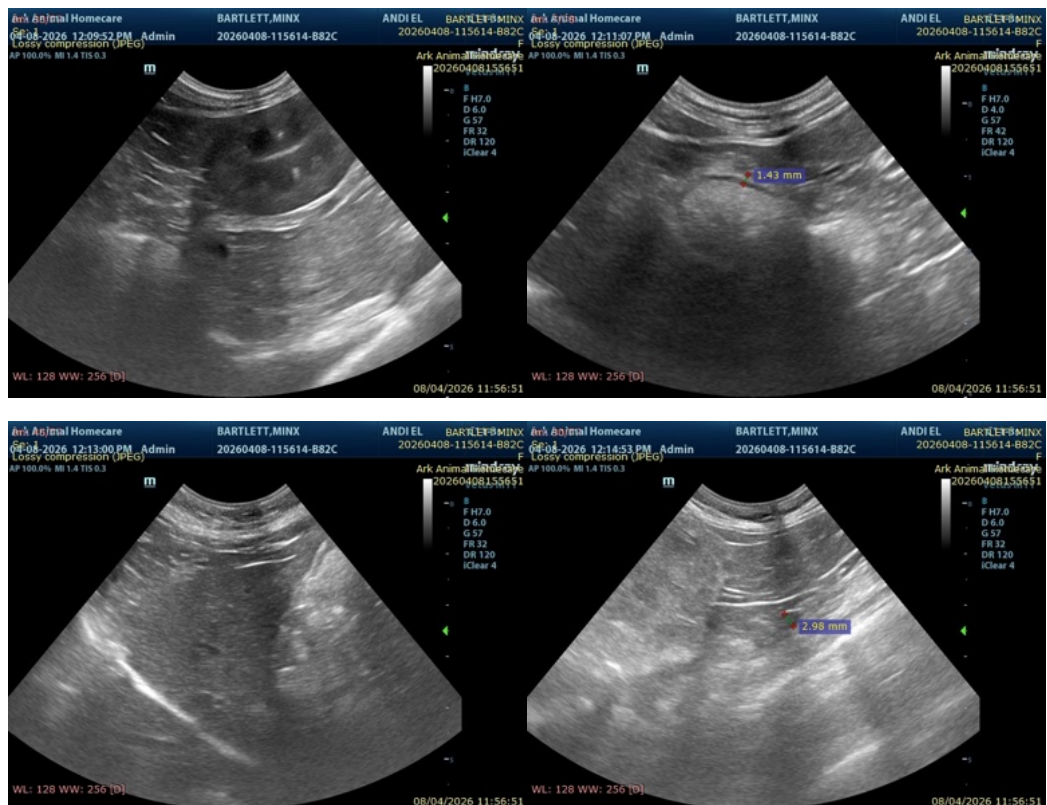
4/8/26

The pancreas is unremarkable, although the pancreatic duct is mildly prominent, which may be age-related or associated with chronic low-grade change.

Recommendations

- Clinical management of chronic kidney disease is recommended (if not already initiated).
- Supportive therapy for uremia-associated nausea (antiemetics, appetite support) may be beneficial.
- Monitoring of renal parameters is advised.
- If gastrointestinal signs persist despite appropriate renal management, additional evaluation (cobalamin, fPLI) may be considered.

Final diagnostic and therapeutic decisions should be made by the attending veterinarian, who can best integrate these findings with the patient's clinical status.





PATIENT

Minx Bartlett

SPECIES

Feline

BREED

Domestic Shorthair

SEX

Spayed female

AGE

16 years

WEIGHT

8.8 lbs

INTERPRETED BY

Alicia Angosto
Guerrero, DMV,
PgDip, MSc.

**IMAGING
PERFORMED BY**

Dr. Kathy Cronin

HOSPITAL NAME

Ark Animal Homecare

REFERRING VET

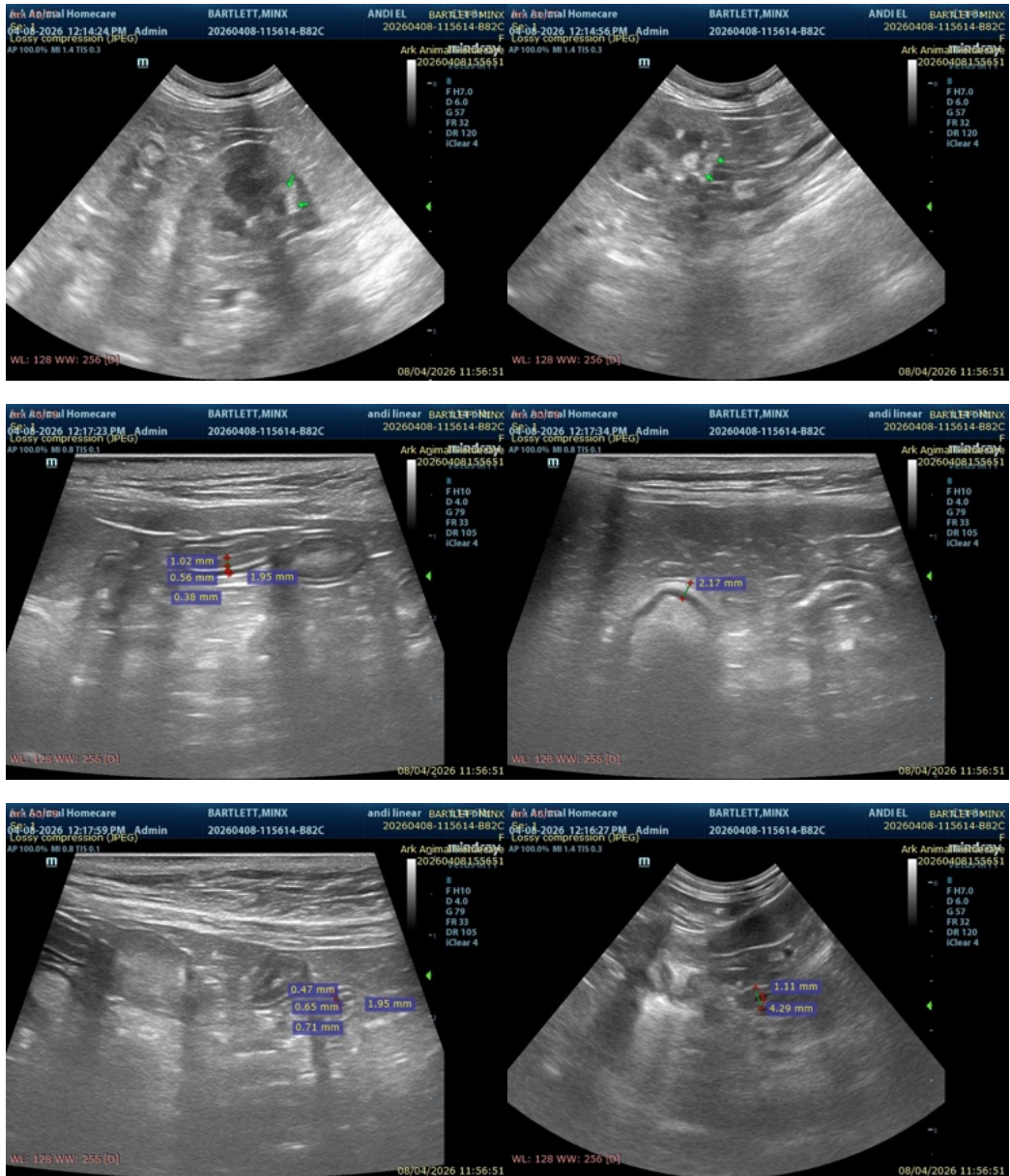
Dr. Cronin

INVOICE

74316

DATE

4/8/26



The information and recommendations provided are based on the images presented by the referring veterinarian/sonographer. No evaluation can be communicated regarding pathology that was not visible in the image/video clips provided.

Thank you for this referral. If the clinical or image interpretation does not parallel your findings or if I can be of any further assistance please contact me.

Alicia Angosto Guerrero, DMV, PgDip, MSc.

info@SonoPath.com