



## PATIENT

Gemma Archer

## SPECIES

Feline

## BREED

Domestic Shorthair

## SEX

Spayed female

## AGE

11 years

## WEIGHT

10.09 lbs

## INTERPRETED BY

Alicia Angosto  
Guerrero, DMV,  
PgDip, MSc.

## IMAGING PERFORMED BY

Brittney Beigel, DVM

## HOSPITAL NAME

Bayside Animal  
Medical Center

## REFERRING VET

Dr. Buchanan

## INVOICE

74311

## DATE

4/8/26

## PRESENTING CLINICAL SIGNS

History: 3# unexplained wt loss over the course of the year, chronic vomiting  
Abnormal PE/Chem/CBC/UA Results: Attached/unremarkable

## ULTRASONOGRAPHIC EXAMINATION OF THE ABDOMEN

### *Urinary System*

The urinary bladder is normally distended, with a thin and smooth wall. The urine is anechoic. The bladder neck and proximal urethra have a normal appearance. No calculi are identified, and there is no ultrasonographic evidence of inflammatory or neoplastic disease.

The left kidney is normal in shape and size (3.57×2.31 cm), with a cortical thickness of 0.34 cm in the sagittal plane. The right kidney is normal in shape and size (3.85×2.17 cm), with a cortical thickness of 0.38 cm in the sagittal plane. In both kidneys, the cortex demonstrates normal echogenicity. The corticomedullary ratio is within normal limits, and corticomedullary definition is preserved. There is no evidence of pyelectasia, nephrolithiasis, or hydronephrosis.

### *Adrenal Glands*

Both adrenal glands demonstrate normal shape and echogenicity. The left adrenal gland measures 0.30 cm at the cranial pole and 0.35 cm at the caudal pole, with small focal mineralizations noted within the adrenal tissue. The right adrenal gland measures 0.27 cm at the cranial pole and 0.26 cm at the caudal pole. These measurements are within normal limits for a cat.

### *Spleen*

Splenic thickness is 0.77 cm. The parenchyma demonstrates normal echogenicity and fine homogeneous echotexture without focal parenchymal abnormalities. The splenic capsule is smooth and regular.

### *Liver*

The liver is subjectively normal in size, with sharp edges and a regular contour. The liver parenchyma looks uniform and isoechoic compared to the falciform fat, with a normal echotexture. No hepatic lymphadenopathy is observed.

The gallbladder lumen is normally distended. The wall is thin and the contents are primarily anechoic. No evident dilation of the cystic duct or common bile duct is observed.

### *Gastrointestinal*

The stomach is empty and folded, containing a small amount of fluid and gas. The gastric wall measures 1.54 mm, with preserved layering. The pylorus measures 2.78 mm. The duodenum measures 1.51 mm. The jejunum measures 2.32 mm in total thickness, with mucosa 1.22 mm, submucosa 0.58 mm, and



## PATIENT

Gemma Archer

## SPECIES

Feline

## BREED

Domestic Shorthair

## SEX

Spayed female

## AGE

11 years

## WEIGHT

10.09 lbs

## INTERPRETED BY

Alicia Angosto  
Guerrero, DMV,  
PgDip, MSc.

## IMAGING PERFORMED BY

Brittney Beigel, DVM

## HOSPITAL NAME

Bayside Animal  
Medical Center

## REFERRING VET

Dr. Buchanan

## INVOICE

74311

## DATE

4/8/26

muscularis propria 0.43 mm. Wall layering is preserved. The ileum measures 2.04 mm in total thickness, with mucosa 0.67 mm, submucosa 0.56 mm, and muscularis propria 0.69 mm. Wall layering is preserved. The ileocecal junction measures 3.33 mm, with a muscularis layer measuring 1.35 mm. The colon measures 1 mm in wall thickness and contains formed feces with marked distal acoustic shadowing in the descending segment.

### ***Pancreas***

The pancreas measures 5.7 mm in thickness. The parenchyma is isoechoic relative to the adjacent omental fat. The pancreatic duct is not dilated. No peripancreatic fat changes are identified.

### ***Free Abdomen***

No sonographic evidence of abdominal effusion, peritonitis, or lymphadenomegaly is identified. The iliac trifurcation appears normal.

## PRIMARY FINDINGS

- Mild relative thickening of the ileal and ileocecal muscularis layer.

## SECONDARY FINDINGS

- Mild focal adrenal mineralization (left adrenal gland).

## INTERPRETATION OF THE FINDINGS & FURTHER RECOMMENDATIONS

This study demonstrates subtle but potentially clinically relevant intestinal changes, primarily characterized by a relative increase in muscularis thickness at the level of the ileum and ileocecal junction.

In the jejunum, the muscularis-to-mucosa ratio is approximately 0.35, which is within normal limits. However, in the ileum, the ratio  $\approx$  1.0. At the ileocecal junction, the muscularis measures 1.35 mm within a total wall thickness of 3.33 mm, indicating that the muscularis accounts for a relatively increased proportion of the mural thickness at this level.

This pattern is subtle and nonspecific, but is recognized in cats with chronic enteropathy, including both inflammatory bowel disease and low-grade (small cell) lymphoma, with ultrasonographic overlap between these two etiologies. Importantly, wall layering is preserved, and overall wall thickness remains within normal limits, which argues against high-grade or aggressive infiltrative disease.

No additional ultrasonographic abnormalities (lymphadenomegaly, mesenteric fat changes, or pancreatic inflammation) are identified to support more advanced or systemic disease. Overall, the findings are most consistent with mild or early chronic enteropathy.



## PATIENT

Gemma Archer

## SPECIES

Feline

## BREED

Domestic Shorthair

## SEX

Spayed female

## AGE

11 years

## WEIGHT

10.09 lbs

## INTERPRETED BY

Alicia Angosto  
Guerrero, DMV,  
PgDip, MSc.

## IMAGING PERFORMED BY

Brittney Beigel, DVM

## HOSPITAL NAME

Bayside Animal  
Medical Center

## REFERRING VET

Dr. Buchanan

## INVOICE

74311

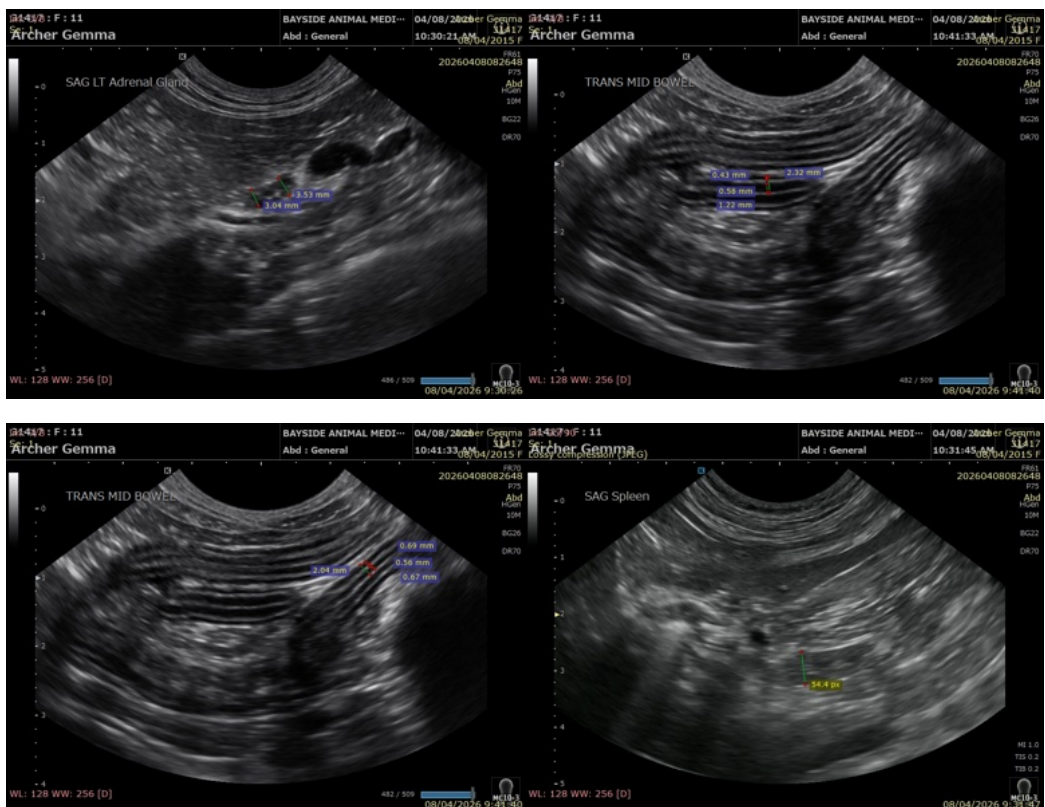
## DATE

4/8/26

## Recommendations

- A dietary trial (novel protein or hydrolyzed diet) is recommended as a first-line approach.
- Assessment of serum cobalamin and folate is advised, with supplementation as indicated.
- Follow-up ultrasound may be useful to monitor for progression.
- If clinical signs and ultrasonographic findings worsen, intestinal biopsy should be considered for definitive diagnosis.

Final diagnostic and therapeutic decisions should be made by the attending veterinarian, who can best integrate these findings with the patient's clinical status.





## PATIENT

Gemma Archer

## SPECIES

Feline

## BREED

Domestic Shorthair

## SEX

Spayed female

## AGE

11 years

## WEIGHT

10.09 lbs

## INTERPRETED BY

Alicia Angosto  
Guerrero, DMV,  
PgDip, MSc.

## IMAGING PERFORMED BY

Brittney Beigel, DVM

## HOSPITAL NAME

Bayside Animal  
Medical Center

## REFERRING VET

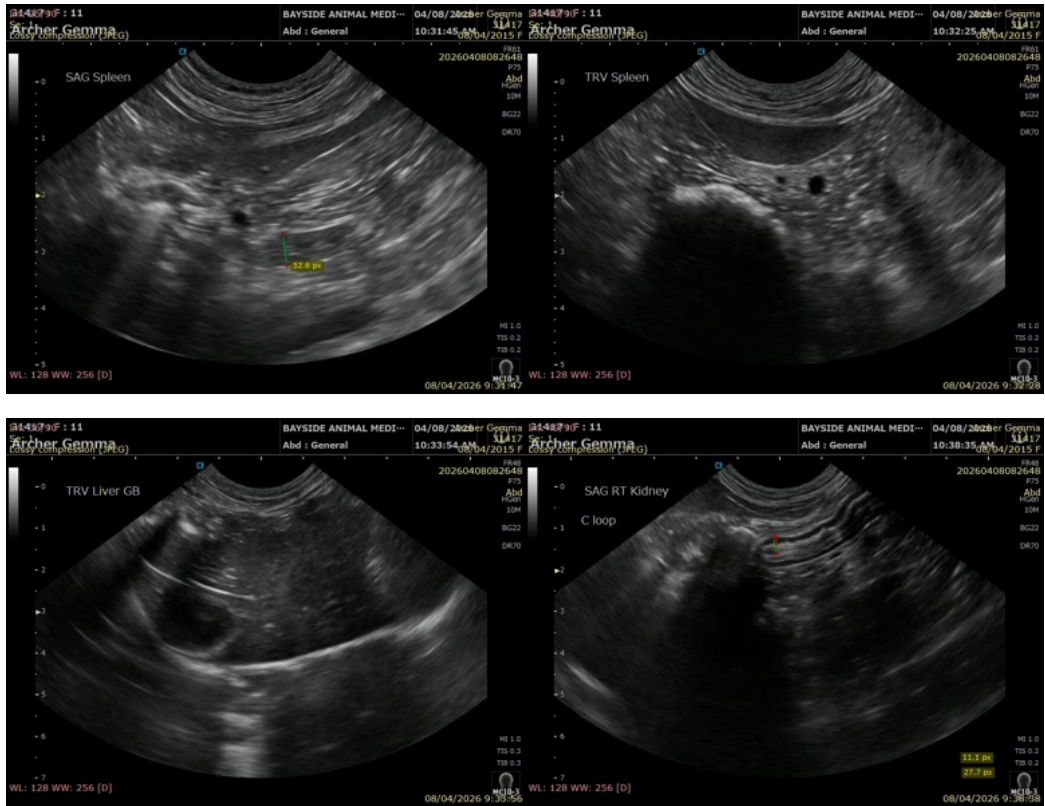
Dr. Buchanan

## INVOICE

74311

## DATE

4/8/26



The information and recommendations provided are based on the images presented by the referring veterinarian/sonographer. No evaluation can be communicated regarding pathology that was not visible in the image/video clips provided.

Thank you for this referral. If the clinical or image interpretation does not parallel your findings or if I can be of any further assistance please contact me.

Alicia Angosto Guerrero, DMV, PgDip, MSc.

[info@SonoPath.com](mailto:info@SonoPath.com)