



PATIENT

Benny Ortiz

SPECIES

Canine

BREED

Havanese Mix

SEX

Neutered male

AGE

7 years

WEIGHT

20.3 lbs

INTERPRETED BY

Alicia Angosto
Guerrero, DMV,
PgDip, MSc.

IMAGING PERFORMED BY

Dr. Vega

HOSPITAL NAME

Animalis Veterinary
Group

REFERRING VET

Dr. Vega

INVOICE

74243

DATE

4/7/26

PRESENTING CLINICAL SIGNS

- Patient presented for abdominal ultrasound prior to anesthesia for dental cleaning and mass removal. Owner reports a mass was first noted in January 2026 on the right lateral abdomen. The mass is cutaneous/subcutaneous, soft on palpation, freely movable/easily grasped, and measures approximately 2 x 2 cm. Patient is BAR, with a normal appetite. No vomiting or diarrhea reported. No PU/PD or abdominal enlargement noted.
- ALT 131 (0-125), ALKP 626 (23-212), ALB 4.2 (2.3-4.0)

ULTRASONOGRAPHIC EXAMINATION OF THE ABDOMEN

Urinary System

The urinary bladder is moderately distended. The bladder wall is thin, smooth, and regular. The luminal contents are anechoic. The bladder neck and proximal urethra have a normal appearance. No evidence of urolithiasis or inflammatory or proliferative changes is identified.

The left kidney is normal in shape and size, measuring 4.69×2.85 cm in the sagittal plane. Cortical thickness is 0.42 cm. The cortex is isoechoic compared to the hepatic parenchyma. The corticomedullary ratio is within normal limits, and corticomedullary definition is preserved. There is no evidence of pyelectasia, nephrolithiasis, or hydronephrosis. Color Doppler demonstrates a normal vascular pattern.

The right kidney is normal in shape and size, measuring 4.60×2.48 cm in the sagittal plane. Cortical thickness is not recorded. The cortex is isoechoic compared to the hepatic parenchyma. The corticomedullary ratio is within normal limits, and corticomedullary definition is preserved. There is no evidence of pyelectasia, nephrolithiasis, or hydronephrosis. Color Doppler demonstrates a normal vascular pattern.

Prostate

The prostate measures 1.79×0.80 cm, is homogeneous and hypoechoic, consistent with post-castration atrophy.

Adrenal Glands

The left adrenal gland measures 0.50 cm at the cranial pole and 0.57 cm at the caudal pole, with normal shape and echogenicity. The right adrenal gland is not confidently visualized.

Spleen

Splenic thickness is 1.37 cm. The parenchyma demonstrates normal echogenicity and fine homogeneous echotexture without focal parenchymal abnormalities. The splenic capsule is smooth and regular.



PATIENT

Benny Ortiz

SPECIES

Canine

BREED

Havanese Mix

SEX

Neutered male

AGE

7 years

WEIGHT

20.3 lbs

INTERPRETED BY

Alicia Angosto
Guerrero, DMV,
PgDip, MSc.

IMAGING PERFORMED BY

Dr. Vega

HOSPITAL NAME

Animalis Veterinary
Group

REFERRING VET

Dr. Vega

INVOICE

74243

DATE

4/7/26

Liver

The liver is subjectively mildly enlarged, with smooth margins and a regular contour. The hepatic parenchyma is homogeneous and isoechoic compared to the falciform fat, with no focal lesions identified. No hepatic lymphadenopathy is observed.

The gallbladder is moderately distended. The wall is thin and regular. The luminal contents are predominantly anechoic with a small amount of biliary sludge. No biliary ductal dilation is identified.

Gastrointestinal

The stomach is empty and folded, with a wall thickness of 2.15 mm and preserved layering. The pylorus measures 4.94 mm. Duodenum: 3.01 mm. Jejunum: 3.10 mm, with mucosa 1.77 mm, submucosa 0.66 mm, and muscularis propria 0.50 mm. Wall layering is preserved. No evidence of ileus, obstruction, or intraluminal foreign material is identified. Colon measures 0.51 mm, containing formed fecal material.

Pancreas

The pancreas measures approximately 0.87 cm in thickness. The parenchyma is isoechoic relative to surrounding fat, with no evidence of inflammation or focal lesions.

Free Abdomen

No sonographic evidence of abdominal effusion, peritonitis, or lymphadenomegaly is identified. The iliac trifurcation appears normal.

PRIMARY FINDINGS

- Mild hepatomegaly.
- Small amount of biliary sludge.

INTERPRETATION OF THE FINDINGS & FURTHER RECOMMENDATIONS

This abdominal ultrasound demonstrates mild hepatomegaly with otherwise normal hepatic parenchymal echogenicity and echotexture, and no evidence of focal lesions or biliary obstruction.

Given the biochemical profile characterized by a marked elevation in ALP with only mild ALT increase and normal GGT and bilirubin, these findings are most consistent with a non-obstructive hepatopathy, commonly associated with vacuolar hepatopathy or enzyme induction.

The absence of biliary ductal dilation, gallbladder wall abnormalities, or parenchymal distortion further supports that there is no ultrasonographic evidence of clinically significant hepatobiliary disease.

The adrenal gland visualized is within normal limits in size (left adrenal up to 0.57 cm; generally expected ≤ 0.7 cm in dogs), and there are no ultrasonographic features strongly suggestive of



PATIENT

Benny Ortiz

SPECIES

Canine

BREED

Havanese Mix

SEX

Neutered male

AGE

7 years

WEIGHT

20.3 lbs

INTERPRETED BY

Alicia Angosto
Guerrero, DMV,
PgDip, MSc.

IMAGING PERFORMED BY

Dr. Vega

HOSPITAL NAME

Animalis Veterinary
Group

REFERRING VET

Dr. Vega

INVOICE

74243

DATE

4/7/26

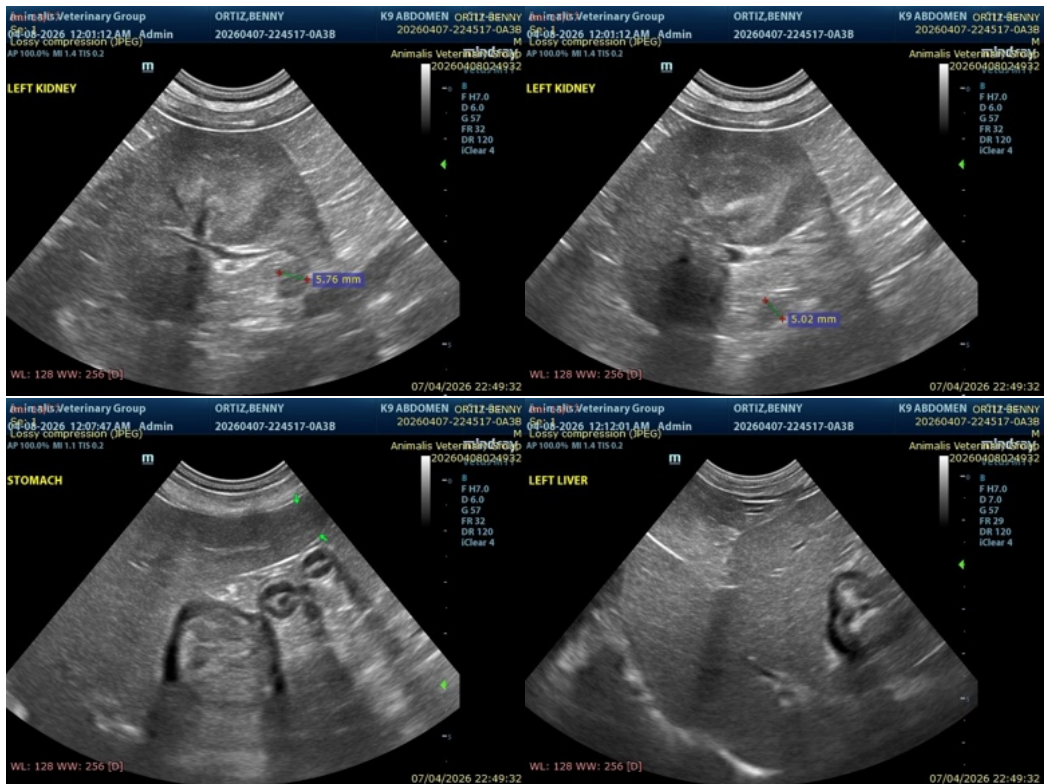
hyperadrenocorticism. However, the right adrenal gland was not visualized, and ultrasound cannot exclude functional endocrine disease, and hyperadrenocorticism remains a clinical differential given the enzyme pattern.

Overall, these findings are most consistent with a mild, likely benign or functional hepatopathy, which correlates with the laboratory abnormalities and does not indicate a primary structural hepatic or biliary disorder.

Recommendations

- Findings are not considered a contraindication for anesthesia in a clinically stable patient.
- Continued clinical monitoring of liver enzymes is recommended.
- If clinical suspicion persists, screening for hyperadrenocorticism may be considered.
- Hepatoprotective therapy may be continued, although identification of an underlying cause (if present) remains clinically relevant.

Final diagnostic and therapeutic decisions should be made by the attending veterinarian, who can best integrate these findings with the patient's clinical status.





PATIENT

Benny Ortiz

SPECIES

Canine

BREED

Havanese Mix

SEX

Neutered male

AGE

7 years

WEIGHT

20.3 lbs

INTERPRETED BY

Alicia Angosto
Guerrero, DMV,
PgDip, MSc.

IMAGING PERFORMED BY

Dr. Vega

HOSPITAL NAME

Animalis Veterinary
Group

REFERRING VET

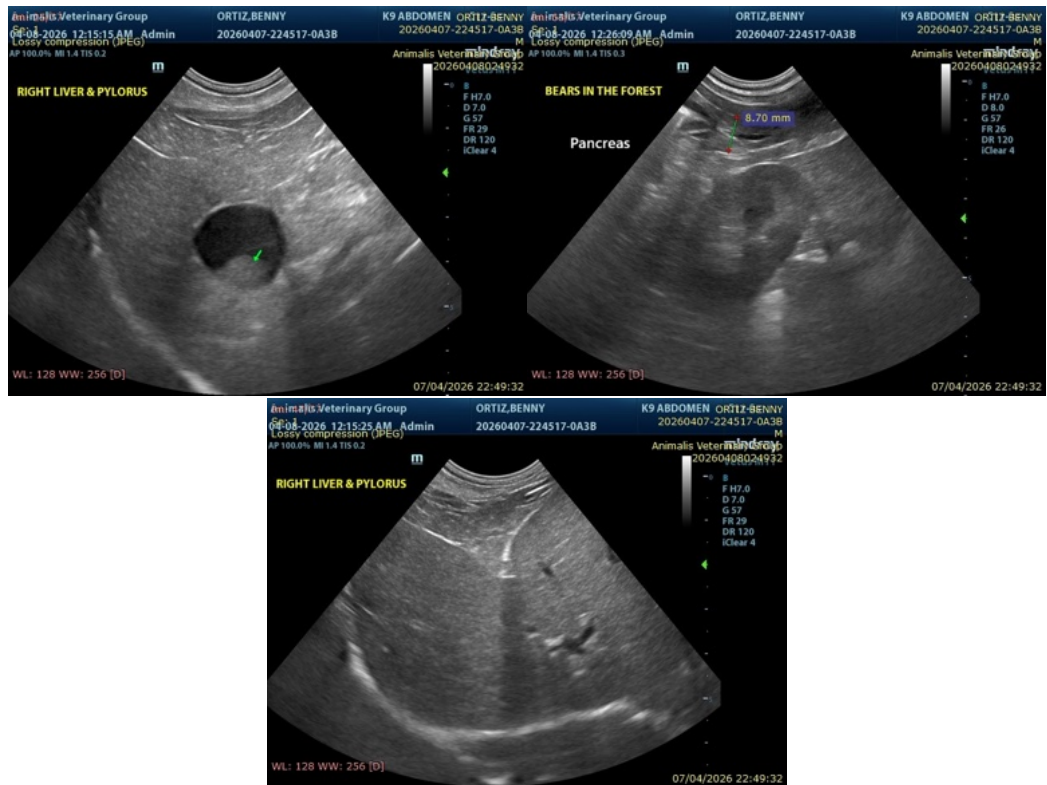Dr. Vega

INVOICE

74243

DATE

4/7/26



The information and recommendations provided are based on the images presented by the referring veterinarian/sonographer. No evaluation can be communicated regarding pathology that was not visible in the image/video clips provided.

Thank you for this referral. If the clinical or image interpretation does not parallel your findings or if I can be of any further assistance please contact me.

Alicia Angosto Guerrero, DMV, PgDip, MSc.

info@SonoPath.com