



PATIENT

Ozzie DeSomma

SPECIES

Canine

BREED

Mix

SEX

Intact male

AGE

9 years

WEIGHT

66 lbs

INTERPRETED BY

Alicia Angosto
Guerrero, DMV,
PgDip, MSc.

IMAGING PERFORMED BY

Rebekah Keller

HOSPITAL NAME

Flanders VC

REFERRING VET

Dr. Cheng

INVOICE

74949

DATE

4/28/26

PRESENTING CLINICAL SIGNS

History: Decreased appetite

Frequent urination (small amounts)

Radiographic findings - mass caudal abdomen

Abnormal PE/Chem/CBC/UA Results: Urine SG 1.006 Ph 8 Blood +2

ULTRASONOGRAPHIC EXAMINATION OF THE ABDOMEN

Urinary System

The urinary bladder is normally distended, with a thin and smooth wall. The urine is markedly turbid, with diffuse echogenic material in suspension, compatible with cellular debris (blood, inflammatory cells, or purulent content). The bladder neck and proximal urethra appear normal. No calculi or focal mural lesions are identified.

The left kidney measures 5.99×3.57 cm, with a cortical thickness of 0.60 cm in the sagittal plane. The cortex is isoechoic relative to the liver parenchyma. The corticomedullary ratio is within normal limits, and corticomedullary definition is preserved. No pyelectasia, nephrolithiasis, or hydronephrosis is identified.

The right kidney is normal in shape and size (measurements not recorded). The cortex is isoechoic relative to the liver parenchyma. The corticomedullary ratio is within normal limits, and corticomedullary definition is preserved. No pyelectasia, nephrolithiasis, or hydronephrosis is identified.

Prostate

The prostate is markedly enlarged, measuring 10.07×6.56 cm (markedly above expected size; typical intact dog prostate approximately 2.5–4.5 cm depending on body size). The parenchyma is heterogeneous, with small mineralized foci. A cystic structure measuring 2.53×1.64 cm is identified. Caudally, there is an additional cavitory lesion measuring 2.06×3.07 cm containing markedly echogenic/turbid material, more consistent with an abscess than a simple cyst.

Adrenal Glands

Both adrenal glands show normal shape and echogenicity. Dorsoventral diameters measured in the sagittal plane: The left adrenal gland measures 0.60 cm at the cranial pole and 0.58 cm at the caudal pole. The right adrenal gland measures 0.63 cm at the cranial pole and 0.58 cm at the caudal pole.

Spleen

Splenic thickness is 2.31 cm. The parenchyma demonstrates normal echogenicity and fine homogeneous echotexture without focal parenchymal abnormalities. The splenic capsule is smooth and regular.



PATIENT

Ozzie DeSomma

SPECIES

Canine

BREED

Mix

SEX

Intact male

AGE

9 years

WEIGHT

66 lbs

INTERPRETED BY

Alicia Angosto
Guerrero, DMV,
PgDip, MSc.

IMAGING PERFORMED BY

Rebekah Keller

HOSPITAL NAME

Flanders VC

REFERRING VET

Dr. Cheng

INVOICE

74949

DATE

4/28/26

Liver

The liver is subjectively normal in size, with sharp edges and a regular contour. The liver parenchyma looks uniform and isoechoic compared to the falciform fat, with a normal echotexture. No hepatic lymphadenopathy is observed.

The gallbladder lumen is normally distended. The wall is thin and the contents are primarily anechoic. No evident dilation of the cystic duct or common bile duct is observed.

Gastrointestinal

The stomach is empty and folded, with a wall thickness of 4.29 mm and preserved layering (within normal limits). The pylorus measures 6.91 mm, within normal limits. The duodenum measures 3.46 mm and the jejunum 3.82 mm, both within normal limits, with preserved wall layering. No evidence of inflammation, ileus, or foreign material is identified. The colon measures 0.87 mm, within normal limits, with formed feces.

Pancreas

The evaluated pancreatic regions do not show evidence of overt inflammation or neoplastic disease.

Free Abdomen

No sonographic evidence of abdominal effusion, peritonitis, or lymphadenomegaly is identified. The iliac trifurcation is normal.

PRIMARY FINDINGS

- Marked prostatomegaly with heterogeneous parenchyma.
- Prostatic cyst.
- Cavitory lesion with turbid content consistent.
- Diffusely turbid urinary bladder contents (compatible with inflammatory or hemorrhagic debris).

INTERPRETATION OF THE FINDINGS & FURTHER RECOMMENDATIONS

This study identifies a severely enlarged, structurally abnormal prostate, with both cystic change and a cavitory lesion containing echogenic debris. The degree of enlargement is marked and clearly accounts for the caudal abdominal mass identified radiographically.

The combination of heterogeneous parenchyma, mineralization, cystic structures, and abscess formation is most consistent with chronic prostatic disease complicated by infection, most likely evolving from benign prostatic hyperplasia with secondary prostatitis and abscess formation. The markedly turbid urinary bladder contents further support the presence of active lower urinary tract inflammation and/or infection, which is likely associated with prostatic disease.



PATIENT

Ozzie DeSomma

SPECIES

Canine

BREED

Mix

SEX

Intact male

AGE

9 years

WEIGHT

66 lbs

INTERPRETED BY

Alicia Angosto
Guerrero, DMV,
PgDip, MSc.

IMAGING PERFORMED BY

Rebekah Keller

HOSPITAL NAME

Flanders VC

REFERRING VET

Dr. Cheng

INVOICE

74949

DATE

4/28/26

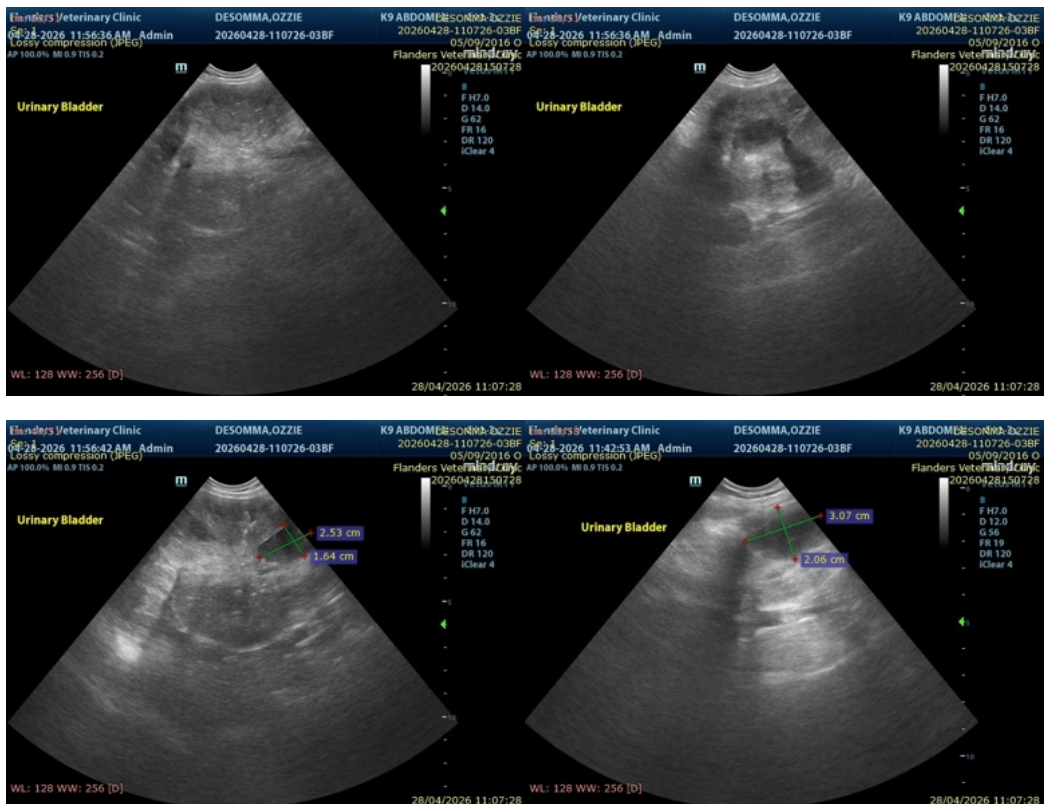
While prostatic neoplasia cannot be completely excluded—particularly given the presence of mineralization—the overall pattern (large size, cystic change, abscess formation, intact male) is more strongly supportive of benign hyperplastic and infectious processes rather than primary malignancy.

The kidneys are structurally unremarkable, and there is no evidence of upper urinary tract involvement at this time. However, the reported hyposthenuria is not explained by the imaging findings and suggests a concurrent functional or systemic process affecting urine concentration, which should be evaluated independently.

Recommendations

- Ultrasound-guided sampling (FNA) may be considered for cytology and culture, if clinically safe, to guide antimicrobial therapy.
- Urine culture and sensitivity testing is recommended.
- Definitive treatment (castration) is strongly recommended, as this is critical for long-term control of prostatic disease.
- In cases of large or non-responsive abscesses, drainage or surgical intervention may be required.

Final diagnostic and therapeutic decisions should be made by the attending veterinarian, who can best integrate these findings with the patient’s clinical status.





PATIENT

Ozzie DeSomma

SPECIES

Canine

BREED

Mix

SEX

Intact male

AGE

9 years

WEIGHT

66 lbs

INTERPRETED BY

Alicia Angosto
Guerrero, DMV,
PgDip, MSc.

IMAGING PERFORMED BY

Rebekah Keller

HOSPITAL NAME

Flanders VC

REFERRING VET

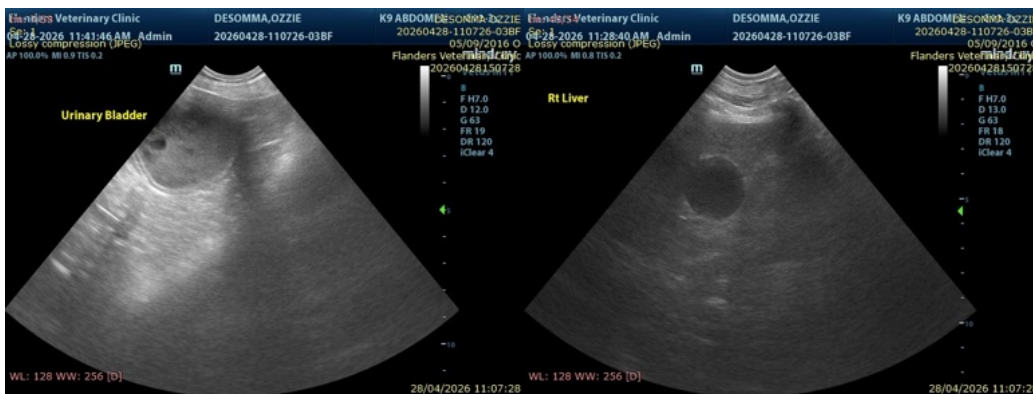Dr. Cheng

INVOICE

74949

DATE

4/28/26



The information and recommendations provided are based on the images presented by the referring veterinarian/sonographer. No evaluation can be communicated regarding pathology that was not visible in the image/video clips provided.

Thank you for this referral. If the clinical or image interpretation does not parallel your findings or if I can be of any further assistance please contact me.

Alicia Angosto Guerrero, DMV, PgDip, MSc.

info@SonoPath.com