



## PATIENT

Maddon Lawry

## SPECIES

Canine

## BREED

Miniature Schnauzer

## SEX

Neutered male

## AGE

9 years

## WEIGHT

15.5 lbs

## INTERPRETED BY

Alicia Angosto  
Guerrero, DMV,  
PgDip, MSc.

## IMAGING PERFORMED BY

Justin Eckenrode

## HOSPITAL NAME

Carlisle Small Animal  
VC

## REFERRING VET

Dr. Morrison

## INVOICE

74932

## DATE

4/28/26

## PRESENTING CLINICAL SIGNS

History: 9 year old diabetic hyperlipidemic mini schnauzer with proteinuria. Diabetic in Feb of 2023.

Last TG was 4/5/24 with 1, 221 (20-150)

Last senior panel was 2/19/26

UPC checked this year and elevated, started Telimisartan 5 mg x 2 months and then rechecked and now UPC, which is 10.1

No fructosamine since hyperlipidemia, O needs to get us a BG curve

LDDS done 4/9/25 and was inconclusive

Primary concern or rule out: PLN, kidney tumor/inflammation, cushinoid?

Spayed/neutered: neutered

Abnormal PE/Chem/CBC/UA Results: UPC 10.1 on 4/22/26\* was 4.4 on 2/20/26 \* was 2.6 on 3/18/25\* was 2.9 on 21.25 Cystatin B 2, 393 (0-99) on 4/22/26 \* was 104 on 2/21/25 2/23/26: Alb 2.6 ALT 234 (18-121) \* was 191 Alpk 1, 553 (5-160) \* was 1,257 Cholesterol 710 (131-345) \* was 971

## ULTRASONOGRAPHIC EXAMINATION OF THE ABDOMEN

### Urinary System

The urinary bladder is moderately distended, with a thin and smooth wall. The urine is anechoic. The bladder neck and proximal urethra appear normal. No calculi or evidence of inflammatory or neoplastic changes are identified.

The left kidney measures 5.16×2.34 cm, with a cortical thickness of 0.58 cm in the sagittal plane. The right kidney measures 5.43×3.13 cm, with a cortical thickness of 0.56 cm in the sagittal plane. Both kidneys are normal in shape and size for a dog of this body weight (expected length approximately 4.5–6.5 cm). The cortex is isoechoic compared to the liver parenchyma, which is abnormal given the concurrent hepatic changes. Numerous small, punctate hyperechoic foci are diffusely distributed throughout the renal cortex, consistent with mineralization or mineral-like interfaces. The corticomedullary ratio is within normal limits, and corticomedullary definition is preserved. There is no evidence of pyelectasia, nephrolithiasis, or hydronephrosis. Color Doppler demonstrates a normal vascular pattern.

### Adrenal Glands

The left adrenal gland measures 0.62 cm at the cranial pole and 0.69 cm at the caudal pole, which is at the upper limit of normal to mildly enlarged for a dog of this size (typical ≤0.6–0.7 cm). The right adrenal gland is not confidently visualized despite thorough evaluation of the region, likely due to acoustic shadowing from adjacent colonic contents. No mass effect is identified in the expected location.

### Spleen

Splenic thickness is 1.25 cm. The splenic parenchyma contains multiple small, diffusely distributed hyperechoic foci, resulting in a “sparkling spleen” appearance. The capsule is thin and regular, and vascularization appears normal.



## PATIENT

Maddon Lawry

## SPECIES

Canine

## BREED

Miniature Schnauzer

## SEX

Neutered male

## AGE

9 years

## WEIGHT

15.5 lbs

## INTERPRETED BY

Alicia Angosto  
Guerrero, DMV,  
PgDip, MSc.

## IMAGING PERFORMED BY

Justin Eckenrode

## HOSPITAL NAME

Carlisle Small Animal  
VC

## REFERRING VET

Dr. Morrison

## INVOICE

74932

## DATE

4/28/26

## Liver

The liver is subjectively enlarged, with rounded margins and regular contour. The parenchyma is diffusely hyperechoic with a fine echotexture and marked attenuation of the ultrasound beam. There is mild heterogeneity between hepatic lobes, with some lobes appearing more hyperechoic than others. No hepatic lymphadenopathy is identified.

The gallbladder is normally distended, with a thin wall. The lumen contains a large amount of echogenic sediment with mineral-like characteristics, consistent with dense biliary sludge or microlithiasis. No dilation of the cystic duct or common bile duct is observed.

## Gastrointestinal

The stomach is distended with ingesta, with a wall thickness of 1.51 mm and preserved layering. The duodenum measures 3.22 mm, within normal limits. The jejunum measures 3.06–3.39 mm, within normal limits, with preserved layering. No evidence of inflammation, ileus, or foreign material is identified. The colon measures 0.89 mm, within normal limits, with formed feces in the descending segment.

## Pancreas

The evaluated pancreatic regions do not show evidence of overt inflammation or neoplastic disease.

## Free Abdomen

No sonographic evidence of abdominal effusion, peritonitis, or lymphadenomegaly is identified. The iliac trifurcation is normal.

## PRIMARY FINDINGS

- Mild left adrenal enlargement
- Hepatomegaly with diffuse hyperechogenicity and marked acoustic attenuation.
- Marked biliary sediment.

## SECONDARY FINDINGS

- Diffuse renal cortical punctate hyperechoic foci.
- “Sparkling spleen” appearance.

## INTERPRETATION OF THE FINDINGS & FURTHER RECOMMENDATIONS

The liver is enlarged, diffusely hyperechoic, and demonstrates significant acoustic attenuation, with mild lobar heterogeneity. This pattern is most compatible with vacuolar hepatopathy, commonly



## PATIENT

Maddon Lawry

## SPECIES

Canine

## BREED

Miniature Schnauzer

## SEX

Neutered male

## AGE

9 years

## WEIGHT

15.5 lbs

## INTERPRETED BY

Alicia Angosto  
Guerrero, DMV,  
PgDip, MSc.

## IMAGING PERFORMED BY

Justin Eckenrode

## HOSPITAL NAME

Carlisle Small Animal  
VC

## REFERRING VET

Dr. Morrison

## INVOICE

74932

## DATE

4/28/26

associated with diabetes mellitus, hyperlipidemia, and hyperadrenocorticism. The observed interlobar variation in echogenicity is a recognized feature in these conditions and is likely related to variable degrees of lipid or glycogen accumulation combined with beam attenuation effects, rather than representing discrete pathology.

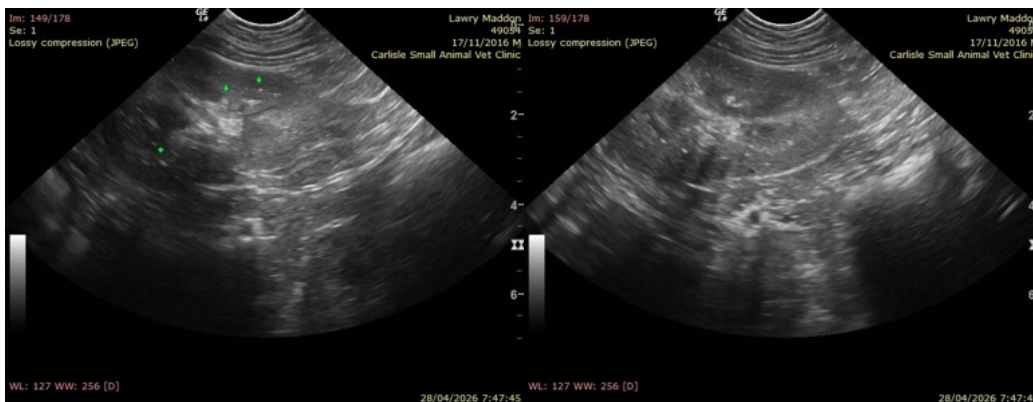
The splenic “sparkling” appearance and borderline enlargement of the left adrenal gland provide additional, although nonspecific, support for a possible hypercortisolemic state, although these findings alone are not diagnostic. Given the previously inconclusive LDDS, hyperadrenocorticism remains a differential but is not confirmed.

The kidneys are normal in size and maintain preserved corticomedullary architecture, which argues against advanced chronic kidney disease. However, the presence of diffuse cortical punctate hyperechoic foci is most consistent with renal mineralization. In this clinical context, this likely reflects metabolic mineral deposition, which can be associated with chronic hyperlipidemia, protein-losing nephropathy, or chronic metabolic derangements. Given the marked proteinuria and hypoalbuminemia, the overall clinical picture is most consistent with a glomerular disease (protein-losing nephropathy). The ultrasound findings neither confirm nor exclude specific glomerular pathologies, as expected, but help exclude mass lesions or obstructive causes and support a metabolic/systemic background. The gallbladder findings of dense sediment are consistent with biliary sludge or microlithiasis, commonly associated with hyperlipidemia in this breed.

## Recommendations

- UPC confirmation and monitoring (if not already repeated) to assess persistence and magnitude of proteinuria and response to therapy.
- Blood pressure measurement is strongly recommended.
- Further endocrine evaluation for hyperadrenocorticism may be considered (repeat LDDS, ACTH stimulation, or alternative testing)
- Biliary sediment is likely secondary, although medical management (ursodeoxycholic acid) may be considered.
- Optimization of diabetic control and management of hyperlipidemia is essential, as these are likely contributing to both hepatic and renal changes.

Final diagnostic and therapeutic decisions should be made by the attending veterinarian, who can best integrate these findings with the patient’s clinical status.





## PATIENT

Maddon Lawry

## SPECIES

Canine

## BREED

Miniature Schnauzer

## SEX

Neutered male

## AGE

9 years

## WEIGHT

15.5 lbs

## INTERPRETED BY

Alicia Angosto  
Guerrero, DMV,  
PgDip, MSc.

## IMAGING PERFORMED BY

Justin Eckenrode

## HOSPITAL NAME

Carlisle Small Animal  
VC

## REFERRING VET

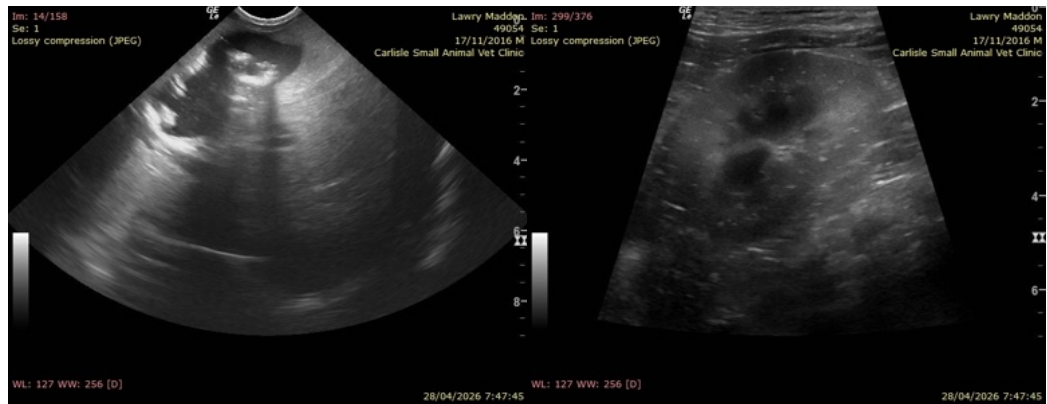
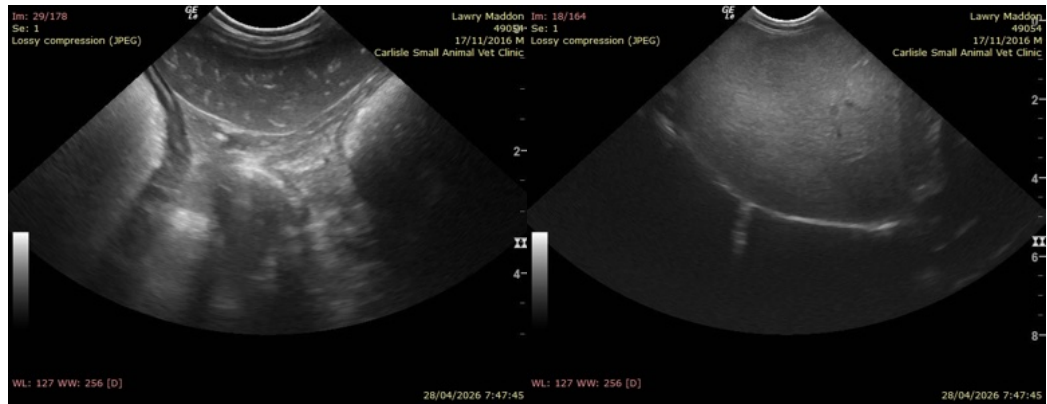
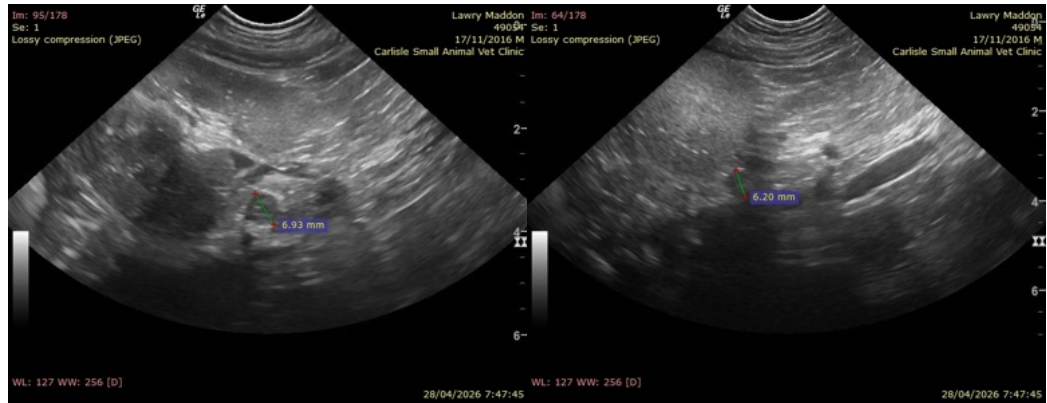
Dr. Morrison

## INVOICE

74932

## DATE

4/28/26





## PATIENT

Maddon Lawry

## SPECIES

Canine

## BREED

Miniature Schnauzer

## SEX

Neutered male

## AGE

9 years

## WEIGHT

15.5 lbs

## INTERPRETED BY

Alicia Angosto  
Guerrero, DMV,  
PgDip, MSc.

## IMAGING PERFORMED BY

Justin Eckenrode

## HOSPITAL NAME

Carlisle Small Animal  
VC

## REFERRING VET

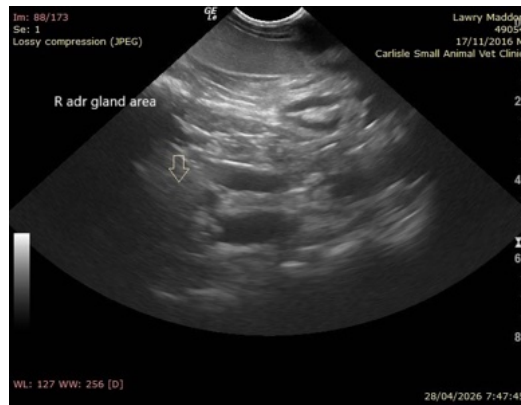Dr. Morrison

## INVOICE

74932

## DATE

4/28/26



The information and recommendations provided are based on the images presented by the referring veterinarian/sonographer. No evaluation can be communicated regarding pathology that was not visible in the image/video clips provided.

Thank you for this referral. If the clinical or image interpretation does not parallel your findings or if I can be of any further assistance please contact me.

Alicia Angosto Guerrero, DMV, PgDip, MSc.

[info@SonoPath.com](mailto:info@SonoPath.com)