



## PATIENT

Lolita Melan

## SPECIES

Canine

## BREED

Yorkshire

## SEX

Spayed female

## AGE

15 years

## WEIGHT

20 lbs

## PRESENTING CLINICAL SIGNS

History: not eating, lethargic, breathing heavy.  
a 4/6 heart murmur was ausculted during exam.

Abnormal PE/Chem/CBC/UA Results: none taken fecal negative

User Name: WestBAHSonoreport

## ULTRASONOGRAPHIC EXAMINATION OF THE ABDOMEN

### Urinary System

The urinary bladder is poorly distended, limiting evaluation of the wall. The urine is anechoic. The bladder neck and proximal urethra appear normal. There are no calculi and no ultrasonographic evidence of inflammatory or neoplastic changes.

The left kidney is normal in shape and size, measuring 4.54×2.45 cm, with a cortical thickness of 0.37 cm in the sagittal plane. The right kidney is normal in shape and size, measuring 4.35×2.42 cm, with a cortical thickness of 0.40 cm in the sagittal plane. In both kidneys, the cortex is isoechoic relative to the liver parenchyma, with several small cortical cysts. The corticomedullary ratio is within normal limits and corticomedullary definition is preserved. There is no evidence of pyelectasia, nephrolithiasis, or hydronephrosis.

## INTERPRETED BY

Alicia Angosto  
Guerrero, DMV,  
PgDip, MSc.

## IMAGING PERFORMED BY

Dr. Sreenivasa  
Maddineni

## HOSPITAL NAME

West Babylon AH

## REFERRING VET

Dr. Maddineni

## INVOICE

74930

## DATE

4/28/26

### Adrenal Glands

Dorsoventral diameters measured in the sagittal plane: The left adrenal gland measures 0.72 cm at the cranial pole and 0.67 cm at the caudal pole. The right adrenal gland measures 0.59 cm at the cranial pole and 0.59 cm at the caudal pole.

### Spleen

Splenic thickness is 1.25 cm. The parenchyma demonstrates normal echogenicity and fine homogeneous echotexture without focal parenchymal abnormalities. The splenic capsule is smooth and regular.

### Liver

The liver is enlarged, with rounded margins and an irregular contour. Within the right medial liver lobe (approximate location), there is a cavitory mass measuring 4.84×4.99 cm, as well as a second nodular lesion measuring 1.60×1.63 cm.

The gallbladder is normally distended, with a thin wall and predominantly anechoic contents, with a small amount of biliary sludge. No dilation of the cystic duct or common bile duct is observed.



## PATIENT

Lolita Melan

## SPECIES

Canine

## BREED

Yorkshire

## SEX

Spayed female

## AGE

15 years

## WEIGHT

20 lbs

## INTERPRETED BY

Alicia Angosto  
Guerrero, DMV,  
PgDip, MSc.

## IMAGING PERFORMED BY

Dr. Sreenivasa  
Maddineni

## HOSPITAL NAME

West Babylon AH

## REFERRING VET

Dr. Maddineni

## INVOICE

74930

## DATE

4/28/26

## Gastrointestinal

The stomach is empty and folded, with a mural thickness of 3.43 mm and preserved wall layering. The pylorus measures 5.26 mm. Duodenum: 2.26 mm. Jejunum: 3.97 mm, with normal wall layering. No ultrasonographic evidence of obstruction, ileus, or foreign material is identified. Colon measures 0.86–1.09 mm and contains formed feces.

## Pancreas

The evaluated pancreatic regions do not show evidence of overt inflammation or neoplastic disease.

## Free Abdomen

No sonographic evidence of abdominal effusion, peritonitis, or lymphadenomegaly is identified. The iliac trifurcation is normal.

## PRIMARY FINDINGS

- Hepatomegaly with irregular contour
- Large cavitory hepatic mass (4.84×4.99 cm)
- Additional smaller hepatic nodule (1.60×1.63 cm).

## SECONDARY FINDINGS

- Small bilateral renal cortical cysts.

## INTERPRETATION OF THE FINDINGS & FURTHER RECOMMENDATIONS

The most significant finding is a large cavitory hepatic mass, accompanied by an additional smaller hepatic nodule and overall hepatomegaly with irregular contour. The cavitory nature of the dominant lesion raises consideration for:

- Hepatic carcinoma with central necrosis.
- Less likely, but possible: hepatic abscess or nodular hyperplasia with cystic/degenerative change.

The presence of multiple lesions favors a multifocal process, which may represent metastatic disease or multicentric primary hepatic neoplasia. However, benign nodular hyperplasia cannot be completely excluded for the smaller lesion, particularly in older dogs.

There is no evidence of abdominal effusion or lymphadenomegaly, which slightly lowers suspicion for widely disseminated disease, although absence of these findings does not exclude malignancy.

The kidneys show small cortical cysts consistent with age-related incidental changes.

## Recommendations

- Initial stabilization and cardiopulmonary assessment are strongly recommended prior to any



## PATIENT

Lolita Melan

## SPECIES

Canine

## BREED

Yorkshire

## SEX

Spayed female

## AGE

15 years

## WEIGHT

20 lbs

## INTERPRETED BY

Alicia Angosto  
Guerrero, DMV,  
PgDip, MSc.

## IMAGING PERFORMED BY

Dr. Sreenivasa  
Maddineni

## HOSPITAL NAME

West Babylon AH

## REFERRING VET

Dr. Maddineni

## INVOICE

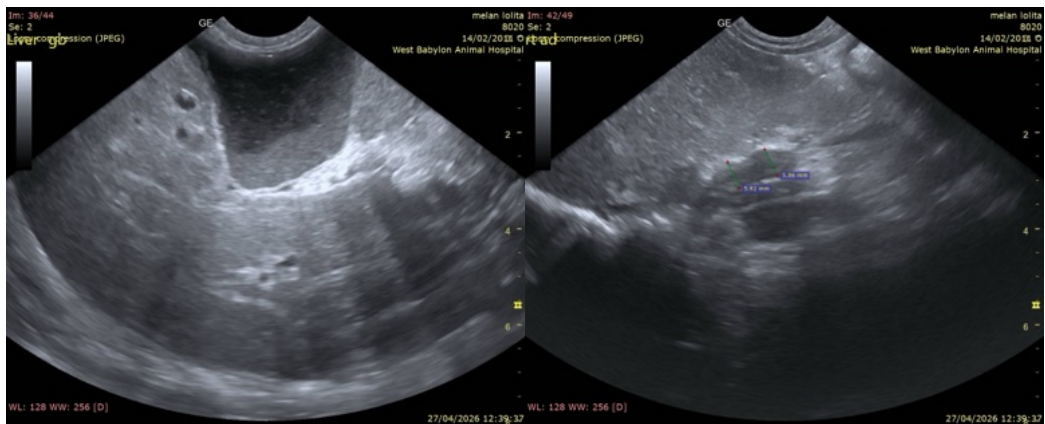
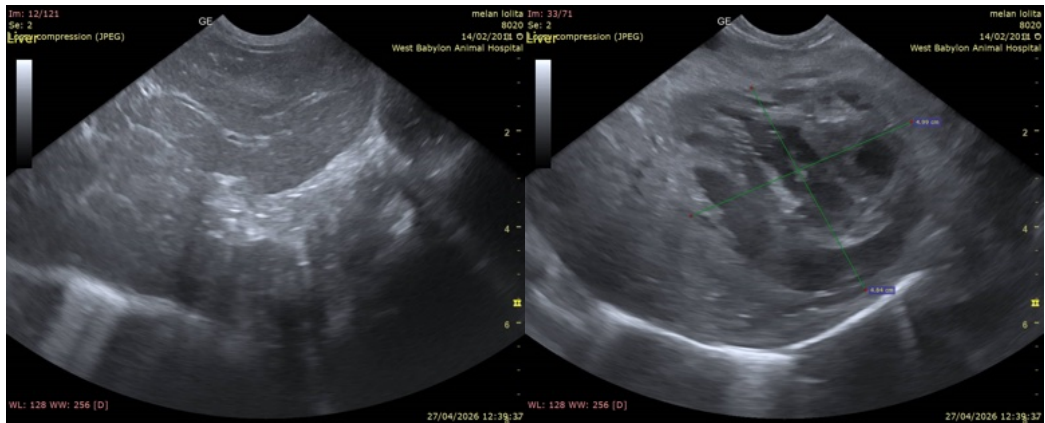
74930

## DATE

4/28/26

invasive procedure, given the patient's age, clinical signs (lethargy, increased respiratory effort), and documented heart murmur:

- Thoracic radiographs
- Consider echocardiography
- These steps are important to determine whether the clinical signs are primarily cardiac, abdominal, or multifactorial, and to assess anesthetic risk before pursuing further diagnostics.
- The hepatic mass is clinically significant; however, fine-needle aspiration may be of limited diagnostic yield given its cavitory nature, and carries a potential risk of hemorrhage, particularly in a geriatric patient.
- Once the patient is clinically stabilized and staging is completed, discussion with the owner should focus on realistic goals.
- Ongoing monitoring of clinical status is recommended to guide decision-making.





## PATIENT

Lolita Melan

## SPECIES

Canine

## BREED

Yorkshire

## SEX

Spayed female

## AGE

15 years

## WEIGHT

20 lbs

## INTERPRETED BY

Alicia Angosto  
Guerrero, DMV,  
PgDip, MSc.

## IMAGING PERFORMED BY

Dr. Sreenivasa  
Maddineni

## HOSPITAL NAME

West Babylon AH

## REFERRING VET

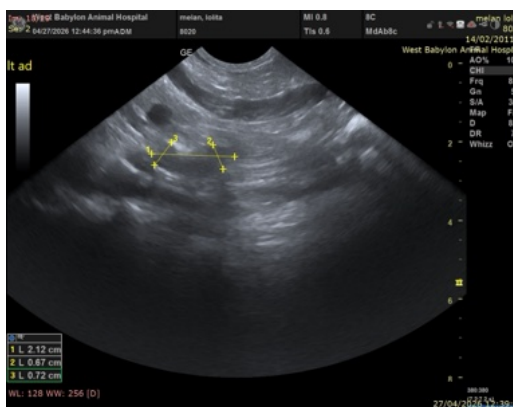
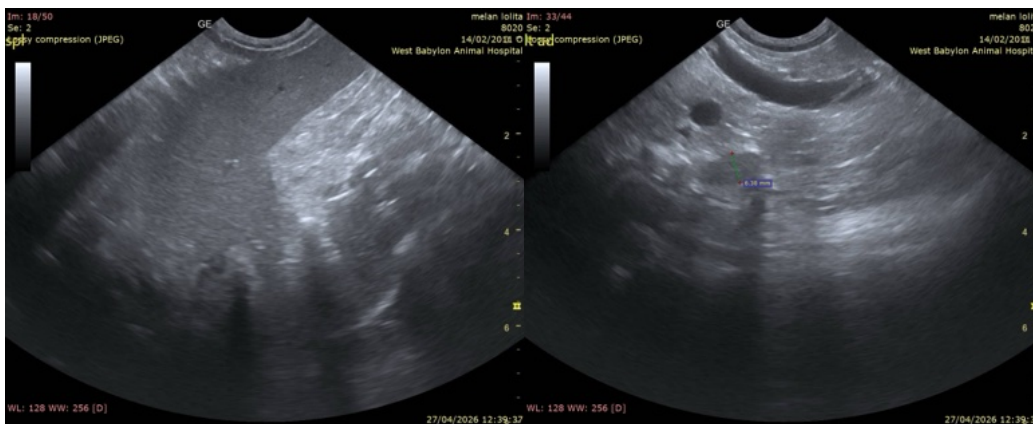
Dr. Maddineni

## INVOICE

74930

## DATE

4/28/26



The information and recommendations provided are based on the images presented by the referring veterinarian/sonographer. No evaluation can be communicated regarding pathology that was not visible in the image/video clips provided.

Thank you for this referral. If the clinical or image interpretation does not parallel your findings or if I can be of any further assistance please contact me.

Alicia Angosto Guerrero, DMV, PgDip, MSc.

[info@SonoPath.com](mailto:info@SonoPath.com)