



PATIENT

Caspian Tsemberlis

SPECIES

Canine

BREED

Lab Mix

SEX

Neutered male

AGE

12 years

WEIGHT

72 lbs

INTERPRETED BY

Alicia Angosto
Guerrero, DMV,
PgDip, MSc.

IMAGING PERFORMED BY

JK

HOSPITAL NAME

Hamburg VC

REFERRING VET

Dr. DenHeyer

INVOICE

74876

DATE

4/27/26

PRESENTING CLINICAL SIGNS

History: History of Mast cell tumors, elevated liver values
Abnormal PE/Chem/CBC/UA Results: ALT 232 ALK PHOS 391

ULTRASONOGRAPHIC EXAMINATION OF THE ABDOMEN

Urinary System

The urinary bladder is poorly distended, limiting wall evaluation. The urine is anechoic. The bladder neck and proximal urethra appear normal. There are no calculi and no ultrasonographic evidence of inflammatory or neoplastic changes.

The left kidney is normal in shape and size, measuring 7.21×2.89 cm, with a cortical thickness of 0.52 cm in the sagittal plane. The right kidney is normal in shape and size, measuring 6.52×3.20 cm, with a cortical thickness of 0.60 cm in the sagittal plane. In both kidneys, the cortex is isoechoic relative to the liver parenchyma. The corticomedullary ratio is within normal limits and corticomedullary definition is preserved. There is no evidence of pyelectasia, nephrolithiasis, or hydronephrosis.

Adrenal Glands

The left adrenal gland measures 0.53 cm at the caudal pole and is within normal limits. The right adrenal gland is not visualized.

Spleen

Splenic thickness is 1.62 cm. The parenchyma is homogeneous with normal echogenicity. There are a few small hyperechoic nodules measuring up to 4.71×4.71 mm, compatible with myelolipoma-like lesions. The splenic capsule is smooth and regular.

Liver

The liver is subjectively normal in size, with sharp edges and a regular contour. The liver parenchyma looks uniform and isoechoic compared to the falciform fat, with a normal echotexture. No hepatic lymphadenopathy is observed.

The gallbladder is normally distended. The wall appears mildly thickened with small intraluminal projections, compatible with early or mild mucosal glandular hyperplasia. The contents are predominantly anechoic. No dilation of the cystic duct or common bile duct is observed.

Gastrointestinal

The stomach is empty and folded, with a mural thickness of 3.31 mm and preserved wall layering. Duodenum: 3.58 mm. Jejunum: 2.99–3.29 mm, with normal wall layering. No ultrasonographic evidence of inflammation, ileus, or foreign material is identified. Colon: Unremarkable.



PATIENT

Caspian Tsemberlis

SPECIES

Canine

BREED

Lab Mix

SEX

Neutered male

AGE

12 years

WEIGHT

72 lbs

INTERPRETED BY

Alicia Angosto
Guerrero, DMV,
PgDip, MSc.

IMAGING PERFORMED BY

JK

HOSPITAL NAME

Hamburg VC

REFERRING VET

Dr. DenHeyer

INVOICE

74876

DATE

4/27/26

Pancreas

The evaluated pancreatic regions do not show evidence of overt inflammation or neoplastic disease.

Free Abdomen

No sonographic evidence of abdominal effusion, peritonitis, or lymphadenomegaly is identified. The iliac trifurcation is normal.

PRIMARY FINDINGS

- Small hyperechoic splenic nodules (myelolipoma-like)
- Mild gallbladder mucosal glandular hyperplasia

INTERPRETATION OF THE FINDINGS & FURTHER RECOMMENDATIONS

This is an unremarkable abdominal ultrasound in the context of a patient with a history of mast cell tumor, with no convincing ultrasonographic evidence of metastatic disease.

The liver and spleen, which are the primary targets for metastatic spread in dogs with mast cell tumors, appear largely normal. The splenic nodules are small, hyperechoic, and well-defined, features most consistent with benign myelolipomas or nodular hyperplasia, which are common incidental findings in older dogs.

However, it is important to emphasize that mast cell tumor infiltration of the liver and spleen can occur in the absence of ultrasonographic abnormalities. Therefore, a normal-appearing liver and spleen do not exclude microscopic metastatic disease.

The gallbladder changes are mild and most consistent with early mucosal glandular hyperplasia, a common incidental finding, particularly in older dogs or those with chronic hepatobiliary enzyme elevation. There is no evidence of biliary obstruction.

Overall, there is no structural explanation for the mild to moderate elevation in liver enzymes, which may be reactive, metabolic, or related to prior or concurrent medical therapy.

Recommendations

- Consider ultrasound-guided FNA of the spleen and liver for staging, even in the absence of overt abnormalities, given the history of mast cell tumor.
- Monitor liver enzymes and correlate with clinical history (including medications).
- Continue routine oncologic staging and follow-up as clinically indicated.

Final diagnostic and therapeutic decisions should be made by the attending veterinarian, who can best integrate these findings with the patient's clinical status.



PATIENT

Caspian Tsemberlis

SPECIES

Canine

BREED

Lab Mix

SEX

Neutered male

AGE

12 years

WEIGHT

72 lbs

INTERPRETED BY

Alicia Angosto
Guerrero, DMV,
PgDip, MSc.

**IMAGING
PERFORMED BY**

JK

HOSPITAL NAME

Hamburg VC

REFERRING VET

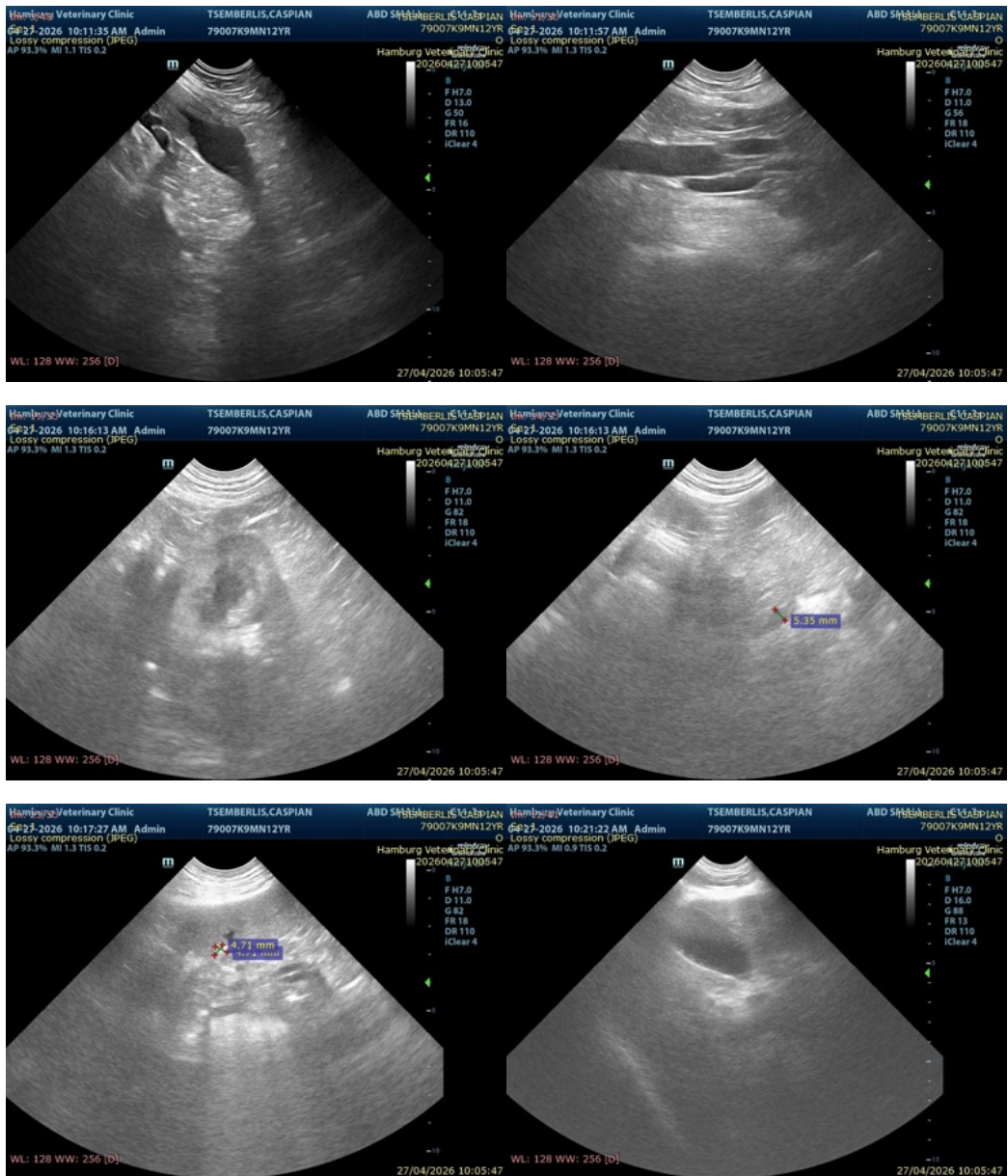
Dr. DenHeyer

INVOICE

74876

DATE

4/27/26





PATIENT

Caspian Tsemberlis

SPECIES

Canine

BREED

Lab Mix

SEX

Neutered male

AGE

12 years

WEIGHT

72 lbs

INTERPRETED BY

Alicia Angosto Guerrero, DMV,
PgDip, MSc.

IMAGING PERFORMED BY

JK

HOSPITAL NAME

Hamburg VC

REFERRING VET

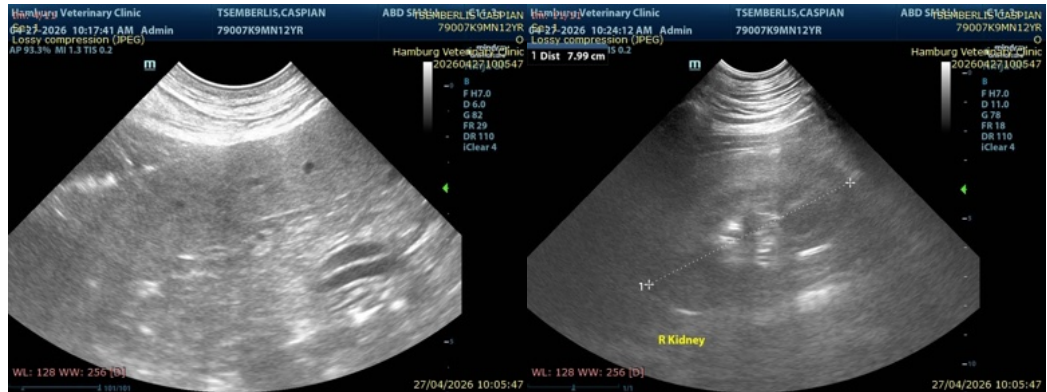Dr. DenHeyer

INVOICE

74876

DATE

4/27/26



The information and recommendations provided are based on the images presented by the referring veterinarian/sonographer. No evaluation can be communicated regarding pathology that was not visible in the image/video clips provided.

Thank you for this referral. If the clinical or image interpretation does not parallel your findings or if I can be of any further assistance please contact me.

Alicia Angosto Guerrero, DMV, PgDip, MSc.

info@SonoPath.com